



## The protective effect of quercetin against hepatotoxicity induced by doxorubicin in male rats

Farzad Rahmani<sup>1</sup>, Parvaneh Najafizadeh<sup>2</sup>, Zahra Mousavi<sup>1\*</sup>, Tayebeh Rastegar<sup>3</sup>, Elmira Barzegar<sup>4</sup>

<sup>1</sup> Department of Pharmacology & Toxicology, Faculty of Pharmacy, Pharmaceutical Sciences Branch, Islamic Azad University, Tehran, Iran

<sup>2</sup> Department of Pharmacology, Faculty of Medicine, Iran University of Medical Sciences, Tehran, Iran

<sup>3</sup> Department of Anatomy, School of Medicine, Tehran University of Medical Sciences, Tehran, Iran

<sup>4</sup> Molecular Research Lab, Department of Pharmacology and Toxicology, Tehran University of Medical Sciences, Tehran, Iran

### Please cite this article as:

Rahmani f, Najafizadeh p, Mousavi Z, Rastegar T, Barzegar E. The protective effect of quercetin against hepatotoxicity induced by doxorubicin in male rats. *Iranian J Pharmacol Ther.* 2018 (February);16: 1-8.

### ABSTRACT

Quercetin is one of the major flavonoids finding in many fruits and vegetables. Quercetin has many health promoting advantages such as improvement of allergic, arthritis disorder, and reduction of cancer and cardiovascular risk. The aim of this study was to examine hepatoprotective effects of quercetin on doxorubicin induced toxicity in animal model. Thirty male Wistar rats (200-230 g) were randomly divided in to 5 groups including: Quercetin group was orally treated with 20 mg/kg of quercetin for 14 days. Doxorubicin group was treated with 25 mg/kg of doxorubicin i.p. for 3 days. Doxorubicin- Quercetin group (DQ) was orally pre-treated of 20 mg/kg quercetin for 14 days with hepatotoxicity induced by i.p. injection of 25 mg/kg doxorubicin (12th, 13th and 14th days). The control and vehicle group were orally received saline (1 mL/kg), and DMSO (1 mL/kg) respectively. Sample of their livers were used to determine the myeloperoxidase (MPO) activity, superoxide dismutase (SOD), malondialdehyde (MDA), GPX, catalase, and histological analysis. The numerical data were evaluated by ANOVA, followed by the Tukey tests. The results show that doxorubicin could produce hepatotoxicity in rat. Also, increased liver enzymatic (ALT, AST, ALP), MPO, MDA ( $p < 0.001$ ), followed infiltration of inflammatory cell, and necrosis of hepatocytes also Pretreatment with quercetin reduces MPO activity ( $p = 0.0034$ ), MDA ( $p = 0.0335$ ) and the elevated liver ALT (0.009), ALP ( $p = 0.0023$ ) and AST activity (0.0074) in rats in DQ group. This study suggests that quercetin have a protective effect on the liver tissue against toxicity induced by doxorubicin.

Conflicts of Interest: Declared None

Funding: None

### Keywords

Quercetin,  
Doxorubicin,  
Hepatotoxicity

### Corresponding to:

Zahra Mousavi,  
Department of Pharmacology-  
Toxicology, Faculty of Pharmacy,  
Pharmaceutical Sciences Branch,  
Islamic Azad University, Tehran-  
Iran (IAUPS) No 99, Yakhchal,  
Gholhak, Shariati St., Tehran,  
Iran

Email:

[moosavi.z@iaups.ac.ir](mailto:moosavi.z@iaups.ac.ir)

Received: 24 Oct 2017

Revised: 21 Nov 2017,

Accepted: 29 Jan 2018

### INTRODUCTION

Flavonoids belong to a group of natural substances with variable phenolic structures and are found in fruits, vegetables, grains, bark roots, stem, flowers, tea and wine. Flavonoids exhibit several biological effects such as anti-inflammatory, anti-hepatotoxic, and anti-ulcer [1].

Quercetin (3,5,7,3',4'-pentahydroxyflavone) is a unique bioflavonoid that has been widely studied over the past decades. Quercetin is found in abundance in onion, broccoli, apple, and berries. Previous studies indicated that quercetin has antibacterial, antinociceptive (pain-relieving),

anxiolytic, antidepressant, anti-allergic, anti-proliferative, and antioxidant effects. It inhibits platelet aggregation and thrombus formation and is effective in diabetes and hypertension [2]. Studies have been reported that quercetin has a preventive effect in experimental models of gastric ulcers caused by various agent-induced damages [3]. It prevents oxidant injury and cell death by several mechanisms like scavenging oxygen radicals, protecting against lipid peroxidation, blocking the calcium channel's activity, and chelating metal ions [4, 5].

Doxorubicin is an anthracycline antibiotic which used for the treatment of uterine, ovarian, breast, lung cancers, Hodgkin's disease, and soft tissue sarcomas. It is assumed that oxidative stress and formation of free radicals accompanied by inflammatory processes play an essential role in doxorubicin toxicity [6]. Endogenous antioxidant enzymes such as superoxide dismutase and catalase can limit the effects of ROS but quickly become overwhelmed by large quantities of ROS. Regulation of these mediators has been considered as a therapeutic necessity to prevent doxorubicin-induced toxicities in various organs [7].

Doxorubicin is an effective anticancer drug with known cardio and hepatotoxicity. Different studies have been conducted to reduce the adverse effects of doxorubicin therapy. Various natural products such as silymarin, celery and parsley juice, catechin, berberine, and fullereneol C<sub>60</sub>(OH)<sub>24</sub> yielded desirable preclinical results in protecting against toxicity induced by doxorubicin [6, 8]. By assuming that doxorubicin hepatotoxicity is related to free radical formation and oxidative stress, an antioxidant such as quercetin might protect liver against doxorubicin-induced toxicity. Therefore, the aim of this study was to investigate, evaluate and confirm the potential hepatoprotective effects of quercetin in rats.

## MATERIALS AND METHODS

### Chemicals

Quercetin was obtained from Sigma Chemical Co. (Germany). It was solubilized in dimethylsulphoxide (DMSO), stored at 4°C and protected from light.

Doxorubicin was obtained from "CellPharma GmbH" (Germany) as solution for injection. Malondialdehyde kit was also provided by zellbioCompany (Tehran, Iran).

### Animals

Experiments were carried out on 30 adults sexually mature male Wistar rats, weighing 200–230 gr, which were obtained from the animal house of Iran University of Medical Sciences, Tehran, Iran. The animals were kept in a room with controlled temperature of (22±1) °C in a 12 h light/dark cycle with free access to food and water *ad libitum*. All experiments were performed in accordance with the guidelines for the care and use of laboratory animals (National Institutes of Health Publication No. 80-23, revised 1996) and were approved by the Research and Ethics Committee of the Pharmaceutical Sciences Branch, Islamic Azad University of Tehran, Iran (IR.IAU.PS.REC.

1396.30).

### Experimental treatment

Thirty animals were randomly divided into five groups (6 rats in each group) and weighed before and 14 days after treatment.

Control group: Saline was administered orally (1mL/kg) for 14 days

Vehicle group: DMSO was administered orally (1mL/kg) for 14 days

Doxorubicin group: Doxorubicin was given doxorubicin interpretational (25 mg/kg) for 3 days.

Quercetin group: Quercetin was given orally (20 mg/kg) for 14 days.

Doxorubicin-quercetin group (DQ): Quercetin was given orally (20 mg/kg) for 14 days and doxorubicin (for inducing hepatotoxicity) was given interpretational (25 mg/kg on 12<sup>th</sup>, 13<sup>th</sup> and 14<sup>th</sup> days).

### Evaluation of hepatic biochemical markers

One day after the administration of the last dose, the animals were sacrificed under ether anesthesia. Their livers were immediately removed and washed with saline. Then 10% of the liver was homogenized in buffered phosphate (pH=7.4) and centrifuged at 10000 rpm for 1min at 4°C. The supernatant was used for estimation of Biochemical parameters such as concentration of glutathione peroxidase (GPx), intensity of lipid peroxidation (LPx), CAT, and SOD (ZellBio GmbH: Germany).

The enzymatic activity was measured by Randex kinetic method, using bio-commercial kits and Hitachi 917 UV/VIS spectrophotometer (Hitachi Technologies, China). Liver tissue was homogenized in a Potter homogenizer with a buffered solution of TRIS-HCl sucrose with a ratio 1:3 at 4 °C. Liver homogenate was then prepared from 1 g of the homogenized liver tissue and filtered.

In order to assess the Myeloperoxidase (MPO) activity as a quantitative index of inflammation and marker of neutrophil infiltration in the tissue, hepatic samples were removed from freezer. 0.1g of each sample was weighted, homogenized in 50mM potassium phosphate buffer with pH 6 containing 0.5% hexadecyl trimethyl-ammonium bromide. The samples were then centrifuged with 11000 rpm for 10 min at 4 °C. Then, 0.1 ml of supernatant was combined with 2.9 ml of 50 mM phosphate buffer containing 0.167 mg/ml O-dianisidine hydrochloride and 0.005% H<sub>2</sub>O<sub>2</sub>. The Spectro-photometrical change of absorbance was measured (Shimadzu 160A UV-VIS spectrophotometer) at 460 nm. One unit of MPO activity in the final reaction was considered as the change in absorbance per minute at room temperature (25±1 °C); MPO activity (U g<sup>-1</sup>) = X/weight of the separated piece of tissue, where X = 10×change in absorbance per minute/volume of supernatant taken in the final reaction.

### Histological studies

Small pieces of liver tissue were fixed in 10% formalin

**Table 1.** Change in the body weight ( $\Delta$ ) and liver weight of the animals of control, Vehicle (DMSO) and experimental groups treated with Quercetin, doxorubicin and the combination of doxorubicin and Quercetin (DQ)

Animal groups	Control	Vehicle	Doxorubicin	DQ	Quercetin
$\Delta$ Body Weight (g)	1.82 $\pm$ 2.4	-3.68 $\pm$ 3.97	76.7 $\pm$ 6.16 <sup>***###&amp;&amp;&amp;^^^</sup>	-5.91 $\pm$ 1.83	-0.37 $\pm$ 2.2
Liver Weight (g)	11.23 $\pm$ 0.58	10.63 $\pm$ 0.45	7.60 $\pm$ 0.58 <sup>**###^</sup>	10.55 $\pm$ 0.62	11.77 $\pm$ 0.58

Data are presented as mean  $\pm$  S.E.M. (n= 6). Means were compared using one-way analysis of variance (ANOVA).

\*\*\* show significant different between doxorubicin and control group (p<0.0001)

### show significant different between doxorubicin and Vehicle group (p<0.0001)

&&& show significant different between doxorubicin and Quercetin group (p<0.0001)

^^^ show significant different between doxorubicin and QD group (p<0.0001)

\*\* show significant different between doxorubicin and control group (p=0.0029)

# show significant different between doxorubicin and Vehicle group (p=0.015)

\$\$\$ show significant different between doxorubicin and Quercetin group (p=0.0006)

^ show significant different between doxorubicin and QD group (p=0.018)

used for histopathological studies. Then tissue processing was done as routine. Five-micron sections were obtained, stained with Harris Hematoxylin& Eosin and assessed for any change in histological structure under light microscope.

#### Statistical analysis

The data were expressed as mean  $\pm$  SEM and statistical and correlation analyses were undertaken using the One-way ANOVA followed by a post-hoc Tukey test using GraphPad Prism 7. A p value < 0.05 was statistically significant.

### RESULTS AND DISCUSSION

The present study confirmed that doxorubicin causes a series of side effects including decrease of the body and liver weight, elevation of hepatic ALT, AST and ALP levels, increase of MPO, infiltration of inflammatory cell, and necrosis of hepatocytes. These biochemical and pathological alterations in the rat model mostly resemble acute liver failure in human.

#### Body weight changes

The rate of gain of body weight during 2 weeks of treatment (Table 1) was different among the animal groups. Body weight gain of the animals treated with doxorubicin significantly (p<0.0001) decreased compared to control, vehicle, quercetin and DQ treated rats. A decrease in body weight was also observed in the experimental group treated with a combination of doxorubicin and quercetin (DQ) but was not significant in compared to vehicle group. (p=0.5539).

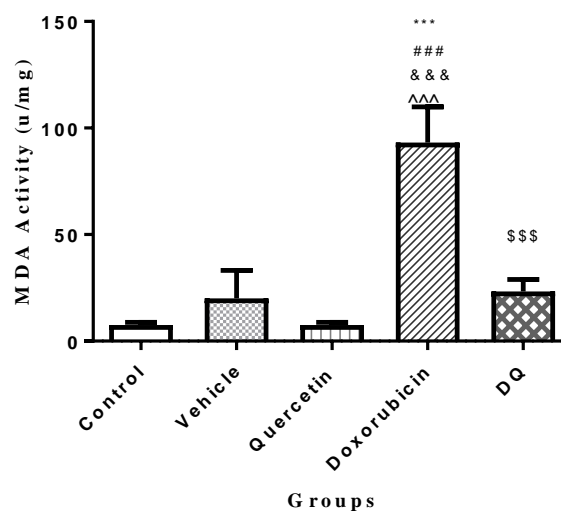
#### Liver weight

Table 1 shows body and liver weight ( $\Delta$ ) changes in different groups. Data show that the liver and body weight of the animals treated by doxorubicin, significantly decreased compared to other groups. A decrease in liver weight was also observed in doxorubicin-quercetin group (DQ) but was not significant in compared to vehicle group (p=0.97).

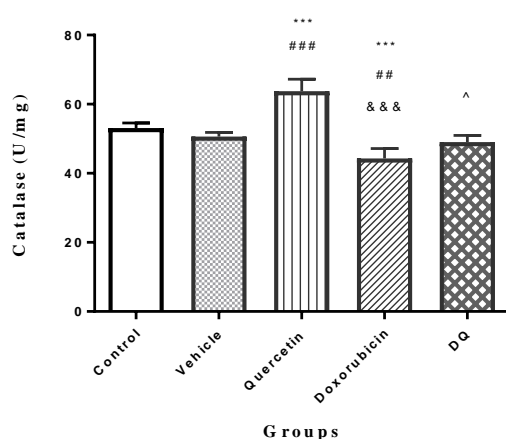
#### Biochemical parameters of rat liver homogenate and liver enzymes activity

The process of lipid peroxidation was significantly higher in the group treated with doxorubicin, compared to control, vehicle, quercetin and DQ groups (p<0.0001). Pretreatment with quercetin returned MDA content to normal levels and could be decrease MDA level compare to DQ group (Fig. 1).

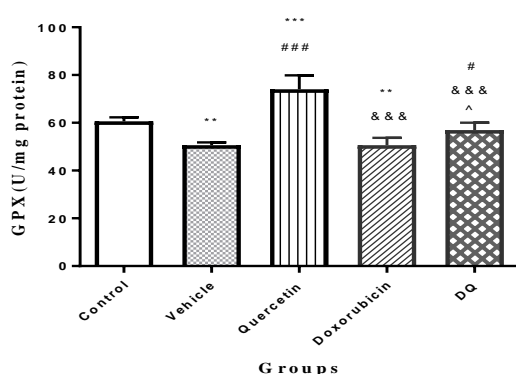
Catalase enzyme activity in the experimental group treated with Quercetin was significantly higher (p<0.001),



**Figure 1.** Effects of quercetin on hepatic MDA activity in rats treated with doxorubicin. Data are presented as mean  $\pm$  S.E.M. (n= 6). Means were compared using one-way analysis of variance (ANOVA). Control (saline) group, vehicle (DMSO) group, DQ (Doxorubicin + Quercetin) group. \*\*\* show significant different between doxorubicin and control group (p<0.0001), ### show significant different between doxorubicin and Vehicle group (p<0.0001), &&& show significant different between doxorubicin and Quercetin group (p<0.0001), ^^ show significant different between doxorubicin and QD group (p<0.0001).

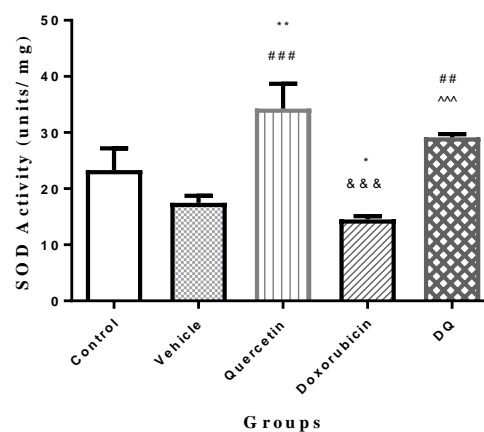


**Figure 2.** Effects of quercetin on hepatic Catalase activity in rats treated with doxorubicin. Data are presented as mean  $\pm$ S.E.M. (n= 6). Means were compared using one-way analysis of variance (ANOVA). Control (saline) group, vehicle (DMSO) group, DQ (Doxorubicin + Quercetin) group. \*\*\* show significant different between doxorubicin or quercetin and control group ( $p < 0.0001$ ), ### show significant different between quercetin and Vehicle group ( $p < 0.0001$ ), ## show significant different between doxorubicin and Vehicle group ( $p = 0.003$ ), &&& show significant different between doxorubicin and Quercetin group ( $p < 0.0001$ ), and ^ show significant different between doxorubicin and QD group ( $p = 0.0335$ ).



**Figure 3.** Effects of quercetin on hepatic GSH-Px activity in rats treated with doxorubicin. Data are presented as mean  $\pm$ S.E.M. (n= 6). Means were compared using one-way analysis of variance (ANOVA). Control (saline) group, vehicle (DMSO) group, DQ (Doxorubicin + Quercetin) group. \*\*\* show significant different between quercetin and control group ( $p < 0.0001$ ), \*\* show significant different between doxorubicin or vehicle and control group ( $p = 0.0012$ ), ### show significant different between quercetin and Vehicle group ( $p < 0.0001$ ), # show significant different between DQ and Vehicle group ( $p = 0.0436$ ), &&& show significant different between doxorubicin or DQ and Quercetin group ( $p < 0.0001$ ), and ^ show significant different between doxorubicin and QD group ( $p = 0.0426$ ).

compared to the control and experimental group treated with doxorubicin and combination of doxorubicin and



**Figure 4.** Effects of quercetin on hepatic SOD activity in rats treated with doxorubicin. Data are presented as mean  $\pm$ S.E.M. (n= 6). Means were compared using one-way analysis of variance (ANOVA). Control (saline) group, vehicle (DMSO) group, DQ (Doxorubicin + Quercetin) group. \*\* show significant different between quercetin and control group ( $p = 0.0041$ ), \* show significant different between doxorubicin and control group ( $p = 0.017$ ), ### show significant different between quercetin and Vehicle group ( $p < 0.0001$ ), ## show significant different between DQ and Vehicle group ( $p = 0.0026$ ), &&& show significant different between doxorubicin and Quercetin group ( $p < 0.0001$ ) and ^^ show significant different between doxorubicin and QD group ( $p = 0.0004$ ).

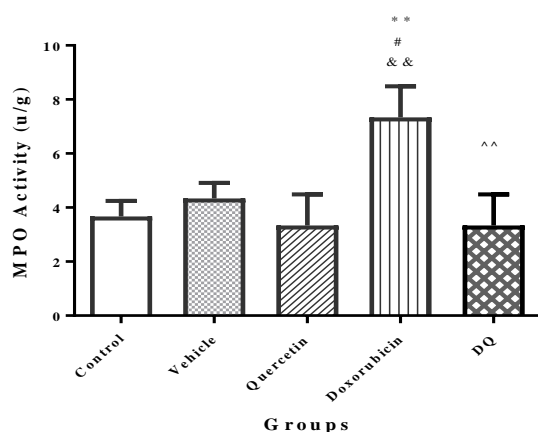
quercetin (Fig. 2). DQ group increased significantly catalase enzyme activity compare doxorubicin group ( $p = 0.0335$ ).

There is statistically significant difference in the concentration of reduced glutathione between the experimental group, treated with doxorubicin, and the control group ( $p < 0.001$ ). Administrated separately, quercetin led to a statistically significant increase in glutathione peroxidase activity, compared to the enzyme activity of the animals in the control and experimental groups treated with doxorubicin and combination of doxorubicin and quercetin ( $p < 0.0001$ ). DQ group increased significantly catalase enzyme activity compare doxorubicin group ( $p = 0.0335$ ) but there wasn't different ( $p = 0.407$ ) compare to control group (Fig. 3).

On the other hand, there was a marked reduction in the hepatic content of SOD in the animals treated with doxorubicin alone ( $p < 0.001$ ). Pretreatment with quercetin and combination of doxorubicin and quercetin improved the alterations in the hepatic SOD (Fig. 4).

MPO activity changes in hepatic homogenate of treated animals are shown in Figure 5. Doxorubicin induced a statistically significant MPO activity in comparison with the activity of control ( $p = 0.0063$ ) and vehicle groups ( $p = 0.0226$ ). Quercetin showed any significant change compared with control ( $p = 0.71$ ) and vehicle ( $p = 0.98$ ) group. The MPO activity level significantly decreased in those groups treated with a combination of doxorubicin and





**Figure 5.** Effects of quercetin on hepatic MPO activity in rats treated with doxorubicin. Data are presented as mean  $\pm$  S.E.M. (n= 6). Means were compared using one-way analysis of variance (ANOVA). Control (saline) group, vehicle (DMSO) group, DQ (Doxorubicin + Quercetin) group. \*\* show significant different between quercetin and control group (p=0.0063), # show significant different between and doxorubicin Vehicle group (p=0.0226), && show significant different between doxorubicin and Quercetin group (p=0.0034), and ^^ show significant different between doxorubicin and QD group (p=0.0034).

quercetin, compared to doxorubicin-treated groups (p=0.0034).

Significant differences were observed in the alkaline phosphatase (ALP), aspartate aminotransferase (AST) and alanine aminotransferase (ALT) activity among the animal groups. Concentration of ALP (p=0.0002), AST (p=0.014) and ALT (p=0.014) were significantly higher in the liver sample of animals treated only with doxorubicin than in vehicle group (Table 2). Quercetin reduced ALP (p=0.014), AST (p=0.0027) and ALT (p=0.0034) activity in rats treated with combination of doxorubicin and quercetin in compared to animals treated only with doxorubicin.

These biochemical and pathological alterations in the rat model mostly resemble acute liver failure in human. High aminotransferase activities of liver could be the result of damage of liver cell membranes after treatment with doxorubicin [9, 10]. The present results were in agreement with the results of other studies that liver of rats treated

with doxorubicin showed hepatotoxicity [11, 12]. Pretreatment of quercetin dramatically prevented the liver damage and improved the liver function by lowering AST and ALP levels. The protective effect of quercetin against doxorubicin was also observed in the livers after histopathological assessments. The histological damages such as inflammatory cell infiltration and necrosis of hepatocytes, induced by doxorubicin, were also remarkably attenuated by quercetin.

Doxorubicin is a very potent antitumor antibiotic. The reported acute and chronic side effects associated with doxorubicin use in clinics are the onset of cardiotoxicity and hepatotoxicity [6, 13]. In agreement with application trials on doxorubicin-induced hepatotoxicity, the present data showed that the significant increase in the activities of AST, ALP and ALT and histopathological changes in the liver were due to doxorubicin therapy. Doxorubicin toxicity is attributed to its pro-oxidant action. Many studies have described that lipid peroxidation of heart and liver cells membrane, caused by reactive oxygen species (ROS), is the main reason of tissue damage induced by doxorubicin [14-16]. The current study demonstrated that doxorubicin induced lipid peroxidation in liver tissue samples. It is well known that malondialdehyde (MDA) is the index of lipid peroxidation. Excessively generation of ROS, including superoxide radical ( $O_2^-$ ), hydroxyl radical, hydrogen peroxide ( $H_2O_2$ ) and singlet oxygen, can cause cellular injury. ROS attacks polyunsaturated fatty acids within membrane lipids, as well as, proteins and genetic materials. For that reason, measurement of MDA levels is the most commonly used method for lipid peroxidation. Superoxide dismutase catalyzes dismutation of the superoxide anion ( $O_2^-$ ) into hydrogen peroxide ( $H_2O_2$ ), which is then detoxified to  $H_2O$  by catalase (CAT). MDA levels with antioxidant capacity have been important biochemical components to detect tissue damage after doxorubicin toxicity in liver tissue. It was found that doxorubicin resulted in degeneration of hepatocytes and necrosis of parenchyma in light microscopy, as well as, high lipid peroxidation in the liver tissue. This study demonstrated that quercetin can significantly prevent the liver lipid peroxidation, liver damage, and can increase the antioxidant capacity. This was manifested by the significant reduction of the elevated hepatic enzymes activities and MDA. Thus, it seems that doxorubicin causes changes in ALT and AST

**Table 2.** Liver enzymatic findings (U/L), in rats treated with saline, DMSO, Quercetin, doxorubicin and combination of Quercetin (DQ) and doxorubicin.

Animal groups	Control	Vehicle	Doxorubicin	DQ	Quercetin
ALP	45.67 $\pm$ 0.64	66.00 $\pm$ 5.5	439.70 $\pm$ 32.8 <sup>***###</sup>	165.0 $\pm$ 34.65 <sup>^^</sup>	148.30 $\pm$ 33.1 <sup>&amp;&amp;</sup>
AST	6100 $\pm$ 357.4	5087 $\pm$ 138.9	8114 $\pm$ 369.7 <sup>#</sup>	4729 $\pm$ 571.6 <sup>^^</sup>	4175 $\pm$ 241.4 <sup>&amp;&amp;</sup>
ALT	2071 $\pm$ 202.8	2710 $\pm$ 193.8	4913 $\pm$ 207.5 <sup>#</sup>	3950 $\pm$ 190.4 <sup>^^</sup>	1601 $\pm$ 163.8 <sup>&amp;&amp;</sup>

Data are presented as mean  $\pm$  S.E.M. (n= 6). Means were compared using one-way analysis of variance (ANOVA).

\*\*\* show significant different between doxorubicin and control group in ALP activity (p=0.0001)

### show significant different between doxorubicin and Vehicle group in ALP activity (p=0.0002)

# show significant different between doxorubicin and Vehicle group in AST (p=0.014) and ALT activity (p=0.014)

&& show significant different between doxorubicin and Quercetin group in ALP (p=0.014), AST (p=0.0027) and ALT activity (p=0.0034)

^^ show significant different between doxorubicin and QD group in ALP (p=0.0023), AST (p=0.0074) and ALT activity (p=0.009)

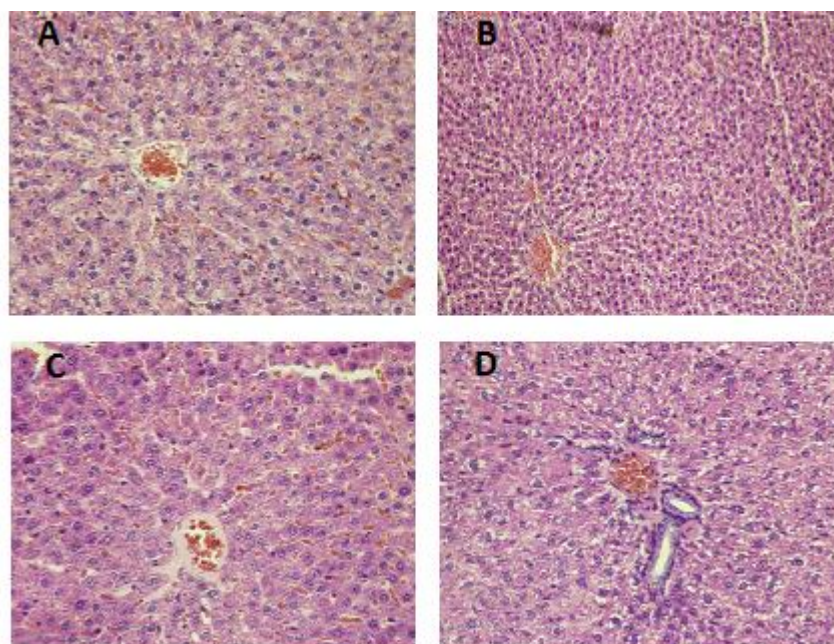
activity, which can be prevented if quercetin is used together with doxorubicin.

Low levels of glutathione were observed during an increase in oxidative stress caused by doxorubicin administration. GSH is essential in maintaining the reduced status of the cell/tissue, and its severe depletion is reported to lead to liver injury. The impaired mitochondrial function, which may contribute to the pathogenesis of doxorubicin toxicity [6], might be a reason for the observed changes in the activities of the typical markers for oxidative status in damaged liver tissue. Hepatocytes are the likely targets of reactive oxygen species (ROS) which attack to the failing liver. It is possible that free radicals cause damage in their formation. Consequently, as a major source of ROS production, mitochondria could also be the major targets susceptible to ROS attacks [12]. The deficiency in the structural design of mitochondria would lead to the adaptation of mitochondrial metabolism, which in return decreases the activity of mitochondrial enzymes in the doxorubicin intoxicated liver [17]. Therefore, it is considered as a key factor in dysfunction of intrinsic cell [18]. Mitochondrial degeneration and dysfunction has been reported to be associated with in doxorubicin administration [14]. The increased levels of oxidative stress enzymes (SOD, GSH-Px, CAT) were observed and confirmed in doxorubicin-induced rats [19].

In vitro experiments demonstrated rapid uptake of quercetin by cells, resulting in significant intracellular

accumulation. A significant uptake by isolated mitochondria was also observed which shows that quercetin is possible to be stored there and released into the cytosol when needed [20]. In vivo experiments showed that quercetin affects the ratio of reduced glutathione (GSH) and oxidized glutathione (GSSG) [21]. It is suggested that quercetin and its metabolites tend to accumulate in the organs involved in its metabolism and excretion. Moreover, it is probable that mitochondria area place for concentration of quercetin within cells. Many in vitro and in vivo animal studies have considered the antioxidant potential of quercetin [22]. They suggest that antioxidant effects of quercetin can protect brain, heart, and other tissues against ischemia-reperfusion injury, toxicity and other factors capable of inducing oxidative stress. Under some conditions, quercetin seems to have pro-oxidant activity. Long-term administration of quercetin (20mg/day) to Sprague-Dawley rats increased the concentrations of serum and liver alpha-tocopherol and significantly decreased malondialdehyde concentrations. It also decreased the GSH concentrations and activity of glutathione reductase significantly [23]. Daily intake of 1 mg/day of quercetin in an animal study increased the ratio of GSH:GSSG in hepatic tissue [21].

Quercetin is one of the major flavonoids belonging to the class of flavonols which is found in many fruits and vegetables with many pharmacological and therapeutic activities like antibacterial, antinociceptive (pain-relieving),



**Figure 6.** Effect of quercetin on histopathological damages induced by doxorubicin in liver of the rats. Liver sections were stained using the hematoxylin–eosin method. CV denotes central vein in the liver. A. The control and vehicle rats, without any signs of liver damage, B. Quercetin group had radial distribution of hepatocytes around central vein was present in the liver tissue of Quercetin treated animals, C. At following doxorubicin treatment, liver sections with massive hepatocyte degeneration, apoptosis or necrosis, and inflammatory cells infiltration, as arrows indicated, and D. quercetin + doxorubicin (DQ), the liver sections showed reduced signs of liver damage; only mild hydropic degeneration of hepatocytes could be infrequently observed, as arrow indicated. Original magnifications 40 $\times$ .

anxiolytic- and antidepressant, anti-allergic, anti-proliferative and antioxidant effects. It also inhibits platelet aggregation and thrombus formation and is effective in Diabetes, diabetic neuropathy and hypertension [2]. In vitro studies show that quercetin contains many anticancer mechanisms including antioxidant, anti-proliferative, pro-apoptotic and cell signaling effects. In addition, it has a growth factor suppression, as well as, potential synergism with some chemotherapeutic agents [24, 25]. Quercetin also inhibits the growth of cancer in vivo in animal experiments designed to promote tumor formation [2, 25]. It prevents oxidant injury and cell death by several mechanisms, like scavenging oxygen radicals, protecting against lipid peroxidation, blocking the calcium channel activity and chelating metal ions [5].

Inflammation is a major component in the pathogenesis of doxorubicin toxicity that is orchestrated in part by endogenous and migrating leukocytes. One possible mechanism might be that quercetin represses ROS by scavenging them and decreases neutrophil accumulation into the liver. Previous studies showed that antioxidant agents improved the accumulation of leukocytes in liver tissue, which is in agreement with the present findings [26]. Quercetin pretreatment decreased the accumulation of inflammatory cells and prevented inflammation-induced tissue injury. Significant liver protective effect was found in quercetin pretreatment group.

Damage of the liver tissue after doxorubicin administration was found to be the same as cardiotoxicity of doxorubicin [6, 27]. Changes in the SOD, glutathione peroxidase (GPx), and catalase (CAT) levels had the same trend; therefore, in quercetin groups, a potential hepatoprotective influence of quercetin was verified as a pre-treatment agent in multiple dose doxorubicin induced hepatotoxicity in the acute phase. Accordingly, it could be confirmed that quercetin is a potential hepatoprotective agent against doxorubicin induced hepatotoxicity. However, the protective effects of quercetin in liver do not interfere with anti-cancer activity of doxorubicin therapy. In vitro findings suggest that quercetin plays a role in reversing drug resistance and re-sensitizing cancer cells against some chemotherapeutic agents [26, 28]. Quercetin might also possibly potentiate the effectiveness of some chemotherapeutic agents [29].

#### *Evaluation of histological changes*

Histological study in control and vehicle groups indicated that hepatocytes arrangement, blood vessels and sinusoids seemed to be normal. Biliary ducts were observed, also looking normally, without any signs of cholestasis. There were no pathological changes of the liver tissue (Fig. 6A). Radial distribution of hepatocytes around central vein was present in the liver tissue of Quercetin treated animals (Fig. 6B). On the other hand, the DOX treated group alone exhibited histopathological changes, such as tissue disorganization, congestion of sinusoids as compared to the normal control group (Fig. 6C).

Pretreatment of rats with quercetin prevented the histopathological changes associated with hepatic toxicity induced by DOX. However, picnotic nucleus observed (Fig. 6D).

#### **CONCLUSION**

Ours findings demonstrated that the in vivo administration of doxorubicin resulted in the elevation of MDA levels and changes in the activities of antioxidant enzymes in rats' hepatocytes, confirming that ROS may be involved in the toxic effects of doxorubicin. Our findings also showed that quercetin had protective effects in the rats exposed to doxorubicin. Moreover, quercetin was able to diminish lipid peroxidation by restoring endogenous antioxidant enzymes. The possible mechanism of quercetin is not clear. Further research is needed to precisely identify the protective effect of quercetin.

#### **ACKNOWLEDGEMENTS**

This work was based on the Toxicology MSc thesis of Farzad Rahmani, Faculty of Pharmacy, Pharmaceutical Sciences Branch, Islamic Azad University, Tehran, Iran.

#### **CONFLICT OF INTEREST**

The authors declare that there is no conflict of interest. The authors alone are responsible for the content of the paper.

#### **REFERENCES**

1. Agrawal A. Pharmacological activities of flavonoids: a review. *Int J Pharma Sci Nanotechnol* 2011;4(2):1394-8.
2. Lakhnpal P, Rai DK. Quercetin: a versatile flavonoid. *Int J Med Update* 2007;2(2):22-37.
3. Kelly GS. Quercetin. *Altern Med Rev* 2011;16(2):172-94.
4. Abo-Salem OM, Abd-Ellah MF, Ghonaim MM. Hepatoprotective activity of quercetin against acrylonitrile-induced hepatotoxicity in rats. *J Biochem Molecul Toxicol* 2011;25(6):386-92.
5. Park C, So HS, Shin CH, Baek SH, Moon BS, Shin SH, et al. Quercetin protects the hydrogen peroxide-induced apoptosis via inhibition of mitochondrial dysfunction in H9c2 cardiomyoblast cells. *Biochem Pharmacol* 2003;66(7):1287-95.
6. Narayana KR, Reddy MS, Chaluvadi M, Krishna D. Bioflavonoids classification, pharmacological, biochemical effects and therapeutic potential. *Ind J Pharmacol* 2001;33(1):2-16.
7. Afanas'ev IB, Dcrozko AI, Brodskii AV, Kostyuk VA, Potapovitch AI. Chelating and free radical scavenging mechanisms of inhibitory action of rutin and quercetin in lipid peroxidation. *Biochem Pharmacol* 1989;38(11):1763-9.
8. Liu LL, Li QX, Xia L, Li J, Shao L. Differential effects of dihydropyridine calcium antagonists on doxorubicin-induced nephrotoxicity in rats. *Toxicology* 2007;231(1):81-90.
9. Saad SY, Najjar TA, Al-Rikabi AC. The preventive role of deferoxamine against acute doxorubicin-induced cardiac, renal and hepatic toxicity in rats. *Pharmacol Res* 2001;43(3):211-8.
10. Madjd Z, Mehrjerdi AZ, Sharifi AM, Molanaei S, Shahzadi SZ, Asadi-Lari M. CD44+ cancer cells express higher levels of the anti-apoptotic protein Bcl-2 in breast tumours. *Cancer Immun Arch* 2009;9(1):4.
11. Akyol S, Ugurcu V, Altuntas A, Hasgul R, Cakmak O, Akyol O. Caffeic acid phenethyl ester as a protective agent against nephrotoxicity and/or oxidative kidney damage: a detailed systematic review. *Sci World J* 2014;2014.



12. Abd El-Aziz M, Othman A, Amer M, El-Missiry M. Potential protective role of angiotensin-converting enzyme inhibitors captopril and enalapril against adriamycin-induced acute cardiac and hepatic toxicity in rats. *J Appl Toxicol* 2001;21(6):469-73.
13. Kolarovic J, Popovic M, Zlinská J, Trivic S, Vojnovic M. Antioxidant activities of celery and parsley juices in rats treated with doxorubicin. *Molecules* 2010;15(9):6193-204.
14. Yagmurca M, Erdogan H, Iraz M, Songur A, Ucar M, Fadillioglu E. Caffeic acid phenethyl ester as a protective agent against doxorubicin nephrotoxicity in rats. *Clin Chim Acta* 2004;348(1-2):27-34.
15. Dodda D, Chhajed R, Mishra J. Protective effect of quercetin against acetic acid induced inflammatory bowel disease (IBD) like symptoms in rats: Possible morphological and biochemical alterations. *Pharmacol Reports* 2014;66(1):169-73.
16. Kolarovic J, Popovic M, Mikov M, Mitic R, Gvozdencovic L. Protective effects of celery juice in treatments with doxorubicin. *Molecules*. 2009;14(4):1627-38.
17. Zhao X, Zhang J, Tong N, Chen Y, Luo Y. Protective effects of berberine on doxorubicin-induced hepatotoxicity in mice. *Biol Pharma Bullet* 2012;35(5):796-800.
18. El-Awady E-SE, Moustafa YM, Abo-Elmatty DM, Radwan A. Cisplatin-induced cardiotoxicity: Mechanisms and cardioprotective strategies. *Eur J Pharmacol* 2011;650(1):335-41.
19. Giannini EG, Testa R, Savarino V. Liver enzyme alteration: a guide for clinicians. *Canad Med Assoc J* 2005;172(3):367-79.
20. Kalender Y, Yel M, Kalender S. Doxorubicin hepatotoxicity and hepatic free radical metabolism in rats: the effects of vitamin E and catechin. *Toxicology* 2005;209(1):39-45.
21. El-Shitany NA, El-Haggar S, El-Desoky K. Silymarin prevents adriamycin-induced cardiotoxicity and nephrotoxicity in rats. *Food Chem Toxicol* 2008;46(7):2422-8.
22. Psotová J, Chlopčiková Š, Grambal F, Šimánek V, Ulrichová J. Influence of silymarin and its flavonolignans on doxorubicin-iron induced lipid peroxidation in rat heart microsomes and mitochondria in comparison with quercetin. *Phytother Res* 2002;16(S1):63-7.
23. Trajković S, Dobrić S, Jačević V, Dragojević-Simić V, Milovanović Z, Đorđević A. Tissue-protective effects of fullereneol C60 (OH) 24 and amifostine in irradiated rats. *Colloids Surfac B: Biointerfaces* 2007;58(1):39-43.
24. Fiorani M, Guidarelli A, Blasa M, Azzolini C, Candiracci M, Piatti E, et al. Mitochondria accumulate large amounts of quercetin: prevention of mitochondrial damage and release upon oxidation of the extramitochondrial fraction of the flavonoid. *J Nutr Biochem* 2010;21(5):397-404.
25. Hwang IK, Lee CH, Yoo K-Y, Choi JH, Park OK, Lim SS, et al. Neuroprotective effects of onion extract and quercetin against ischemic neuronal damage in the gerbil hippocampus. *J Med Food* 2009;12(5):990-5.
26. Tardif S, Madamidola OA, Brown SG, Frame L, Lefievre L, Wyatt PG, et al. Clinically relevant enhancement of human sperm motility using compounds with reported phosphodiesterase inhibitor activity. *Hum Reproduct* 2014;29(10):2123-35.
27. Pedrycz A, Wieczorski M, Czerny K, editors. Increased apoptosis in the adult rat liver after a single dose of adriamycin administration. *Ann Uni Mariae Curie-Sklodowska Sectio D: Med*; 2004.
28. Seufi AM, Ibrahim SS, Elmaghraby TK, Hafez EE. Preventive effect of the flavonoid, quercetin, on hepatic cancer in rats via oxidant/antioxidant activity: molecular and histological evidences. *J Experim Clin Cancer Res* 2009;28(1):80.
29. Su J, Guo CJ, Wei J, Yang J, Jiang Y, Li A. Protection against hepatic ischemia-reperfusion injury in rats by oral pretreatment with quercetin. *Biomed Environ Sci* 2003;16(1):1-8.

1.