

Stereological and biochemical studies of kidney in diabetic mice treated with ethanolic extract of *Urtica dioica* L.: Introducing an anti-diabetic and nephroprotective agent

Samaneh Goorani¹, Nabi Shariatifar^{2,3}, Mohammad Mahdi Zangeneh^{4,5}, Akram Zangeneh^{4,5*}, Fariba Hosseini⁵

¹ Department of Toxicology, Faculty of Veterinary Medicine, University of Tehran, Tehran, Iran

² Department of Environmental Health, School of Public Health, Tehran University of Medical Sciences, Tehran, Iran

³ Halal Research Center of iri.fda.Moh, Tehran, Iran

⁴ Department of Clinical Science, Faculty of Veterinary Medicine, Razi University, Kermanshah, Iran

⁵ Biotechnology and Medicinal Plants Research Center, Ilam University of Medical Sciences, Ilam, Iran

Please cite this article as:

Goorani S, Shariatifar N, Zangeneh MM, Zangeneh A, Hosseini F. Stereological and biochemical studies of kidney in diabetic mice treated with ethanolic extract of *Urtica dioica* L.: Introducing an anti-diabetic and nephroprotective agent. Iranian J Pharmacol Ther. 2019 (March);17:1-9.

ABSTRACT

Urtica dioica L. is widely used as an anti-inflammatory, antioxidant, antimicrobial, hypocholesterolemic, antiulcer, anti-colitis, anticancer, hypotensive, immunomodulatory, and hepatoprotective agent. In the present study, the antidiabetic and nephroprotective potentials of *U. dioica* ethanolic extract was investigated against streptozotocin (STZ) induced diabetic mice. Male mice were divided into six groups: normal control, untreated diabetic, diabetic mice receiving 30, 90 and 270 mg/kg of plant extract (groups UD30, UD90 and UD270, respectively) or 30 mg/kg glibenclamide. At 20th day, the mice killed, dissected, then blood and kidney samples were collected for histological and biochemical parameters analysis. The data was analyzed by one way variance analysis and Duncan's test using SPSS 21. Different doses of *U. dioica* (especially UD270) could significantly ($p \leq 0.05$) reduce the raised levels of blood glucose, urea, creatinine and volumes and lengths of the proximal and distal convoluted tubules, collecting ducts, vessels and loop of Henle and increase the weight of body and levels of superoxide dismutase (SOD) and catalase (CAT) when compared to the untreated group. The results of the present study showed that under the present experimental conditions, ethanolic extract of *U. dioica* indicated antidiabetic and nephroprotective abilities against STZ induced kidney damage in mice.

Conflicts of Interest: Declared None

Funding: None

Keywords

Antidiabetic potential,
Nephroprotective potential,
Ethanolic extract,
Urtica dioica L.,
Streptozotocin

Corresponding to:

Akram Zangeneh,
Department of Clinical Science,
Faculty of Veterinary Medicine,
Razi University, Kermanshah,
Iran, & Biotechnology and
Medicinal Plants Research
Center, Ilam University of
Medical Sciences, Ilam, Iran

Email:

akramzangeneh@yahoo.com

Received: 17 Sep 2018

Published: 18 Mar 2019

INTRODUCTION

Diabetes mellitus as a metabolic disorder, is the most important reason for renal failure and legal blindness and one of the major risk factors of cardiovascular diseases. Increase in sedentary lifestyle, consumption of energy-rich diets, and obesity are some of the factors resulting in the rise in the number of diabetics [1]. Diabetes patients are five times more likely to develop severe chronic leg ischemia leading to foot ulceration and often amputation than non-

diabetic patients [2].

Kidney is one of the organs that are affected in diabetes [3]. However, the exact pathogenesis of poor nephropathy in diabetic patients is not clearly understood; the decrease of proximal and distal cell capacity and also the oxidative and inflammatory changes are the main causes [3]. Renal hypertrophy is a known complication which occur in the initial stages of diabetes mellitus [4]. Some studies have revealed

that in early diabetes, renal hypertrophy could be reversed by medical treatment [5, 6].

Diabetes-inducing chemicals such as streptozotocin (STZ) cause diabetic kidney disease [7]. STZ is the compound that is used as a diabetogenic agent in diabetes-related experiments [7, 8]. It is efficiently taken up by β -cells via the glucose transporter Glut2, causing diabetes by β -cell demolition [9, 10]. In addition to β -cells, other tissues such as the kidney are also delicate to STZ toxicity [11, 12] making it arduous to identify between diabetic nephropathy-related events and direct effects of STZ in these organs [13-15].

Findings from the screening of various ethno medicinal plants describe their antioxidant effects and reveal that they could protect kidney against STZ-induced oxidative stress by changing the levels of antioxidant enzymes [16-19]. Some medicinal plants have high content of antioxidant compounds such as triterpenes, tannins, saponins, naphthaquinone, flavonoids, and alkaloids, so they can decrease the rate of nephrotoxicity [20, 21]. *Urtica dioica* L grows widely in the western parts of the Iran. It is widely distributed throughout the temperate and tropical areas around the world [22]. In Iranian traditional medicine, the leaves and roots of the plant are used internally as emmenagogue, diuretic, blood purifier and for treatment of menorrhagia, haemorrhage, haematuria, anaemia, diarrhea, jaundice, nephritis, rheumatism and eczema [22-24]. *U. dioica* elaborates several classes of organic compounds of medicinal importance including vitamins, proteins, amino acids, fatty acids, chlorophylls, sterols, carotenoids, saponins, tannins, phytosterols and flavanoids [25-27]. The plant has been reported to have various pharmacological activities [26, 28] such as anti-rheumatoid arthritis [29], cardiovascular [30], hepatoprotective [31], natriuretic, hypotensive [32], antiandrogenic [33], immunomodulatory [34], anticancer [35], analgesic [36], antiulcer [37], anti-colitis, hypocholesterolemic [30], insecticide [38], antibacterial, antiviral [25], antimicrobial, antifungal [36, 39, 40], antioxidant and anti-inflammatory [40] effects.

In the present study, we investigated the ameliorative effect of the ethanolic extract of *U. dioica* by studying the microscopic structural changes in mice kidney after streptozotocin (STZ)-induced nephrotoxicity using modern design-based stereological methods. The stereological variables are the volumes of the renal cortex, medulla, connective tissues, proximal and distal convoluted tubules, vessels, collecting ducts, Henle's loop and lengths of the five last-mentioned tubular structures. Renal functions were also investigated by examining serum (urea and creatinine) and tissue (superoxide dismutase (SOD) and catalase (CAT)) biomarkers.

MATERIALS AND METHODS

Animals

Sixty male Balb/c mice weighing between 38-40 g were housed in an air-conditioned room (22±2 °C) and had free access to the standard pellet diet and water ad libitum conditions during the study. Animal studies were approved by the Local Research Ethics Committee of Razi University, Kermanshah, Iran with the ethical code of 397-3-002.

Plant extraction

U. dioica was collected in July 2017 from Kermanshah province (in west of Iran). The leaves of the plant were shade dried for one week. The dried aerial leaves of the plant were grinded, and about 200 g of the obtained powder was extracted with 2000 mL ethanol for 2 h at 40°C by continuous shaking. The extract was left for 24 h at room temperature; it was then filtered through Whatman paper no. 2. In rotary evaporator (Panchun Scientific Co., Kaohsiung, Taiwan), the extract was concentrated and lyophilized afterward [16].

Experimental design

Diabetes was experimentally induced by intraperitoneal injection of STZ (60 mg/kg) in 50 mice. Fasting blood glucose levels were assessed everyday by glucometer strips. After three days, the mice with plasma glucose level > 250 mg/dL were considered diabetic. The mice were divided into six following groups (n=10): I. Control group (C); II. Untreated-diabetic group; III. Treated group with 30 mg/kg glibenclamide (G30); IV. Treated group with 30 mg/kg of the ethanolic extract of *U. dioica* (UD30); V. Treated group with 90 mg/kg of the ethanolic extract of *U. dioica* (UD90); VI. Treated group with 270 mg/kg of the ethanolic extract of *U. dioica* (UD270). Blood samples were obtained in 0, 4, 7, 10, 13, 16, 20 days from tail vein to assess the blood glucose level by Easy Gluco glucometer (Ames, Korea). Twenty three days after diabetes induction and at the end of the 20th day of the treatment, the animals of all groups were euthanized by ketamine HCl (40 mg/kg). Immediately, blood samples were drawn from mice heart and inserted in serum tubes for determination of urea and creatinine [16].

Also, the capacity of antioxidant enzymes was assessed by determining the activity of SOD and CAT in the whole kidney of each group (n=5) using the procedures reported by Abei (1974) and Martin *et al* (1987) [41, 42].

Histological study

Volume density: After dissection, the left kidney was weighed then fixed in 10% neutral buffered formalin solution for one week. Immersion method was used to evaluate the kidney primary volume. For assessment of kidney final volume, the amount of tissue shrinkage must be determined [43,44]. The sections of organ were prepared using the orientator method. Totally, 7-10 slab were obtained from kidney. A circular piece was sampled from a kidney slab and the area of this piece was calculated. The slabs and circular piece were processed, sectioned (5 μ m thicknesses) and stained by Periodic Acid Schiff (PAS) method. The area of the circular piece was calculated again and tissue shrinkage was measured [45]:

$$\text{Volume shrinkage} = 1 - (\text{AA}/\text{AB})^{1.5}$$

AA and AB: The area of the circular piece after and before tissue processing.

The total volume of the organ was then estimated using:

$$V_{\text{final}} = V_{\text{primary}} \times (1 - \text{Volume shrinkage})$$

Tissue sections were examined using a video microscopy system. The fractional volume of the renal structures was measured using a point probe (with an area of 100 cm² and containing 25 points) and following formula:

$$V_v = P_{\text{structure}} / P_{\text{reference}}$$

$P_{\text{structure}}$ = sum of points hitting to the interested structures

$P_{\text{reference}}$ = sum of points hitting to the reference space

Length density

The length density of the tubules and vessels was evaluated using an unbiased counting probe (740×740μm). The length density was estimated as [45]:

$$L_v = 2 \times \sum Q/a(\text{frame}) \times \sum \text{frame}$$

$\sum Q$ = sum of the tubules counted, $a(\text{frame})$ = probe area, 547600μm², $\sum \text{frame}$ = total number of the counted frames.

Statistical analysis

All data were analyzed by Duncan's test of one-way variance analysis (ANOVA), using the SPSS 18 software package. Data were considered statistically significant at $p \leq 0.05$.

RESULTS

Effect of U. dioica ethanolic extract on the weight of body

In this study, body weight reduced significantly ($p \leq 0.05$) in untreated mice compared to the control ones (Fig. 1). Administration of *U. dioica* ethanolic extract at all doses and glibenclamide could significantly ($p \leq 0.05$) enhance body weight in comparison with the untreated group. There isn't difference significant among UD90, UD270 and glibenclamide groups.

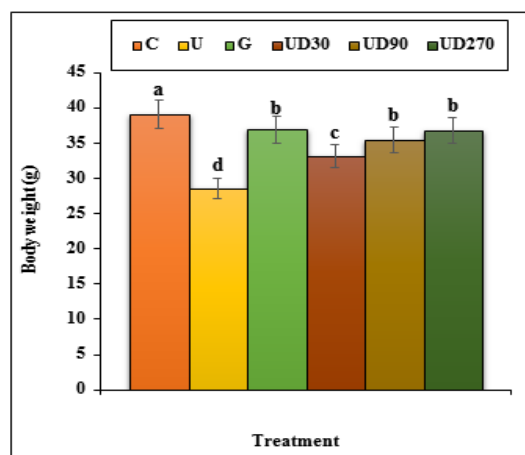


Figure 1. The weight of the body in all of the experimental groups. C (Control), U (Untreated diabetic), G (Glibenclamide), UD (*Urtica dioica*). Non-identical letters indicate a significant difference between the groups ($p \leq 0.05$).

Effect of U. dioica ethanolic extract on the concentration of fasting blood glucose

The blood glucose concentration enhanced significantly ($p \leq 0.05$) in untreated-diabetic mice in a time-dependent manner. But, treatment of STZ-diabetic mice with the *U. dioica* ethanolic extract at 90 and 270 doses could significantly ($p \leq 0.05$) decrease the blood glucose concentration similar to the glibenclamide treated at the end of the experiment. The *U. dioica* has the most effect on days 20 of the experiment (Fig. 2).

Effect of U. dioica ethanolic extract on the levels of histological parameters

The results indicated that the weight and volume of kidney and the volumes of cortical and medullary increased ($p \leq 0.05$) in the untreated mice when compared to the control ones. Administration of *U. dioica* ethanolic extract and glibenclamide could significantly ($p \leq 0.05$) reduce the above parameters when compared to the untreated group (Fig. 3,4). There isn't difference significant among UD90, UD270 and glibenclamide groups.

The volumes of proximal convoluted tubule, distal convoluted tubule, collecting duct, loop of Henle, vessels and interstitial tissue enhanced significantly ($p \leq 0.05$) in untreated mice compared to the control ones (Fig. 5). Administration of *U. dioica* ethanolic extract at all doses and glibenclamide to the mice could significantly ($p \leq 0.05$) reduce the volumes of the above structures in comparison with the untreated group. *U. dioica* at all doses and glibenclamide significantly ($p \leq 0.05$) decreased the volumes of distal convoluted tubule, loop of Henle and vessels similar to the control group. Also there isn't significant difference ($p \leq 0.05$) among UD270 and control groups in the volumes of collecting duct and interstitial tissue.

The data of the mean absolute lengths of kidney subcomponents in treated and untreated groups are showed in Fig. 6. Lengths of the proximal convoluted tubule, distal convoluted tubule, collecting duct, loop of Henle and vessels increased significantly ($p \leq 0.05$) in untreated mice compared to the control ones. *U. dioica* ethanolic extract at all doses and glibenclamide could reduce significantly ($p \leq 0.05$) the lengths of above structures as compared to the untreated group. No significant difference ($p \leq 0.05$) observed among *U. dioica* at all doses, glibenclamide and control groups in the length of distal convoluted tubule. Also there isn't significant difference ($p \leq 0.05$) among UD270, glibenclamide and control groups in the length of loop of Henle. UD270 could decrease significantly ($p \leq 0.05$) the length of collecting duct similar to the control group.

Effect of U. dioica ethanolic extract on the concentrations of kidney biochemical parameters

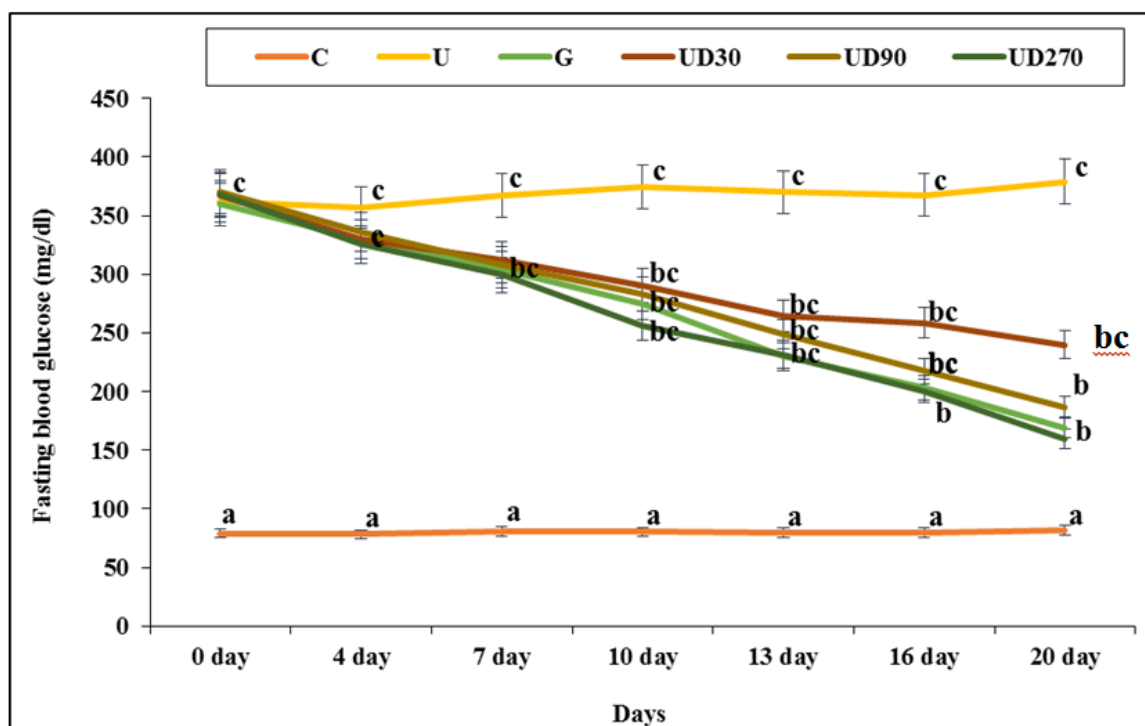


Figure 2. The levels of blood glucose on different days in all of the experimental groups. C (Control), U (Untreated diabetic), G (Glibenclamide), UD (*Urtica dioica*). Non-identical letters indicate a significant difference between the groups ($p \leq 0.05$).

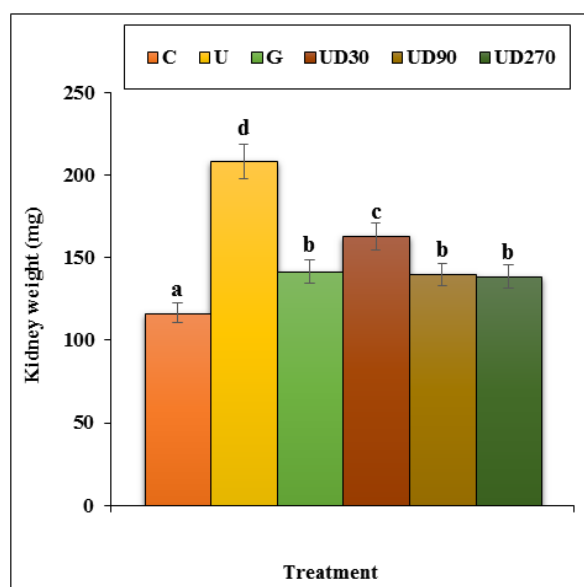


Figure 3. The weight of kidney in all of the experimental groups. C (Control), U (Untreated diabetic), G (Glibenclamide), UD (*Urtica dioica*). Non-identical letters indicate a significant difference between the groups ($p \leq 0.05$).

The estimated values of the kidney biochemical parameters are presented in Figures 7 and 8. STZ-induced toxicity, increased the concentrations of the urea and creatinine and decreased the concentrations of the SOD and CAT significantly ($p \leq 0.05$) as compared to the untreated group. Several

doses of *U. dioica* ethanolic extract and glibenclamide could significantly ($p \leq 0.05$) reduce the above parameters. There isn't significant difference ($p \leq 0.05$) among *U. dioica* at all doses, glibenclamide and control groups in the concentration of creatinine. UD90, UD270 and glibenclamide could in-

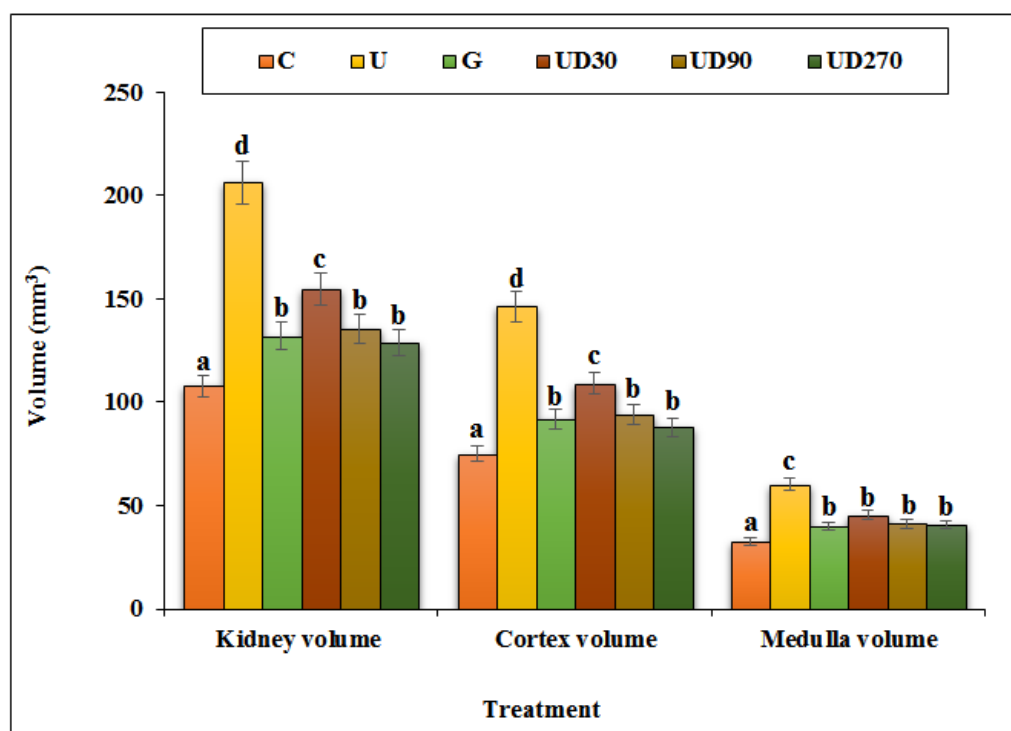


Figure 4. The absolute volumes of the kidney, cortex and medulla in all of the experimental groups. C (Control), U (Untreated diabetic), G (Glibenclamide), UD (*Urtica dioica*). Non-identical letters indicate a significant difference between the groups ($p \leq 0.05$).

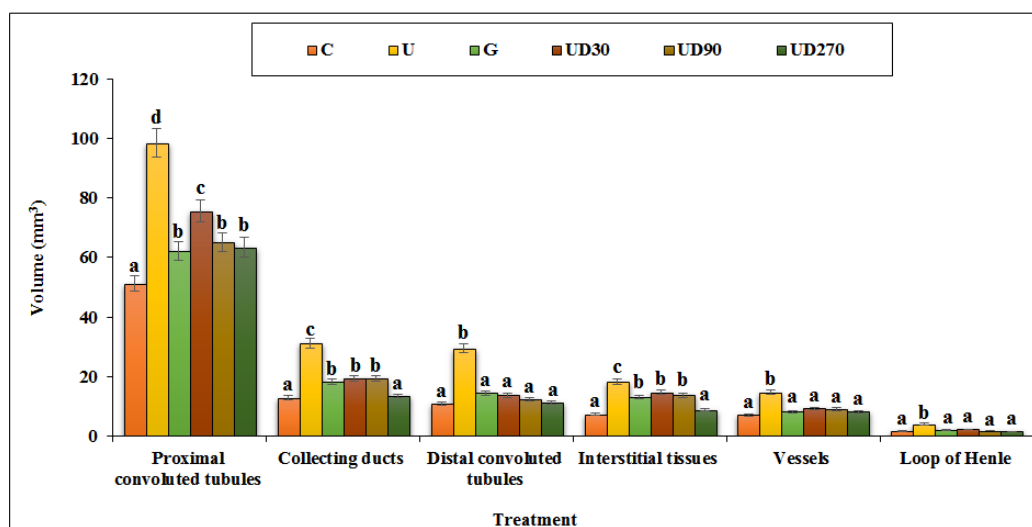


Figure 5. The absolute volumes of proximal and distal convoluted tubules, collecting ducts, interstitial tissues, vessels and loop of Henle in all of the experimental groups. C (Control), U (Untreated diabetic), G (Glibenclamide), UD (*Urtica dioica*). Non-identical letters indicate a significant difference between the groups ($p \leq 0.05$).

crease significantly ($p \leq 0.05$) the concentration of CAT similar to the control group.

DISCUSSION

Medicinal plants have the immense potential for the

management and remedy of every disease such as nephrotoxicity [20, 21]. A list of medicinal plants that consumed for their nephroprotective effects including;

Vernonia cinerea, *Aerva lanata*, *Euphorbia neriifolia*, *Punica granatum* L, *Orthosiphon stamineus*, *Carica papaya*,

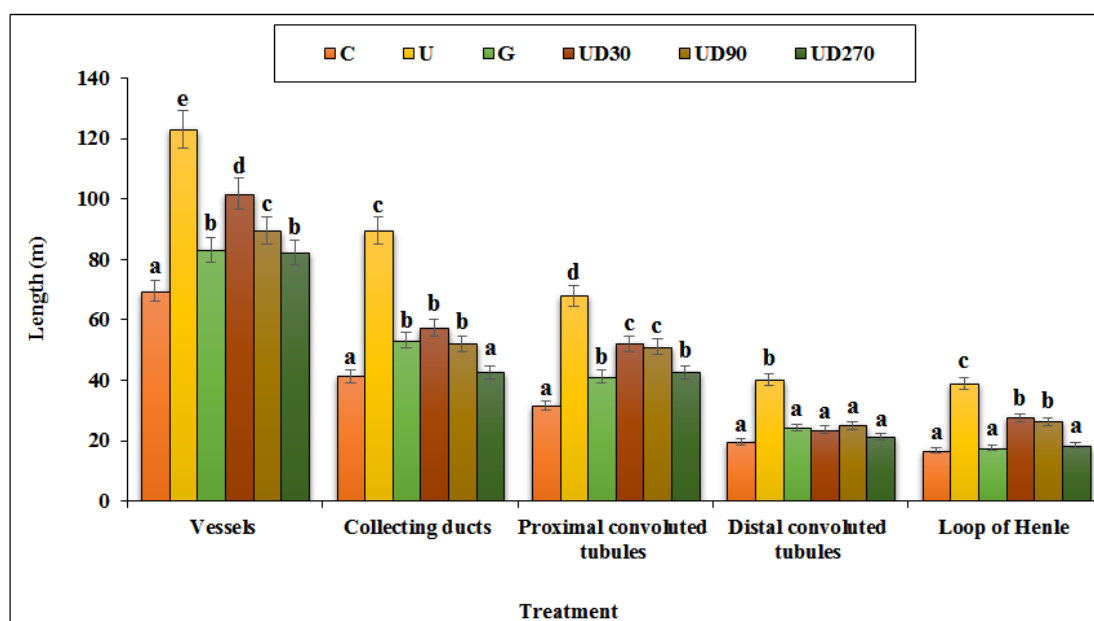


Figure 6. The absolute lengths of the vessels, collecting ducts, proximal and distal convoluted tubules and loop of Henle. C (Control), U (Untreated diabetic), G (Glibenclamide), UD (*Urtica dioica*). Non-identical letters indicate a significant difference between the groups ($p \leq 0.05$).

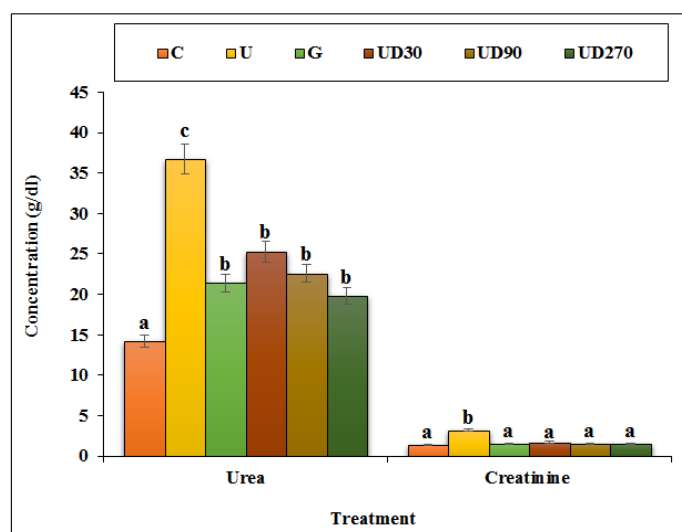


Figure 7. The levels of urea and creatinine in all of the experimental groups. C (Control), U (Untreated diabetic), G (Glibenclamide), UD (*Urtica dioica*). Non-identical letters indicate a significant difference between the groups ($p \leq 0.05$).

Strychnos potatorum, *Tamarindus indica*, *Crataeva nurvula*, *Tectona grandis*, *Boerhaavia diffusa*, *Rubia cardifolia* Linn, *Ficus religiosa* L, *Acorus calamus*, *Curcuma longa* L and *Aerva javanica* [46]. In this experimental study, the nephro-protective effect of *U. dioica* ethanolic extract at several doses was determined in STZ-induced diabetes nephrotoxicity in mice model. But, to our knowledge, this is the first time *U. dioica* ethanolic extract with these doses and methods has been used from experimentally induced diabetic in mice.

In the recent study, diabetes was induced in all mice by

single intraperitoneal injection of STZ. STZ partially annihilates the beta cells of islets of Langerhans, nephron, hepatocytes, RBC resulting in inexpressive insulin secretion causing type 2 diabetes, hepatotoxicity, nephrotoxicity, hemato-toxicity [11, 13]. The results of serum glucose levels indicated that UD90 and UD70 in 20 day have significant difference in comparison with untreated diabetic group. But there was no significant difference between the experimental doses of UD90, UD270 and classic antidiabetic drug, glibenclamide in this day. The ethanolic extract of plant 250

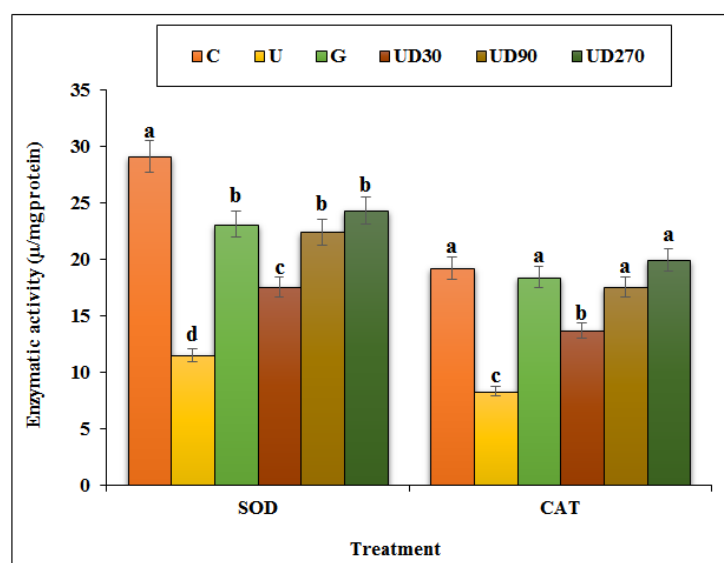


Figure 8. The levels of kidney SOD and CAT in all of the experimental groups. C (Control), U (Untreated diabetic), G (Glibenclamide), UD (*Urtica dioica*), SOD: Superoxide dismutase, CAT: Catalase. Non-identical letters indicate a significant difference between the groups ($p \leq 0.05$).

mg/kg has reported a significant glucose lowering activity against alloxan-induced diabetes in rats [47]. The fructose-induced insulin resistance in male rats has been revealed to reduce serum glucose level on administration of hydro-alcoholic leaf extract [48]. The cold methanolic extract of leaves (250 mg/kg) has also showed remarkable antihyperglycemic potential in alloxan-induced diabetes [49]. The leaf extract was administered in perfused islets of langerhans both in normal and streptozotocin induced diabetic rats which demonstrated a remarkable enhancement of insulin secretion thereby reducing the blood sugar level [50].

Renal inconveniences is evaluated by the elevated histological examination as well as by serum levels of cytoplasmic parameters [51]. The increased serum parameters levels such as creatinine and urea and the decreased tissue parameters such as SOD and CAT have been attributed to the blemished structural integrity of the kidney [51]. In our study, we observed acute renal damage in toxic group mice following STZ administration manifested by: normal shifts in renal function tests (by increasing the concentrations of urea and creatinine and decreasing the concentrations of SOD and CAT) in renal tissue with altered histopathological signs as compared to the control mice. But, *U. dioica* ethanolic extract at all doses and glibenclamide could significantly ($p \leq 0.05$) improve above parameters.

During the short-term study, the administration of *U. dioica* ethanolic extract ameliorate the renal morphological changes at all doses especially 270 mg/kg dose. Untreated mice revealed some degree of renal hypertrophy which was mainly due to the enlargement of the cortex, medullary and its subcomponents. The pathogenesis of kidney hypertrophy can be attributed to the overproduction of oxygen-free radicals following administration of toxins such as STZ, which

is expressed in response to cytokines [11]. These changes were ameliorated significantly with *U. dioica* ethanolic extract. Agree with this experiment, in a study indicated that ethno medicinal plant decreases the volumes and lengths of the proximal and distal convoluted tubules, collecting ducts, vessels and loop of Henle in STZ-induced hepatotoxicity in mice.

CONCLUSION

It concludes that *U. dioica* ethanolic extract revealed significant antidiabetic and nephroprotective potentials. This extract also demonstrated improvement in histological and biochemical parameters and so might be of value in the treatment of diabetes and nephrotoxicity.

CONFLICTS OF INTEREST

The author(s) declare(s) that there is no conflict of interest regarding the publication of this article

REFERENCES

1. Kitabchi AE, Umpierrez GE, Miles JM, Fisher JN. Hyperglycemic crises in adult patients with diabetes. *Diabetes Care* 2009; 32(7): 1335-1343.
2. Le-Devehat C, Khodabandehlou T, Vimeux M. Impaired hemorheological properties in diabetic patients with lower limb arterial ischaemia. *Clin Hemorheol Microcirc* 2001; 25(2): 43-48.
3. Musabayane CT. The effects of medicinal plants on renal function and blood pressure in diabetes mellitus. *Cardiovasc J Afr* 2012; 23(8): 462-468.
4. Hostetter TH, Troy JL, Brenner BM. Glomerular hemodynamic in experimental diabetes. *Kidney Int* 1981; 19(3): 410-415.
5. Mogensen CE, Anderson MJF. Increased kidney size and glomerular filtration rate in untreated juvenile diabetes: normalization by insulin-treatment. *Diabetologia* 1975; 11(3): 221-224.
6. Christiansen JS, Gammelgaard J, Tronier B, Svendsen PA, Parving HH.

- Kidney function and size in diabetes before and during initial insulin treatment. *Kidney Int* 1982; 21(5): 683-688.
7. Breyer MD, Bottinger E, Brosius FC, Coffman TM, Harris RC, Heilig CW, Sharma K. Mouse models of diabetic nephropathy. *J Am Soc Nephrol* 2005; 16(1): 27-45.
 8. Brosius FC, Alpers CE, Bottinger EP, Breyer MD, Coffman TM, Gurley SB, Harris RC, Kakoki M, Kretzler M, Leiter EH, Levi M, McIndoe RA, Sharma K, Smithies O, Susztak K, Takahashi N, Takahashi T. Mouse models of diabetic nephropathy. *J Am Soc Nephrol* 2009; 20(12): 2503-2512.
 9. Lenzen S. The mechanisms of alloxan- and streptozotocin-induced diabetes. *Diabetologia* 2008; 51(2): 216-226.
 10. Tesch GH, Allen TJ. Rodent models of streptozotocin induced diabetic nephropathy. *Nephrology (Carlton)* 2007; 12(3): 261-266.
 11. Rerup CC. Drugs producing diabetes through damage of the insulin secreting cells. *Pharmacol Rev* 1970; 22(4): 485-518.
 12. Weiss RB. Streptozotocin: a review of its pharmacology, efficacy, and toxicity. *Cancer Treat Rep* 1982; 66(3): 427-438.
 13. Kraynak AR, Storer RD, Jensen RD, Kloss MW, Soper KA, Clair JH, DeLuca JG, Nichols WW, Eydeloth RS. Extent and persistence of streptozotocin-induced DNA damage and cell proliferation in rat kidney as determined by in vivo alkaline elution and BrdUrd labeling assays. *Toxicol Appl Pharmacol* 1995; 135(2): 279-286.
 14. Palm F, Ortster H, Hansell P, Liss P, Carlsson PO. Differentiating between effects of streptozotocin per se and subsequent hyperglycemia on renal function and metabolism in the streptozotocin diabetic rat model. *Diabetes Metab Res Rev* 2004; 20(6): 452-459.
 15. Tay YC, Wang Y, Kairaitis L, Rangan GK, Zhang C, Harris DCH. Can murine diabetic nephropathy be separated from superimposed acute renal failure? *Kidney Int* 2005; 68(1): 391-398.
 16. Hagh-Nazari L, Goodarzi N, Zangeneh MM, Zangeneh A, Tahvilian R, Moradi R. Stereological study of kidney in streptozotocin-induced diabetic mice treated with ethanolic extract of *Stevia rebaudiana* (bitter fraction). *Comp Clin Path* 2017; 26(2): 455-463.
 17. Najafi F, Goodarzi N, Zangeneh MM, Zangeneh A, Hagh-Nazari L. Antidiabetic and hepatoprotective effects of bitter fraction of *Stevia rebaudiana* alcoholic extract on streptozotocin-induced diabetic male mice. *J Rafsanjan Univ Med Sci* 2017; 16(6): 493-504.
 18. Zangeneh MM, Goodarzi N, Zangeneh A, Tahvilian R, Najafi F. Amelioration of renal structural changes in STZ-induced diabetic mice with ethanolic extract of *Allium saralicum* R.M. Fritsch. *Comp Clin Path* 2018; 27(4): 861-867.
 19. Zangeneh MM, Zangeneh A, Amiri H, Amiri N, Tahvilian R, Moradi R, Zhaleh, H, Razegh Tehrani P. Nephroprotective activity of *Alyssum menicoides* Boiss aqueous extract on streptozotocin-induced diabetic nephrotoxicity in male mice. *Comp Clin Path* 2018; 27(5): 1147-1154.
 20. Sherkatolabbasieh H, Hagh-Nazari L, Shafieezadeh S, Goodarzi N, Zangeneh MM, Zangeneh A. Ameliorative effect of the ethanolic extract of *Allium saralicum* R.M. Fritsch on CCl₄-induced nephrotoxicity in mice: a stereological examination. *Arch Biol Sci* 2017; 69(3): 535-543.
 21. Farzaei MH, Zangeneh MM, Goodarzi N, Zangeneh A. Stereological assessment of nephroprotective effects of *Trachyspermum ammi* essential oil against carbon tetrachloride-induced nephrotoxicity in mice. *Int J Morphol* 2018; 36(2): 750-757.
 22. Khare CP. Indian medicinal plants an illustrated dictionary. New York: Springer Science Business Media LLC. 2007
 23. Guil-Guerrero J, Rebolloso-Fuentes M, Torija Isasa M. Fatty acids and carotenoids from stinging nettle (*Urtica dioica* L.). *J Food Compos Anal* 2003; 16(2): 111-119.
 24. Wetherilt H. Evaluation of *Urtica* species as potential sources of important nutrients. *Dev Food Sci* 1992; 29(1): 15-25.
 25. Krystofova O, Adam V, Babula P, Zehnalek J, Beklova M, Havel L, Kizek R. Effects of various doses of selenite on stinging nettle (*Urtica dioica* L.). *Int J Environ Res Public Health* 2010; 7(10): 3804-3815.
 26. Rafajlovská V, Kavrákovski Z, Simonovská J, Srbinoska M. Determination of protein and mineral contents in stinging nettle. *Qual Life* 2013; 4(1-2): 26-30.
 27. Katakai MS, Murugamani V, Rajkumari A, Mehra PS, Awasthi D, Yadav RS. Antioxidant, hepatoprotective and anthelmintic activities of methanol extract of *Urtica dioica* L. *Leaves Pharm Crops* 2012; 3(1): 38-46.
 28. Shackebaei D, Godini A, Abolghazi M, Majnoui M, Hesari M. Protection of ischemic and reperfused rat heart by aqueous extract of *Urtica dioica*. *Int Cardiovasc Res J* 2010; 4(3): 107-111.
 29. Riehemann K, Behnke B, Schulze-Osthoff K. Plant extracts from stinging nettle (*Urtica dioica*), an anti-rheumatic remedy, inhibit the pro-inflammatory transcription factor NF-KappaB. *FEBS Lett* 1999; 442(1): 89-94.
 30. Alisi CS, Emejulu AA, Nwagou LA, Onyema OO. Decreased cardiovascular risk and resistance to hyperlipemia-induced hepatic damage in rats by aqueous extract of *Urtica dioica*. *Afr J Biochem Res* 2008; 2(4): 102-106.
 31. Kanter M, Coskun O, Budancamanak M. Hepatoprotective effects of *Nigella sativa* L. and *Urtica dioica* Linn. on lipid peroxidation, antioxidant enzyme systems and liver enzymes in carbon tetrachloride-treated rats. *World J Gastroenterol* 2005; 11(42): 6684-6688.
 32. Tahri A, Yamani S, Legssyer A, Aziz M, Mekhfi H, Bnouham M, Ziyat A. Acute diuretic, natriuretic and hypotensive effects of a continuous perfusion of aqueous extract of *Urtica dioica* in the rat. *J Ethnopharmacol* 2000; 73(1-2): 95-100.
 33. Nahata A, Dixit VK. Evaluation of 5 α -reductase inhibitory activity of certain herbs useful as antiandrogens. *Andrologia* 2014; 46(6): 592-601.
 34. Akbay P, Basaran AA, Undeger U, Basaran N. In vitro immunomodulatory activity of flavonoid glycosides from *Urtica dioica*. *Phytother Res* 2003; 17(1): 34-37.
 35. Koch E. Extracts from fruits of saw palmetto (*Sabal serrulata*) and roots of stinging nettle (*Urtica dioica*): viable alternatives in the medical treatment of benign prostatic hyperplasia and associated lower urinary tracts symptoms. *Planta Med* 2001; 67(6): 489-500.
 36. Gulcin I, Kufrevioglu OI, Oktay M, Buyukokuroglu ME. Antioxidant, antimicrobial, antiulcer and analgesic activities of nettle (*Urtica dioica* L.). *J Ethnopharmacol* 2004; 90(2-3): 205-215.
 37. Wetherilt H. Nutritional evaluation of *Urtica* species. In: Kavalali G, editor. *Urtica*. London: Taylor and Francis.
 38. Zlatko J, Miroslav K, Zorica P. Grain-protective properties of herbal extracts against the bean weevil *Acanthoscelides obtectus* Say. *Ind Crops Prod* 2007; 26(1): 100-104.
 39. Hadizadeh I, Peivastegan B, Kolahi M. Antifungal activity of nettle (*Urtica dioica* L.), colocynth (*Citrullus colocynthis* L. Schrad), oleander (*Nerium oleander* L.) and konar (*Ziziphus spina-christi* L.) extracts on plants pathogenic fungi. *Pak J Biol Sci* 2009; 12(1): 58-63.
 40. Modarresi-Chahardehi A, Ibrahim D, Fariza-Sulaiman S, Mousavi L. Screening antimicrobial activity of various extracts of *Urtica dioica*. *Rev Biol Trop* 2012; 60(4): 1567-1576.
 41. Abei H. Catalase. In: Bergmeyer HU, Ed. *Methods of enzymatic analysis*. New York: Academic Press 1974.
 42. Martin JP, Dailey M, Sugarman E. Negative and positive assays of superoxide dismutase based on hematoxylin autooxidation. *Arch Biochem Biophys* 1987; 255(2): 329-336.
 43. Braendgaard H, Gundersen HJ. The impact of recent stereological advances on quantitative studies of the nervous system. *J Neurosci Methods* 1986; 18(1-2): 39-78.
 44. Gundersen HJ, Bendtsen TF, Korbo L, Marcussen N, Møller A, Nielsen K, Nyengaard JR, Pakkenberg B, Sørensen FB, Vesterby A. Some new, simple and efficient stereological methods and their use in pathological research and diagnosis. *Acta Pathol Microbiol Immunol Scand* 1992; 96(5): 379-394.
 45. Mandarim-de-Lacerda CA. Stereological tools in biomedical research. *An Acad Bras Cienc* 2003; 75(4): 469-486.
 46. Mohana-Lakshmi S, Usha-Kiran-Reddy T, Sandhya-Rani KS. A Review on medicinal plants for nephroprotective activity. *Asian J Pharm Clin Res* 2012; 5(4): 8-14.
 47. Grevsen K, Frette XC, Christensen LP. Concentration and composition of flavonol glycosides and phenolic acids in aerial plants of stinging nettles (*Urtica dioica* L.) are affected by nitrogen fertilization and by harvest time. *Eur J Hort Sci* 2008; 73(1): 20-27.
 48. Ahangarpour A, Mohammadian M, Dianat M. Antidiabetic effect of hydroalcoholic *Urtica dioica* leaf extract in male rats with fructose-induced insulin resistance. *Iran J Med Sci* 2012; 37(3): 181-186.
 49. Al-Wasfi RM, Jabaar Al-Kaabee HJ, Dergham M, Hameed AF. Study-

- ing the hypoglycemic and the antibacterial activity of various plant extract of *Urtica dioica*. Al-kufa J Biol2012; 4(2): 232-242.
50. Farzami B, Ahmadvand D, Vardasbi S, Majin FJ, Khaghani SH. Induction of insulin secretion by a component of *Urtica dioica* leave extract in perfused Islets of Langerhans and its in vivo effects in normal and streptozotocin diabetic rats. J Ethnopharmacol 2003; 89(1): 47-53.
51. Mishra S, Ranjan-Pani S, Sahoo S. Anti-nephrotoxic activity of some medicinal plants from tribal rich pockets of Odisha. Pharmacogn Res 2014; 6(3): 210-217.