



Original Article

IRANIAN JOURNAL OF PHARMACOLOGY & THERAPEUTICS  
Copyright © 2018 by Iran University of Medical Sciences

Iranian J Pharmacol Ther. 2018 (April);16:1-10.



## Synergistic effect of coenzyme Q10 and magnesium sulphate in reducing myocardial infarction caused by isoproterenol in rats

Arti Negi<sup>1</sup>, Rajendra Sandur V<sup>2\*</sup>, Nilanjan Ghosh<sup>1</sup>, Nikitha Gavind<sup>2</sup>

<sup>1</sup> Department of Pharmacology and Toxicology, Guru Ram Das (P.G.) Institute of Management and Technology, Dehradun, India

<sup>2</sup> Krupanidhi College of Pharmacy, Bengaluru, India

### Please cite this article as:

Negi A, Sandur V R, Ghosh N, Gavind N. Synergistic effect of coenzyme Q10 and magnesium sulphate in reducing myocardial infarction caused by isoproterenol in rats. Iranian J Pharmacol Ther. 2018 (April);16: 1-9.

### ABSTRACT

The objective of the study aims to evaluate the combined protective effects of coenzyme Q10 and magnesium sulphate on isoproterenol induced myocardial damage in rats. Coenzyme Q10 (50 mg/kg) and magnesium sulphate (10 mg/kg) were administered orally to wistar rats in individual or in combination for 30 days. At the end of this period, rats were administered isoproterenol (85 mg/kg i.p.) intraperitoneally for two consecutive days to induce myocardial injury. After induction, rats were anaesthetized and plasma was collected to analyze various biochemical parameters. Further, immunohistochemistry and histopathology of the heart tissue was performed. Induction of rats with isoproterenol resulted in a marked ( $p < 0.001$ ) elevation of infarct size, level of serum marker enzymes (AST, ALT, LDH and CK-MB), lipid peroxidation, protein expression of  $\alpha$ -smooth muscle actin ( $\alpha$ -SMA) along with alterations in histopathology. Pretreatment with combination of coenzyme Q10 (CoQ10) and magnesium sulphate (MgSO<sub>4</sub>) exhibited a significant ( $p < 0.001$ ) decrease in serum marker enzyme, infarct size, lipid peroxidation, protein expression of  $\alpha$ -smooth muscle actin ( $\alpha$ -SMA) and showed preservation of cardiomyocytes histo-architecture when compared with individual treated groups. This study demonstrated the synergistic cardio protective effect of coenzyme Q10 (CoQ10) and magnesium Sulphate (MgSO<sub>4</sub>) in isoproterenol induced myocardial damage in rats demonstrated that the oral pre-treatment with CoQ10 and Magnesium sulphate were associated with moderate protection against ISO-induced cardio toxicity and cardiac hypertrophy. The mechanism might be associated with the enhancement of antioxidant defense system. The present results can form the basis that combination of CoQ10 and magnesium sulphate proved to be a potential therapeutic agent for pharmacological management of ischemic heart disease. It could provide experimental evidence to support the rationality of combinatorial use in the prevention of the onset and progression of myocardial injury.

**Conflicts of Interest:** Declared None

**Funding:** None

### Keywords

Myocardial damage,  
Coenzyme Q10,  
Magnesium sulphate,  
Isoproterenol,  
Lipid peroxidation,  
 $\alpha$ -Smooth Muscle Actin

### Corresponding to:

Rajendra Sandur V,  
Department of Pharmacology,  
Krupanidhi College of Pharmacy,  
Bengaluru, India

Email:

[drrajendra1972@gmail.com](mailto:drrajendra1972@gmail.com)

Received: 15 Oct 2017

Revised: 21 Nov 2017,

Accepted: 21 Feb 2018

### INTRODUCTION

Cardiovascular disease (CVD), predominantly myocardial damage, is the leading cause of death worldwide

[1]. Acute myocardial damage is the most important and serious consequence of coronary artery disease. It occurs

when myocardial ischemia, a diminished blood supply to heart, exceeds a critical threshold and overwhelms myocardial cellular repair mechanisms designed to maintain normal operating function and homeostasis. Ischemia at this critical threshold level for an extended period results in irreversible myocardial cell damage or death [2]. According to W.H.O, 17.3 million deaths in 2008 were attributed to cardiovascular disease, with 7.3 million (42 % of all cardiovascular deaths) being due to the result of a myocardial damage [3]. In India, 31.7 % of deaths occur due to MI. Incidence of cardiovascular diseases was about 7 % in 1970 and increase up to 32 % in 2011 in India [4]. Myocardial damage is invariably followed by numerous pathophysiological and biochemical alterations including hyperlipidemia, thrombosis, lipid peroxidation (LPO) and free radical damage etc., leading to qualitative and quantitative changes of myocardium [5]. Isoproterenol is a synthetic catecholamine and  $\beta$ -adrenergic agonist which has been documented to produce severe stress in the myocardium resulting in myocardial damage, if administered in supramaximal doses [6, 7].

The pathophysiological and morphological aberrations produced in the heart of this myocardial necrotic rat model are comparable with those taking place in human. Among the various mechanism proposed to explain ISO induced damage to cardiac myocytes including hypoxia, coronary hypotension, calcium overload, energy depletion and excessive production of free radicals as a result of catecholamine auto-oxidation [7]. Various experimental and clinical studies have shown that enormous amount of reactive oxygen species such as superoxide, hydrogen peroxide and hydrogen radicals are generated in failing myocardium [8]. CoQ10 (ubiquinone, CoQ10) is ubiquitous and has a central role against the depletion of ATP (Adenosine tri phosphate) as an electron carrier in the mitochondrial respiratory chain and in oxidative phosphorylation. Extra mitochondrial CoQ10 is also an efficient lipid soluble antioxidant, protecting against lipid peroxidation [9]. Low levels of cardiac CoQ10 is observed in patients with cardiomyopathy [10]. Coenzyme Q10 exerts action at the cellular level and rectifies some of the basic deficiencies leading to aggravation of heart related diseases [11]. These cardio protective effects of CoQ10 are most likely explained by its antioxidant effect and its ability to generate ATP which requires continuous reduction of ubiquinone and regeneration to the active ubiquinol form [12].

Magnesium, a rare alkaline earth metal is the second most abundant intracellular cation and the fourth most important cation in the body [13]. Magnesium is critical for the proper functioning of many physiologic reactions, including those that are critical to the cardiovascular system. Magnesium deficiency has been suggested in cardiomyopathy [14]. Also, there is growing evidence that magnesium status is important in pathogenesis and treatment of cardiovascular disease [15]. Calcium overload is central in ischemic myocardial cell death and this is exacerbated during reperfusion. Magnesium administration may provide

cellular protection during ischemia. Magnesium drives calcium into the sarcoplasmic reticulum, reduces mitochondrial calcium overload [16] and competes with calcium for binding to troponin C. It also inhibits calcium influx into myocytes and thus prevents increase in intracellular concentration of calcium function. Magnesium helps to conserve ATP as the magnesium salt [17]. The present study is designed to evaluate the preventive effect on architectural alteration in myocardial tissue through Anti-  $\alpha$  smooth muscle actin ( $\alpha$ -SMA) by using a combination of CoenzymeQ10 with Magnesium Sulphate on  $\beta$  adrenergic stimulator induced myocardial injury.

## MATERIALS AND METHODS

### *In vivo study*

**Animals:** All experiments and protocols described in the present study were approved by the Institutional Animal Ethics Committee (IAEC) of Pharmacy Department and Committee for the purpose of Control and Supervision of Experiments on animals (CPCSEA) guidelines (IAEC Approval Number:- 1145/07/CPCSEA, Date:- 15/12/2013). Rats of both sexes, weighing about 200-250 g were obtained from SGRR Institute of Technology, Dehradun. The animals were housed in separate cages and maintained under standardized condition ( $25\pm 5^\circ\text{C}$  and 35 to 60 % humidity) in a well-ventilated animal house under 12 hour light-dark cycle. They were provided free access to standard laboratory food and purified drinking water *ad libitum*.

### *Induction of experimental myocardial damage*

Isoproterenol was dissolved in normal saline and injected intraperitoneally to rats (85 mg/kg, i.p.) at an interval of 24 h for 2 days to induce experimental myocardial damage [18, 19].

### *Experimental Design*

After acclimatization, animals were randomly divided into the following groups consisting of 6 rats each:

**Group I (Control):**- Animals received standard laboratory diet and drinking water *ad libitum* and served as a control group.

**Group II (Positive control):** Animals received isoproterenol (85 mg/kg, i.p) for 2 days.

**Group III (Coenzyme):** Animals received CoQ10 (50 mg/kg) orally daily for 30 days and isoproterenol on 31<sup>st</sup> and 32<sup>nd</sup> day and then treatment were continued for 10 days.

**Group IV (MgSO<sub>4</sub>):** Animals received MgSO<sub>4</sub> (10 mg/kg) orally daily for 30 days and isoproterenol on 31<sup>st</sup> and 32<sup>nd</sup> day and then treatment were continued for 10 days [20].

**Group V (CoQ10 and MgSO<sub>4</sub>):** Animals received combination of CoQ10 + MgSO<sub>4</sub> (50 mg/kg + 10 mg/kg), orally daily for 30 days and isoproterenol on 31<sup>st</sup> and 32<sup>nd</sup> day and then treatment were continued for 10 days [21, 22].

### *In vitro antioxidant study*

#### *Reducing power activity*

**Principle:** This method is based on the principle of

increase in the absorbance of the reaction mixtures. Increase in the absorbance indicates an increase in the antioxidant activity. Increase in absorbance of the reaction mixture indicates the reducing power of the samples. Substances, which have reduction potential, react with potassium ferricyanide ( $K_3Fe(CN)_6$ ) ( $Fe^{3+}$ ) to form potassium ferrocyanide ( $Fe^{2+}$ ), which then reacts with ferric chloride to form ferric ferrous complex that has an absorption maximum at 700 nm.

Potassium ferricyanide + Ferric chloride  $\rightarrow$  Potassium ferrocyanide + ferrous chloride

Procedure: In this method, antioxidant compound forms a colored complex with potassium ferricyanide, trichloro acetic acid and ferric chloride, which is measured at 700 nm. Increase in absorbance of the reaction mixture indicates the reducing power of the samples. In the method 2.5 ml of 0.2 M phosphate buffer (pH 6.6) and 2.5 ml of  $K_3Fe(CN)_6$  (1 % w/v) were added to different conc. of drug sample dissolved in distilled water. The resulting mixture was incubated at 50 °C for 20 min, followed by the addition of 2.5 ml of trichloro acetic acid (10 % w/v). The mixture was centrifuged at 3000 rpm for 10 min to collect the upper layer of the solution. Then 2.5 ml of supernatant was mixed with 2.5 ml distilled water and 0.5 ml of ferric chloride (0.1 % w/v). The absorbance was measured at 700 nm against blank sample [23].

Body weight and Heart weight: The body weights of rat were monitored at regular intervals during the experimental period. At the end of the experiment, the animals were euthanized, the hearts were removed, weighed, and histological examinations were done. The relative heart weight to body weight ratio was calculated to assess the degree of myocardial weight gain [24].

Biochemical parameters in serum: The collected serum was used for the estimation of cardiac marker creatine kinase-MB (CK-MB) [25], lactate dehydrogenase (LDH) [26,27], aspartate transaminase (AST) and alanine transaminase (ALT) [28] using commercially available standard enzymatic Ranbaxy kits.

Measurement of Myocardial infarct size: The principle of tri phenyl tetrazolium chloride (TTC) assay is based on the oxidation of TTC by the intact mitochondrial dehydrogenase, which results in the formation of 1,3,5-triphenyltetrazolium formazan (carmin red product). Infarcted tissues lack dehydrogenase activity and hence no stain is observed [29, 30].

The heart was transversely cut across the left ventricle, and sections having 2mm to 3mm thickness were incubated in 1 % TTC solution prepared in phosphate buffer for 30 min at 37 °C. Later tissues were fixed in 10 % formalin. The non-ischemic myocardium and viable ischemic myocardium were stained red, while the infarcted myocardium were observed as pale grey or white [31].

#### *In vivo Lipid peroxidation*

This assay is based on the reaction of a chromogenic reagent, 2-thiobarbituric acid, with malondialdehyde (MDA)

at 25 °C which results in the formation of a chromophore with absorbance maxima at 530 nm. Determinations of lipid peroxidation were done by colorimetric estimation by measuring the amount of malondialdehyde (MDA) [32]. Samples were homogenized in cold phosphate buffer saline (pH-7.4). To 2 ml of the above sample, 2 ml of 28 % trichloroacetic acid were added and centrifuged. To the above 4 ml of supernatant 1 ml of 1 % thiobarbituric acid was added, and heated in boiling water for 60 min. The solution was cooled. The absorbance of the solution was then read using a spectrophotometer at 530 nm [33]. The amount of malondialdehyde (MDA) (nmol/mL) was then calculated.

#### *Histopathological examination*

Rats were sacrificed and hearts were collected from each group. The myocardial tissues were preserved in natural phosphate buffer, 10 % formalin solution for histological studies. Haemotoxylin and Eosin (H&E) stains were used to stain the sections for histological evaluation using light microscope [34].

#### *Immunohistochemistry*

The paraffin sections were deparaffinized in xylene, dehydrated in a graded series of ethanol. Sections were then incubated in antigen for retrieval (boiling the section at 98 °C for 20 minutes in 10 mM/L sodium citrate buffer) and then treated with 3 %  $H_2O_2$ . Monoclonal antibody  $\alpha$  smooth muscle actin ( $\alpha$ -SMA) were applied on the slide and incubated in humid chamber overnight in a refrigerator at 4 °C. Secondary antibodies were then applied followed by incubation with streptavidin peroxidase. Sections were washed with phosphate buffered saline (PBS) three times after each step. Sections were then stained with diaminobenzidine (DAB) chromogenic solution and counter stained with haemotoxylin [35].

#### *Statistical Analysis*

The results were expressed as mean  $\pm$  standard deviation for six rats for each group. The statistical analyses were performed using Graph Pad Prism software version 5.04 statistical package program. Analyses were done using one-way analysis (ANOVA) followed by Dunnett's multiple comparison tests. *P* value < 0.05 was considered statistically significant.

## RESULTS

### *In vitro antioxidant activity*

#### *Reducing power activity*

It was observed that the CoQ10 have demonstrated dose dependent increase in the reducing property. Ethanolic solution of CoQ10 (100 mg) have shown maximum reducing power i.e. 95.70 % at concentration of 100 mg/ml and ascorbic acid have shown maximum activity i.e. 134.49 % at concentration 100  $\mu$ g/ml. However, Magnesium sulphate does not show any reducing power activity. But reducing power activity increased when both CoQ10 and  $MgSO_4$  used

**Table 1.** Reducing power activity of Ascorbic acid, CoQ10 and CoQ10+MgSO4

S. No.	Conc. (µg/ml)	Abs (Ascorbic acid)	%Increase In reducing activity (Ascorbic acid)	Conc. (mg/ml)	Abs (CoQ10)	%increase In reducing activit (CoQ10)	Abs CoQ10 +MgSO <sub>4</sub>	% Increase In reducing activity (CoQ10+MgSO <sub>4</sub> )
1.	1.56	0.423	4.96%	1.56	0.526	2.73%	0.623	10.26%
2.	3.125	0.475	17.86%	3.125	0.598	16.79%	0.687	21.59%
3.	6.25	0.514	27.54%	6.25	0.630	23.04%	0.795	40.70%
4.	12.5	0.597	48.13%	12.5	0.680	32.81%	0.824	45.84%
5.	25	0.654	62.28%	25	0.724	41.40%	0.899	59.11%
6.	50	0.756	87.59%	50	0.812	58.59%	0.989	75.04%
7.	100	0.945	134.49%	100	1.002	95.70%	1.234	118.4%

**Table 2.** Effect of CoQ10 & Magnesium Sulphate pretreatment on heart weight, body weight and heart weight/body weight ratio in isoproterenol induced myocardial damage in rats

Groups	Control	ISO-treated	CoQ10+ISO	MgSO <sub>4</sub> +ISO	CoQ10+MgSO <sub>4</sub> +ISO
Initial body weight(g)	252±1.51	240.2±2.34	245.4±2.17	245±1.83	250±0.02
Body weight (g)	252±1.67	232.6±2.94*	242.16±2.48 <sup>#</sup>	240.16±1.16 <sup>#</sup>	247.16±1.16 <sup>#@^</sup>
Heart weight (g)	0.603 ±0.01	1.065±0.02*	0.82±0.01 <sup>#</sup>	0.878±0.015 <sup>#</sup>	0.744±0.022 <sup>#@^</sup>
Heart weight/body weight ratio (%)	0.239±0.008	0.457±0.01*	0.338±0.006 <sup>#</sup>	0.364±0.006 <sup>#</sup>	0.303±0.006 <sup>#@^</sup>

All values are expressed as mean ± S.D. (n = 6), \*P<0.05, P<0.001 vs. Control; #P<0.05, P<0.001 vs. ISO; @P<0.05, P<0.001 vs. CoQ10+ISO; ^P<0.05, P<0.001 vs. MgSO<sub>4</sub>+ ISO (one way ANOVA).

in combination. The IC<sub>50</sub> value of the ascorbic acid were found to be 24.54 µg/ml and IC<sub>50</sub> value of CoQ10 were found to be 41.82 mg/ml, and that of the CoQ10 along with MgSO<sub>4</sub> were found to be 25.58 mg/ml. CoQ10 shows antioxidant activity which was found to be comparatively less than ascorbic acid as depicted in Table 1.

### In vivo study

#### Effect of CoQ10 and Magnesium sulphate on heart weight to body weight ratio

The effects of CoQ10, MgSO<sub>4</sub> & Isoproterenol treatment on heart weight, body weight and heart weight to body weight ratio are depicted in Table 2. There was no significant difference in the body weight between the groups observed, although isoproterenol treated animals showed a slight reduction in body weight which was not significant. The heart weight and the heart weight to body weight ratio was increased significantly (p<0.001) in isoproterenol-

administered rats as compared to control rats. However, rats pretreated with CoQ10 and Magnesium sulphate treatment show significant decrease in the heart weight/body weight ratio when compared to Isoproterenol treated group.

#### Effect of CoQ10 and magnesium sulphate on cardiac marker enzymes

The effects of CoQ10, magnesium sulphate and isoproterenol treatment on cardiac marker enzymes are depicted below. The levels of cardiac marker enzymes AST, ALT, LDH and CK-MB were significantly increased in the serum of Isoproterenol administered rats in comparison with the control group as shown in Tables 3 and 4. The levels of cardiac marker enzymes AST, ALT, LDH and CK-MB were significantly increased in the serum of Isoproterenol administered rats in comparison with control group. Pretreatment with CoQ10 and Magnesium sulphate in combination showed a significant (p<0.001) decrease in the

**Table 3.** Serum marker level in all groups before induction of myocardial damage

Groups	Control	ISO	CoQ10+ISO	MgSO <sub>4</sub> +ISO	CoQ10+MgSO <sub>4</sub> +ISO
AST (U/L)	68.83±2.22	66.30±1.89	66.83±1.91	74.18±1.84	57.46±1.93
ALT (U/L)	34.90±2.40	35.50±1.76	43.28±0.99	37±2.36	35.08±2.65
LDH (U/L)	126.93±0.88	123.66±2.65	125.51±2.27	128.5±1.87	123.75±2.28
CK-MB (IU/L)	116.5±1.43	118.5±3.39	111.16±2.69	125.66±2.73	114.16±3.06

**Table 4.** Effect of CoQ10 and Magnesium sulphate on cardiac marker enzymes

Groups	Control	ISO-treated	CoQ10+ISO	MgSO <sub>4</sub> +ISO	CoQ10+ MgSO <sub>4</sub> +ISO
AST (U/L)	67.70±2.14	166±3.27*	107.44±2.68 <sup>#</sup>	118.78±3.33 <sup>#</sup>	84.59±2.95 <sup>#@^</sup>
ALT (U/L)	35.20±1.63	74.39±2.31*	56.60±1.41 <sup>#</sup>	63.58±2.32 <sup>#</sup>	50.77±1.32 <sup>#@^</sup>
LDH (U/L)	128.91±3.03	280.22±4.14*	172.05±2.10 <sup>#</sup>	182.54±3.18 <sup>#</sup>	144.82±4.12 <sup>#@^</sup>
CK-MB (IU/L)	121.64±2.82	307.42±3.11*	162.65±3.20 <sup>#</sup>	161.17±4.04 <sup>#</sup>	135.07±1.24 <sup>#@^</sup>

Results are expressed as mean ± S.D. (n=6). \*P<0.001 vs. Control; #P<0.0001 vs. ISO; @P<0.001 vs. CoQ10+ISO; ^P<0.0001 vs. MgSO<sub>4</sub>+ ISO (one way ANOVA)

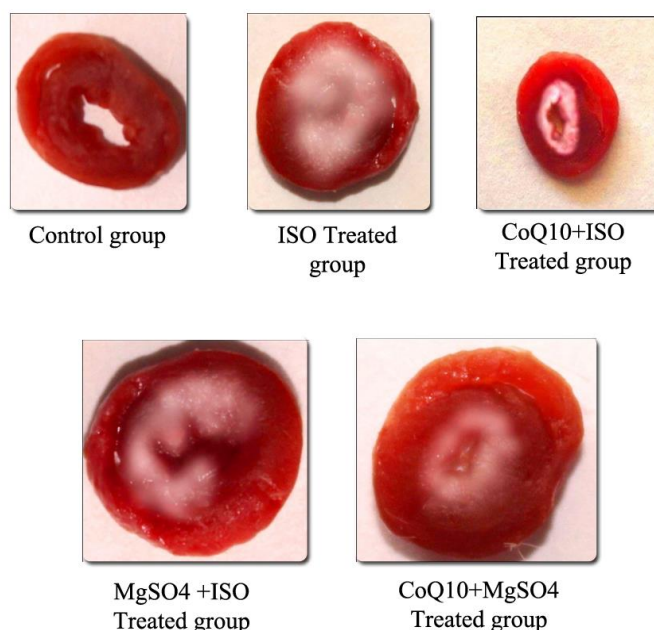


Figure 1. Images of heart slice showing extent of damage

Table 5. Effect of CoQ10 & Magnesium sulphate pretreatment on % infarct size

S.No.	Groups	%Infarct size
1.	Control	No damage
2.	ISO-treated*	52.48%
3.	CoQ10+ISO <sup>#</sup>	33.32%
4.	MgSO <sub>4</sub> +ISO <sup>#</sup>	46.13%
5.	CoQ10+ MgSO <sub>4</sub> +ISO <sup>#@^</sup>	21.61%

All values are expressed as mean  $\pm$  S.D. (n = 4). \*P<0.05 vs. Control; # P<0.05 vs. ISO; @ P<0.05 vs. CoQ10+ISO; ^ P<0.05 vs. MgSO<sub>4</sub>+ ISO (one way ANOVA)

levels of all serum marker enzymes as compared to Isoproterenol treated group.

#### Measurement of myocardial infarct size

Representative illustrations of damage size using TTC staining are shown in Figure 1 and Table 5. ISO administration indicated a large unstained area with more necrotic patches. However, the heart slice of the CoQ10+MgSO<sub>4</sub>+ ISO treated rats exhibited a major portion stained positively showing tissue viability with less necrotic tissues as compared to individual treated group. Figure 1 and also indicates the increased damage size in ISO administered group (52.48%), which were significantly (p<0.001) reduced to 21.61% with the combined pretreatment of CoQ10 and Magnesium sulphate.

#### In vivo lipid peroxidation

To determine the lipid peroxidation, MDA levels were measured in serum and myocardial homogenates. Both serum and heart MDA levels were considerably increased (p<0.001) in isoproterenol alone treated rats in comparison with normal control group. However, treatment with CoQ10 and MgSO<sub>4</sub> significantly reduced the rise of MDA levels of serum and myocardium. The value of MDA in serum and tissue were calculated from standard curve of MDA as indicated in Tables 6 and 7.

#### Effect of CoQ10 and Magnesium sulphate on histopathology of myocardium

Histopathological observation of normal control group

Table 6. Absorbance of serum and Heart tissue sample for lipid peroxidation assay

S.No.	Groups	Serum			Heart Tissue		
		Absorbance at 530nm			Absorbance at 530nm		
1.	Control	0.428	0.398	0.456	0.123	0.182	0.165
2.	ISO-TREATED	1.982	1.894	1.858	0.836	0.891	0.848
3.	CoQ10+ISO	1.002	1.104	0.982	0.484	0.512	0.496
4.	MgSO <sub>4</sub> +ISO	1.412	1.346	1.432	0.652	0.576	0.656
5.	CoQ10+MgSO <sub>4</sub> +ISO	0.633	0.651	0.612	0.364	0.268	0.312

**Table 7.** Effects of CoQ10 and MgSO<sub>4</sub> on MDA levels in the serum and heart tissue

S.No.	Groups	MDA content (nmol/ml serum)	MDA content (nmol/mg tissue)
1.	Control	5.32±0.40	1.56±0.42
2.	ISO-treated	25.91±0.88*	11.30±0.40*
3.	CoQ10+ISO	13.67±0.90 <sup>#</sup>	6.29±1.96 <sup>#</sup>
4.	MgSO <sub>4</sub> +ISO	18.74±0.61 <sup>#</sup>	8.11±0.62 <sup>#</sup>
5.	CoQ10+MgSO <sub>4</sub> +ISO	8.16±0.27* <sup>#@^</sup>	3.77±0.69 <sup>#@^</sup>

All values are expressed as mean ± S.D. (n = 3). \*P<0.05vs. Control; # P<0.05, P<0.001 vs. ISO;@ P<0.001 vs. CoQ10+ISO; ^ P<0.001 vs. MgSO<sub>4</sub>+ ISO (one way ANOVA).

**Table 8.** Histopathological changes in rat myocardium of different experimental groups

S.No.	Groups	Myonecrosis	Inflammation	Oedema
1.	Control	—	—	—
2.	ISO-treated	+++++	+++++	+++++
3.	CoQ10+ISO	++	++	++
4.	MgSO <sub>4</sub> +ISO	+++	+++	+++
5.	CoQ10+MgSO <sub>4</sub> +ISO	+	+	+

(+++++): severe; (+++), (++) : moderate; (+): mild; (-): nil

exhibited clear integrity of myocardial membrane. Isoproterenol treated hearts showed widespread subendocardial necrosis, hypertrophy, infiltration of inflammatory cells and abundant fibroblastic hyperplasia along with increased edematous intramuscular space. The tissue sections from all treatment groups showed some infiltration with neutrophil granulocytes, interstitial edema and some discontinuity with adjacent myofibrils but the morphology of cardiac muscle fibers was relatively well preserved with no evidence of focal necrosis when compared to ISO induced group.

Combination of CoQ10 and MgSO<sub>4</sub> showed a better morphology than individual treatment groups as clearly observed from Figure 2 and Table 8.

### IMMUNOHISTOCHEMISTRY

The expression of  $\alpha$  Smooth Muscle Actin (SMA) in the heart of normal and ISO administered rats are shown in Fig. 3. Immunohistochemical analysis showed that ISO injection significantly ( $p<0.05$  or  $p<0.001$ ) increased the expression of  $\alpha$  Smooth Muscle Actin in the myocardium after 30<sup>th</sup> days, compared to control rats. That marker indicates the expression of high amount of stainable collagen with complex remodeling and reduplication of the collagen fiber network of the myofibril threads. Vimetin (pathological cardiac protein express during infarction) was expressed weakly in vessel wall, but stain densely in the inflammatory infiltrate. Both histological and immunohistochemical figures of ISO induced group confirms a necrotic debris around cardiac myocyte which was completely infarcted and shown infiltration of inflammatory cells which has been significantly reduce in remaining treated groups. At the initial time the expression of  $\alpha$  SMA in infarcted areas were restricted to vascular structure was not significant at any group (data not shown). At this time, these immunoreactive cells could be seen within areas displacing myocytes (Fig. 3C). By the end of the experimental time period myocyte cells stained with  $\alpha$ -SMA appeared more delicately

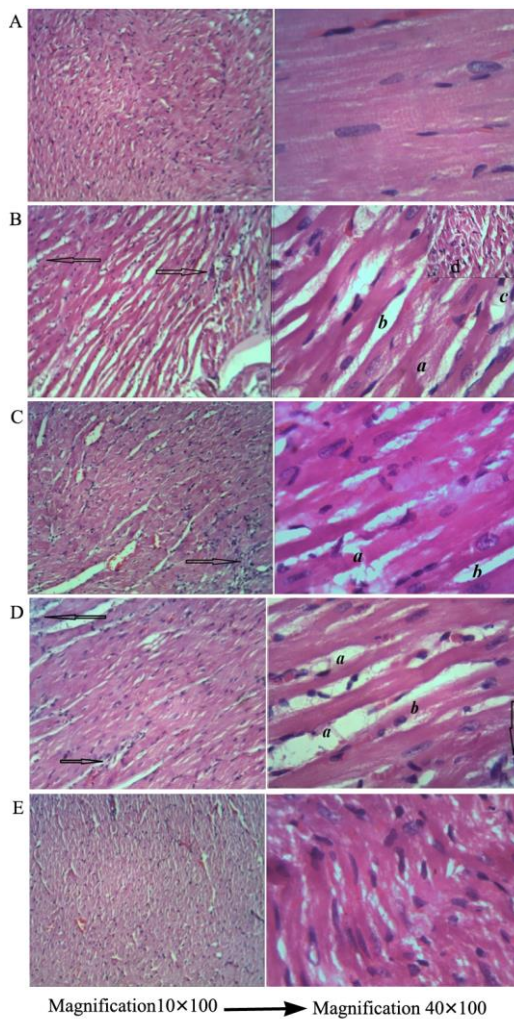
filamentous than initial days. However, by the treatment of combination of CoQ10 and Magnesium sulphate the expression of  $\alpha$  Smooth Muscle Actin ( $\alpha$ -SMA) protein marker was down regulated ( $p<0.001$ ), when compared to ISO groups.

### DISCUSSION

Myocardial damage (MI) is major health problem and one of the leading causes of morbidity and mortality worldwide. MI occurs due to imbalance between myocardial blood supply and demand resulting in development of ischemia followed by necrosis [36]. Isoproterenol which is a synthetic catecholamine and  $\beta$ -adrenergic agonist, by its positive inotropic and chronotropic actions increases the myocardial oxygen demand that leads to ischemic necrosis [37].

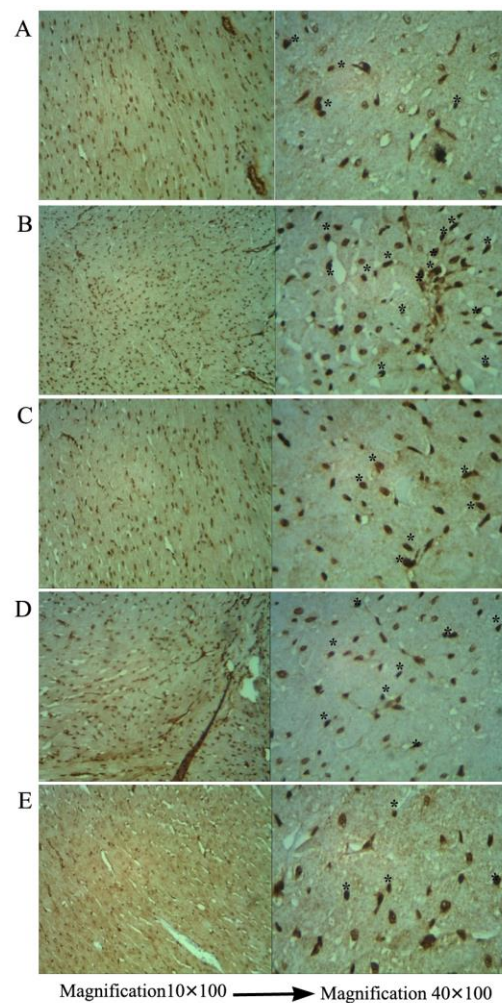
In the present study, cardio protective effect of CoQ10 and CoQ10+ MgSO<sub>4</sub> were evaluated by *in vitro* study and *in vivo* study. The antioxidant activity of CoQ10 and CoQ10+ MgSO<sub>4</sub> were determined according to the reducing power method using spectrophotometer. It was observed that the CoQ10 have demonstrated dose dependent increase in the reducing property. In contrast, MgSO<sub>4</sub> did not show any reducing power activity. However combination of both showed increase in percentage of reducing power activity.

Relative increase in heart weight is an index of cardiac hypertrophy. Hypertrophy observed is a compensatory response to necrosis of the heart muscle, caused by the severe stress of the heart induced by administration of ISO [38]. It may be due to the increase in overall protein biosynthesis during development of hypertrophy accompanied by edema or over expression of genes encoding proteins involved in the contractile unit [39]. The elevation of cytoplasmic calcium during MI could also be a factor responsible for the activation of intracellular signals governing the hypertrophic response of cardiac cells. Increase in heart weight might be attributed to increased



**Figure 2.** Optical microscopic images of heart muscle, (Haemotoxylin and Eosin, presenting with Magnification $10\times 100$  and Magnification  $40\times 100$ ), A. Photomicrograph showing normal architecture of rat heart in control groups, B. Photomicrograph of rat heart of ISO treated group: a. subendocardial necrosis; b. increased edematous intramuscular space; c. fibroblastic hyperplasia; d. edema; Arrows represent prominent area of infiltrations of inflammatory cells, C. Photomicrograph of rat heart of CoQ10 treated group, showing less myocardial injury, less intramuscular space and inflammatory cells. Arrow represent prominent area of infiltrations of inflammatory cells, D. Photomicrograph of rat heart of MgSO<sub>4</sub> treated group, showing less intramuscular space and inflammatory cells. a. infiltration of inflammatory cells; b. intramuscular space; Arrows represent infiltrations of inflammatory cells, and E. Photomicrograph of rat heart of CoQ10+MgSO<sub>4</sub> treated group showing least myocardial injury, clear nuclear and myocytes architecture nearly similar to control group.

water content, edematous intramuscular space [40] and increased protein content. In the present study there has been significant increase in the heart weight and the heart weight to body weight ratio (i.e. Heart relative weight) in ISO



**Figure 3.** Immunohistochemical images of myocardium showing expression of  $\alpha$ -Smooth Muscle Actin ( $\alpha$ -SMA) (representing with Magnification $10\times 100$  and Magnification  $40\times 100$ ), \* indicate expression of  $\alpha$ -SMA. A. Immune histochemical expression of  $\alpha$  Smooth muscle actin ( $\alpha$ SMA) in myocardium of Control group, B. Immunohistochemical expression of  $\alpha$  Smooth muscle actin ( $\alpha$ SMA) in myocardium of ISO-treated group, C. Immunohistochemical expression of  $\alpha$  Smooth muscle actin (SMA) in myocardium of CoQ10 pretreated group, D. Immunohistochemical expression of  $\alpha$  Smooth muscle actin (SMA) in myocardium of MgSO<sub>4</sub> pretreated group, and E. Immunohistochemical expression of  $\alpha$  Smooth muscle actin (SMA) in myocardium of CoQ10+MgSO<sub>4</sub> pre-treated group.

induced rats. It is possible that CoQ10 improves cardiac bioenergetic whereas Magnesium sulphate is natural calcium antagonist, thus reducing calcium overload during stress condition.

Myocardial cells contain several enzymes and macromolecules which on metabolic damage release the extracellular fluid and serve as diagnostic markers of myocardial injury [40]. The release of these enzymes reflects an alteration in the plasma membrane integrity and permeability in response to  $\beta$ -adrenergic stimulation. Measurement of AST, ALT, CK, and LDH activities is

necessary to ascertain extent of myocardial injury. In present study conducted, ISO administration caused a rise in the level of diagnostic marker enzymes AST, ALT, LDH, and CK due to leakage from tissue to blood serum as a result of damaged or destroyed cardio myocytes, as well as, the cells damaged because of insufficient supply of oxygen and oxidative damage of myocardium which render the cell membrane fragile, porous, or ruptured. The increased levels of these enzymes are indicative of severity of cell necrosis and ISO mediated per oxidative myocyte injury. In this study, isoproterenol injected rats showed significant elevation in the levels of these marker enzymes in serum, and indicates ISO induced necrotic damage of the myocardium and leakiness of the plasma membrane. The combination of CoQ10 and Magnesium sulphate seems to preserve the structural and functional integrity and/or permeability of the cardiac membrane and thus restricting the leakage of these indicative enzymes as evident from the markedly decreased levels of these enzymes in CoQ10+MgSO<sub>4</sub> +ISO group when compared to the individual treatment groups, thereby establishing the cardio protective effect of the combination of CoQ10 and Magnesium sulphate

Extent of myocardial damage was detected by direct staining with TTC dye. In the present study we observed an increased infarct size which is indicated by a clear bright/yellow color spot in the heart slices of ISO induced rats. The utilization of NADH by the free radicals produced by ISO and leakage of dehydrogenase enzymes from the damaged myocardial cells are the possible mechanisms that might prevented the conversion of TTC in to TPF. This may be the reason for the colorless bright spot in ISO induced rat heart and reflects the presence of non-viable cells. This finding was also supported by the increased levels of LDH in the serum of ISO induced rats, where LDH might release out from the myocardium. This ISO induced loss of dehydrogenases was counteracted by the co administration of CoQ10 & Magnesium sulphate. The increased damage area in ISO administered group (52.48%), which was significant ( $p < 0.001$ ) reduced to 21.61% with the combined pre-treatment of CoQ10 and MgSO<sub>4</sub> further supporting the better protection from cardiac damage of the combination. This can be supported by the explanation that CoQ10 is a membrane stabilizer and preserves myocardial sodium-potassium ATPase activity and stabilizes myocardial calcium dependent ion channels, thus providing energy and enhancing contractile function in the failing heart. Also Magnesium has ability to inhibit myocardial cell sodium and calcium influx as well as potassium egress, thereby diminishing infarct-related reperfusion injury and limiting infarct size.

Lipid peroxidation is an important pathogenic event in MI and accumulation of oxidants makes the cell membranes more susceptible to oxidative injury and formation of lipid peroxidation product, MDA that reflects the damage of the myocardial cell contents. A significant increase in the levels of lipid peroxidation products in ISO induced rats appear to

be the initial stage to the tissue making it more susceptible to oxidative damage. Increased production of free radicals may be responsible for the observed membrane damage as evidenced by the elevated lipid peroxidation in terms of TBARS in the present study. However, pre-treatment of rats with CoQ10 and MgSO<sub>4</sub> significantly diminished cardiac tissue /serum MDA concentration which can be ascribed to the enhanced activities of antioxidant status in myocardium. MgSO<sub>4</sub> can also reduce *in vivo* LPO possibly by reducing catecholamine's secretion radicals. It has previously been shown that Mg blocks free radical formation both in cell cultures and *in vivo* [41]. Our study revealed that CoQ10 in combination with Magnesium sulphate had shown marked decreased in level of MDA thus mitigating lipid peroxidation.

Histopathological observation of normal control group exhibited clear integrity of myocardial membrane. Architectural changes found in Isoproterenol treated cardiomyocytes.

Stress induced hypertrophy creates structural alteration, subendocardial necrosis, infiltration of inflammatory cells and abundant fibroblastic hyperplasia along with increased edematous intramuscular space. The tissue sections from all treatment groups showed some infiltration with neutrophil granulocytes, interstitial edema and some discontinuity with adjacent myofibrils but the morphology of cardiac muscle fibers was relatively well preserved with no evidence of focal necrosis when compared to ISO induced group. Combination of CoQ10 and MgSO<sub>4</sub> showed a better morphology than individual treatment groups.

Activation of fibroblast to myofibroblast is the hallmark of cardiac fibrosis. Immunohistochemical analysis confirms, above 90% of co-expressed  $\alpha$ -SMA suggesting the activation of myofibroblast in Isoproterenol induce infarcted rat heart. In rat myocardial study the expression of  $\alpha$  SMA was found in the spindle shaped cells. Expression of myofibroblast elevates the pressure overload of right ventricle. Isoproterenol induce group clearly indicates a heterogenous immunophenotype of myofibril, nuclear pigmentation and Vimetin expression staining through  $\alpha$  SMA stain whereas CoQ10 with MgSO<sub>4</sub> group shows significant reduction in the co expression of vimetin in the zone of expression. Further illustration of heterogeneity were characterized in myocardial scar has been clearly expressed through  $\alpha$  SMA. In rat myocardial study the expression of  $\alpha$  SMA was found in the spindle shaped cells. Through immunohistochemical and histological study, sustained expression of basal lamina protein collagen IV in myocardial scar was absent. It possibly might be due to shorter period of ISO exposure. The appearance of myofibrils persists for at least 4 weeks.

## CONCLUSION

The present study demonstrated that the oral pre-treatment with CoQ10 and Magnesium sulphate were associated with moderate protection against ISO-induced cardio toxicity and cardiac hypertrophy. This combination had also shown marked anti lipid per oxidative effect and



lower myocardial injury by reducing serum markers in stress induced group. Cardio protective effect of the combination was confirmed by the histological study by infarct size quantification assay and histo architectural analysis of the myocardium and through the significant reduction of CK-MB cardiac marker in the group containing both these two drug compared to the stressed group. Whereas other single drug treated group was unable to prove handful of improvement in architectural changes followed by biochemical evidences. The present results can form the basis that combination of CoQ10 and magnesium sulphate proved to be a potential therapeutic agent for pharmacological management of ischemic heart disease. Although the study provided a possible new therapeutic tool for myocardial damage, more studies are required to elucidate and precise the mechanism of CoQ10 and magnesium sulphate in reversing the pathogenesis of myocardial damage.

### CONFLICT OF INTEREST

The authors declare that this research does not have any conflict of interest with anyone or any institute.

### REFERENCES

1. Khorrami A, Hammami M, Garjani M, Maleki-Dizaji N, Garjani Ali. Tacrolimus ameliorates function disturbances and oxidative stress in isoproterenol-induced myocardial damage. *DARU J Pharmac Sci* 2014;22:68.
2. Schoen FJ, Mitchell RN. The heart. In: Kumar V, Abbas AK, Aster JC. Robbins and Cotran pathologic basis of disease. Philadelphia: Elsevier, 2015. Fig 12.14- Schematic representation of the progression of myocardial necrosis after coronary artery; 575-579.
3. Mendis S, Puska P, Norrving B, editors. Global Atlas on Cardiovascular Disease Prevention and Control. World Health Organization, Geneva, 2011.
4. Reddy KS. India wakes up to Threat of cardiovascular disease. *J Am College Cardiol* 2007;50:1370-1372.
5. Hegstad AC, Ytrehus K, Myklebust R, Jorgensen L. Ultra structural changes in myocardial myocytic mitochondria: crucial step in the development of oxygen radical induced damage in isolated rat hearts. *Basic Res Cardiol* 1994;89:128-138.
6. Rona G. Catecholamine cardio toxicity. *J Mol Cell Cardiol* 1985; 17:291-306.
7. Yates, JC, Dhalla NS. Induction of necrosis and failure in the isolated perfused rat heart with oxidized isoproterenol. *J Mol Cell Cardiol* 1975;7:807-816.
8. Liehn EA, Postea O, Curaj A, Marx N. Repair after myocardial damage, between fantasy and reality: the role of chemokines. *J Am Coll Cardiol* 2011;58:2357-2362.
9. Kalén A, Appelkvist EL, Dallner G. Age-related changes in the lipid compositions of rat and human tissues. *Lipids* 1989;24:579-584.
10. Molyneux SL, Florkowski CM, George PM, Pilbrow AP, Frampton CM, Lever M, et al. Coenzyme Q10: an independent predictor of mortality in chronic heart failure. *J Am Coll Cardiol* 2008;52:1435-1441.
11. Witte KK, Nikitin NP, Parker AC, von Haehling S, Volk HD, Anker SD, et al. The effect of micronutrient supplementation on quality-of-life and left ventricular function in elderly patients with chronic heart failure. *Eur Heart J* 2005;26:2238-2244.
12. Bergamini Ch, Moruzzi N, Sblendido A, Lenaz G, Fato R. A Water Soluble CoQ10 Formulation Improves Intracellular Distribution and Promotes Mitochondrial Respiration in Cultured Cells. *PLoS ONE* 2012;7(3):e33712
13. Bloom S: Magnesium deficiency cardiomyopathy. *Am J Cardio Path* 1988;2:7-17.
14. R. John Purvis, Movahed Assad. Review on Magnesium Disorders and Cardiovascular Diseases. *Clin Cardiol* 1992;15:556-568.
15. Ferrari R, Albertini A, Curello S, Ceconi C, Di Lisa F, Raddino R, et al. Myocardial recovery during post ischemic reperfusion; effects of nifedipine, calcium and magnesium. *J Mol Cell Cardiol* 1986;18:487-98.
16. Hearse D. Reperfusion ischemic myocardium. *J Mol Cel Cardiol* 1977;9:606-16.
17. Khorrami Arash, Hammami Mojtaba, Garjani Mehraveh, Maleki-Dizaji Nasrin Garjani Alireza. Tacrolimus ameliorates functiona disturbances and oxidative stress in isoproterenol-induced myocardial damage. *DARU J Pharmac Sci* 2014;22:68.
18. Seth SD, Maulik M, Katiyar CK, Maulik SK. Role of lipistat in protection against isoproterenol induced myocardial necrosis in rats: a biochemical and histopathological study. *Ind J Pharmacol* 1998;42(1): 101-106.
19. Ivanov A, Tokareva O, Gorodetskaya E, Kalenikova E, Medvedev O. Cardio protection with Intravenous Injection of Coenzyme Q10 is limited by Time of Administration after Onset of Myocardial Damage in Rats. *Clin Experim Cardiol* 2014;5(4):1-6
20. Garson Ch, Kelly-Laubscher R, Blackhurst D, Gwanyanya A. Lack of cardioprotection by single-dose magnesium prophylaxis on isoprenaline-induced myocardial infarction in adult Wistar rats. *Cardiovasc J Afr.* 2015 Nov-Dec;26(6):242-249.
21. Jalal AN, AL Yasseri ARK, Kadhim HA. Histopathological monitoring of cardio protective effects of MgSO4, pioglitazone and omega-3 fatty acids in rabbits induced with myocardial damage. *Kufa Med J* 2009;12:476-480.
22. Arvind kumar EG, Chetan PK, Subhash LB, Vijaya AP. Effect of Pretreatment with Coenzyme Q10 on isoproterenol- induced Cardio toxicity and Cardiac Hypertrophy in Rats. *Curr Ther Rse* 2009;70:460-471.
23. Indian Pharmacopoeia. Vol-1: Published by Indian Pharmacopoeia commission Ghaziyabad; 427-428.
24. Expert panel of the IFCC on enzymes, *Clin Chem Acta.* 1976;70: F19.
25. Searey RL, *Diagnostic Biochemistry* McGraw-Hill, New York, NT 1969.
26. Tietz Textbook of Clinical Chemistry and Molecular Diagnostics. Burtis CA, Ashwood ER, Bruns DE; 5th edition, WB Saunders Comp., 2012.
27. Henry RJ, Chiamori N, Golub OJ, Berkman S. *Am J Clin Path* 1960; 34(341):1960.
28. Bremmer FW. Cardiac disease and hyper tension in "Clinical Chemistry theory, analysis and correlation. Kaplan L and Pesce A (Ed) CV Mosby company, 1987.
29. Fishbein MC, Meerbaum S, Rit J, Londo U, Kanmatsuse K, Mercier JC, et al. Early phase acute myocardial infarct size quantification: validation of the triphenyl tetrazolium chloride tissue enzyme staining technique. *Am Heart J.* 1981;101:593-600.
30. Lie JT, Pairolero PC, Holley KE, Titus JL. Macroscopic enzyme mapping verification of large, homogenous, experimental myocardial infarcts of predictable size and location in dogs. *J Thorac Cardio Sur* 1975;69:599-605.
31. www.oxfordbiomed.com
32. Slater TF, Sawyer BC. The stimulatory effect of carbon tetrachloride and other halogenalkane or per oxidative reactions in the rat liver function in vitro. *Biochem J* 1971;123:805-815.
33. Bull AW, Marnett LJ. *Analyt Biochem* 1985;149:284-290.
34. Willems Ingrid EMG, Havenith Michael G, De Mey Jo GR, Daemen Mat JAP. The  $\alpha$ -Smooth Muscle Actin-Positive Cells in Healing Human Myocardial Scars. *Am J Pathol* 1994;145(4):869.
35. De Bono DP, Boon NA. Diseases of the cardiovascular system. In: Edwards CR, Boucheir IA, editors. Davidson's principles and practice of medicine. Hong Kong: Churchill Livingstone; 2002:249-340.
36. Nandave M, Mohanty I, Nag TC, Ojha SK, Mittal R, Kumari S, et al. Cardio protective response to chronic administration of vitamin E in Isoproterenol induced myocardial necrosis: hemodynamic, biochemical and ultra-structural studies. *Ind J Clin Biochem* 2007;22(1):22-28.

37. Zaki Ahmed A, Hashish Nadia E, Amer Mohamed A, Lahloub Mohamed-Farid. Citrus medica "Otroj": Attenuates Oxidative Stress and Cardiac Dysrhythmia in Isoproterenol-Induced Cardiomyopathy in Rats. *Chin Natural Med* 2014;12(5):0345–0350.
38. Heather LC, Catchpole AF, Stuckey DJ, Cole MA, Carr CA, Clarke K. Isoproterenol induces in vivo functional and metabolic abnormalities; similar to those found in the infarcted rat heart. *J Physiol Pharmacol* 2009;3:31-39.
39. Upaganlawar A, Gandhi C, Balaraman R. Effect of green tea and vitamin E combination in isoproterenol induced myocardial damage in rats. *Plant Foods Hum. Nutrition* 2009;64:75–80.
40. Judd JT, Wexler BC. Myocardial glycoprotein changes with isoproterenol induced necrosis and repair in the rat. *Am J Physiol* 1974;226: 597–602.
41. Goyal S, Arora S, Bhatt TK, Das P, Sharma A, Kumari S, et al. Modulation of PPAR- $\gamma$  by telmisartan protects the heart against myocardial damage in experimental diabetes. *Chemico-Biol Interact* 2010;185(3):271–280.