

Wound Healing Activity of *Mimusops elengi* Leaves

M. SWAPNA REDDY¹, SWAPNA ALETI², JA SNEHA³, and NVL SUVARCHALA⁴

For author affiliations, see end of text.

Received March 16, 2013; Revised July 9, 2013; Accepted September 21, 2013

This paper is available online at <http://ijpt.tums.ac.ir>

ABSTRACT

In the present investigation, methanolic extract of *Mimusops elengi* leaves were evaluated for wound healing activity. Entire wound healing process is complex series of events that begins at the moment of injury and can continue for months to years. Methanolic extract of *Mimusops elengi* leaves were examined for wound healing activity in the form of ointment by the excision, the incision and dead space wound model in mice. The extract ointments showed considerable wound healing properties with excision wound model ($p < 0.001$), incision wound model ($p < 0.05$), and dead space wound model ($p < 0.05$) when results were compared with control. Standard used for the present study was Betadine ointment in terms of wound contracting ability, wound closure time, tensile strength and dry granuloma weight. Results obtained clearly indicated that methanolic extract of *Mimusops elengi* leaves exhibit significant wound healing properties.

Keywords: *Mimusops elengi*, Wound healing, Betadine, Methanolic extract

Mimusops elengi known as Bakul (Family-Sapotacea) is a large ornamental evergreen tree cultivated in India and reared in gardens for sake of its fragrant flowers. In traditional and folk system of medicine, bark, fruit and seeds of *Mimusops elengi* possess several medical properties such as astringent, tonic and febrifuge in dental disease and uterine disorders [1-4]. This plant has also been reported for antiulcer, diuretic, analgesic, antipyretic, anti-inflammatory and anti-microbial activities [5-7]. Phytochemical evaluation showed presence of alkaloids, flavonoids, tannins, steroids, triterpenoids, saponins [8-16].

Wounds are visible results of individual cell death or damage. It is a disruption of tissue integrity that is typically associated with a loss of substance. It is an intricate process in which the skin repairs itself after injury in normal skin. The epidermis and dermis exist in steady state equilibrium, forming protective barriers against external environment. Stages of wound healing are inflammatory phase, proliferation phase, fibroblastic phase and maturation phase. Herbal medicines are crucial in wound healing since they initiate disinfection,

debridement and providing a moist environment to encourage the establishment of natural healing process [17-18].

Literature search revealed that *Mimusops elengi* bark possess wound healing activity [19] but there is no report regarding wound healing activity of *M. elengi* leaves. Thus, the present study was undertaken to investigate wound healing activity of methanolic extract of *M. elengi* leaves.

MATERIALS AND METHODS

Plant material

The leaves of *M. elengi* were collected from medicinal garden of Vaagdevi Pharmacy College, Warangal and authenticated by Prof. Raju S. Vastavaya, Associate Professor, Dept. of Botany, Kakatiya University, Warangal.

Extraction and preparation of formulation

The plant material was dried in shade, powdered and sieved through 40 mesh (100 g) and extracted in Soxhlet

Table 1. Effect of methanolic leaf extract ointment of *Mimusops elengi* Linn on excision wound model

Group	Treatment	Epithelizaion period	Wound area in mm ² (% wound contraction)				
			3rd Day	6 th Day	9 th Day	12 th Day	14 th Day
1	Control	22 nd days	76.27 ± 8.10 (23.12%)	58.62 ± 5.18 (41.21%)	45.25 ± 1.62 (54.72%)	31.42 ± 6.12 (69.15%)	18.62 ± 6.12 (83.68%)
2	Standard-treated	13 th days	41.22 ± 4.19 (46.78%)	36.75 ± 6.47 (63.25%)	10.66 ± 5.23 (89.34%)	0.58 ± 0.68* (99.42%)	0.3 ± 0.30** (99.70 %)
3	Extract-treated	16 th days	67.41 ± 3.12 (33.62%)	41.45 ± 4.13 (54.67%)	14.31 ± 0.62 (85.65%)	7.42 ± 1.08* (92.47 %)	0.67 ± 0.58** (99.31%)

Results were expressed as mean ± SD (n = 6), **p* < 0.05, ***p* < 0.001 vs. Control.

apparatus for 12 h with methanol, concentrated and dried under reduced pressure. The extract was weighed and yield was calculated to be 32.82% w/v. Semisolid mass (dark green color) obtained was used as ingredient for 5% ointment preparation. About 5g of semisolid extract was incorporated into 100 g (w/w) of simple ointment base B.P.

Animals

Healthy Wistar Albino mice of either sex (30-45 g) were used for present study and fed on standard diet and water ad libitum. These animals were housed at room temperature (25 ± 10°C), relative humidity 45-55% and 12:12 h light/dark cycle. The protocol followed was approved by Institutional Animal Ethics committee (IAEC) under CPCSEA Committee before animal experimentation.

Wound healing activity

Screening for wound healing activity was performed. For incision, excision and dead space wound model, 54 animals of either sex weighing between 35 to 40 g were divided in each model consisting of six animals.

Effect of methanolic extract ointment of *Mimusops elengi* Linn on excision wound model

The hair on the skin of animals were removed using a suitable depilatory (Anne-French hair removing cream) and circular wounds of approximately 10 mm diameter were inflicted on the cleared skin by cutting under mid Xylocain 4% topical anesthesia. The areas of the wounds were measured (mm²) immediately by using vernier calipers. This was taken as the initial wound area reading. Group-I animals served as negative control, Group-II served as positive control (applied topically Betadine 5% w/w in ointment I.P) and Group-III animals were treated with the extract ointment topically (5% w/w). All the test samples were applied once daily. The wound area of each animal was measured on 1st, 3rd, 6th, 9th, 12th, 14th and 16th post wound day. The wound closure was measured at regular intervals of time to get the percentage of wound closure and epithelialization time that indicates the formation of new epithelial tissue to heal the wound. Wound contraction and epithelialization time of an excision

wound margin was traced after wound creation using a transparent paper and the area was measured by vernier calipers. Wound contraction was measured in each 2 day interval, until complete wound healing and it was expressed in percentage of healed wound area. The epithelialization time was measured from initial day [20]. The healing tissues obtained on the 16th day from all three groups of animals of the excision wound model were processed for histological study. Sections were qualitatively assessed under the optical microscope and observed in respect of fibroblast proliferation, collagen formation, epithellization and blood vessels

Effect of methanolic extract ointment of *Mimusops elengi* Linn on insicion wound model

In incision wound model, Group-I animals served as negative control, Group-II served as positive control (applied topically Betadine 5% w/w in ointment I.P) and Group-III animals were treated with the extract ointment topically (5% w/w). All animals were anaesthetized before wound creation and paravertebral long incisions were made through the skin at the distance of about 1.5 cm from midline on the depilated back of mice. No local or systemic antimicrobials were used throughout the experiment. Both the edges of wound were kept together and stitched with black silk surgical thread (no. 000) and a curved needle (no.11). The continuous threads on wound edges were tightened for good closure of the wound. After stitching, wound was left undressed then simple ointment base, standard ointment and extract ointment were applied daily up to 9 days. The wounds tissues were removed on the 10th day and tensile strength of cured wound skin was measured using tensiometer. The skin breaking strength was expressed as the minimum weight (grams) of water necessary to bring about the gapping of the wound [17-21].

Effect of nethanolic extract ointment of *Mimusops elengi* Linn on dead space wound model: histopathological studies

In Dead space wound model, Group-I animals served as negative control, Group-II served as positive control (applied topically Betadine 5% w/w in ointment I.P) and Group-III animals were treated with the extract ointment topically (5% w/w). Animals were

Table 2. Effect of methanolic extract ointment of *Mimusops elengi* Linn on incision wound model

Group	Treatment	No. of Animals	Tensile strength in gm/cm on 10th post wound day
1	Control	6	162.41 ± 2.32
2	Standard-treated	6	287.41 ± 2.68*
3	Extract treated	6	242.75 ± 2.71*

Results were expressed as mean ± SD, **p* < 0.05 vs. Control.

Table 3. Effect of methanolic extract ointment of *Mimusops elengi* Linn on dead space wound model

Group	Treatment	No. of Animals	Granulation tissues dry-weight (mg/100g)	Tensile strength on 10th post wounding day (g/cm)
1	Control	6	32.5 ± 1.18	136.75 ± 2.30
2	Standard-treated	6	53.5 ± 1.19*	327.25 ± 2.10*
3	Extract-treated	6	49.5 ± 1.17*	252.5 ± 2.80*

Results were expressed as mean ± SD, **p* < 0.05 vs. control

anaesthetized by Xylocain 4% topical anesthesia and wound was made by implantation of cotton pellets (10 mg), (2.0 × 0.5), one on side, in the lumber region on the dorsal surface of each animal. On the 10th post-wound day, granuloma tissue formed on implanted cotton pellets were dissected out carefully. Granuloma tissue from one part was dried and weighed, while the other part of granuloma tissue was used for determination of tensile strength [22-23]. Wound tissue specimens from control, test and standard groups were taken after complete healing of excision wound. After usual processing, 6 mm thick sections were cut and 10% of formalin solution was used to fix the granulation tissues for 24 h and dehydrated with a sequence of ethanol-xylene series of solutions. The inflicted

materials were embedded with paraffin at 40-600C. Microtome sections were taken at 10 µm thicknesses. The processed sections were stained with Haematoxylin and observed under microscope [24-26].

Statistical analysis

Treated group was compared with the control group. The results were analyzed statistically using Student’s t-test to identify the differences between the treated and control groups. The data considered significance at *p* < 0.05.

RESULTS AND DISCUSSION

In this work, the 5% (w/w) extract-ointment-treated groups showed significant wound healing from the sixth

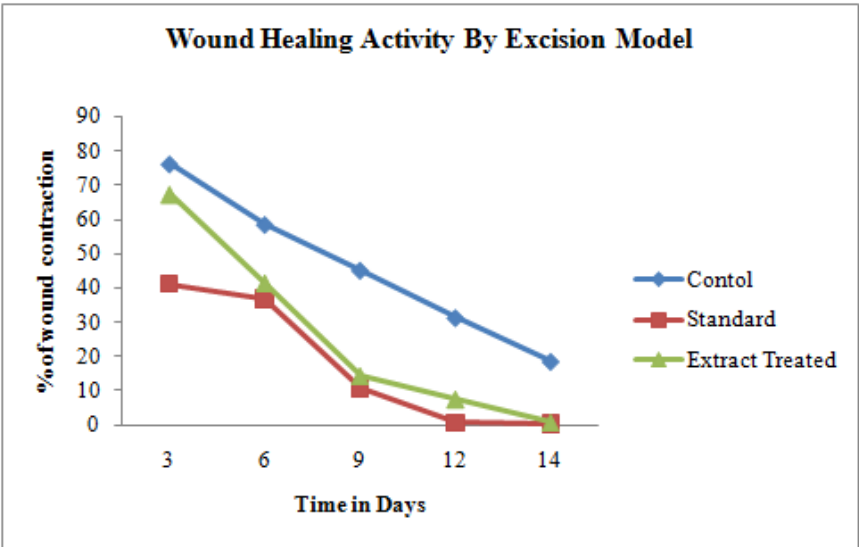


Fig 1. Effect of Methanolic Extract Ointment of *Mimusops elengi* Linn on Exsicion Wound Model

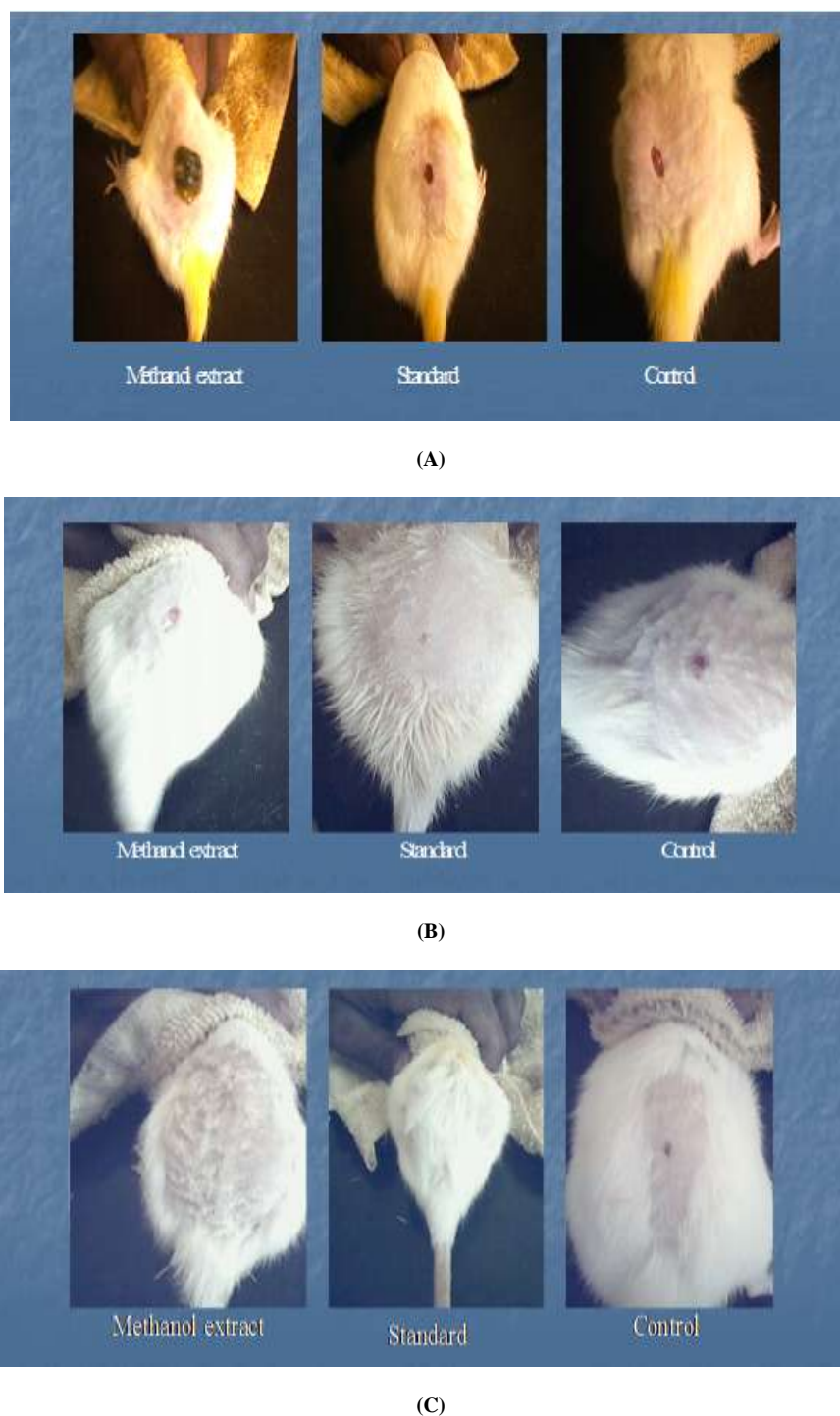

Fig 2. Excision Wound Model on (A) 0 Day, (B) 8th Day and (C) 16th Day

day onwards. In 5% (w/w) extract-ointment-treated mice, the wounds were completely healed (epithelization period) in 16 ± 2 days whereas in the control animals it took more than 20 ± 2 days. On day 12, standard-ointment-treated wound was completely healed while extract-ointment-treated wound was also almost at complete healing stage. It was also observed that epitheliazation period of treated and standard group

were less in comparison to simple-ointment-base-treated group (Table 1).

The studies on excision wound healing model revealed that all the three groups showed day to day decrease in wound area. However, on sixteenth post-wounding day, control animals group-I showed 9.63 ± 4.12 of wound area (which might be due to self-immunity of the animals), whereas group-II Betadine

treated animal showed 0.1 wound areas and the treated group-III exhibited 0.2 ± 0.31 wound area. When compared with the control, the activity of extract was found to be highly significant ($p < 0.05$) as shown in Figs 1 and 2.

The promotion of wound healing activity was also well gazed by its tensile strength of the incision wound. Generally, wound-healing agents have the properties to enhance the deposition of collagen content, which provides strength to the tissues and forms cross-linkages between collagen fibers. The tensile strength of the extract-treated group was found to be 242 ± 2.71 which was higher than that of control treated group of animals (162.41 ± 2.32) and slightly less than that of standard-treated group of animals (287.41 ± 2.68) on 10th post wound day (Table 2).

The effect of topical administration of the extract ointment treated group and control group on dead space wound model was assessed by increase in the weight of granulation tissue and increase tensile strength. The data is depicted in Table 3. This indicates enhanced collagen maturation by increased cross-linking of collagen fibers. The increased weight of the granulation tissue indicates the presence of higher protein content in treated animals. The response was found to be significant in extract-ointment-treated animals.

Wound contraction, a part of proliferate phase of wound healing occurs through the centripetal movement of the tissues surrounding the wound, which is mediated by fibroblasts. The increased wound contraction in the treated group might be due to the enhanced activity of fibroblasts *Mimusops elengi* leaf extract. A significant increase in collagen content due to enhanced migration of fibroblasts and epithelial cells to the wound site was observed during the wound healing process in the treated group. A close examination of granulation tissue sections revealed that tissue regeneration was much quicker in the treated group compared with control group. Early dermal and epidermal regeneration in the treated group confirmed that the ointment containing the *Mimusops elengi* extract was shown to have positive effect toward cellular proliferation, granulation tissue formation, and epithelialization. Incomplete epithelialization with less extracellular matrix synthesis was observed in control rats. Clumps of degenerating neutrophils, necrotic changes, and the persistence of inflammatory exudates in the upper dermis were also observed up to 16th day. The treated rats showed marked epithelialization, a moderate amount of extra cellular matrix synthesis and new blood vessel formation.

In conclusion, wound healing activity of methanolic extract of *Mimusops elengi* leaves were investigated by excision wound model, incision wound model and dead space wound model. Methanolic extract of *Mimusops elengi* leaves showed significant wound healing properties. As *Mimusops elengi* leaves extracts showed the presence of alkaloids, tannins, flavonoids, steroids, triterpenoids and saponins, the wound healing effect of methanolic leaf extract of *Mimusops elengi* might be

due to the presence of these compounds. Further pharmacological and biochemical investigation will clearly elucidate the mechanism of action and will be helpful in projecting this plant as a therapeutic agent in wound healing.

REFERENCES

- Gogte VM. Ayurvedic Pharmacology and Therapeutic uses of Medicinal Plants. Mumbai: Bharatiya Vidya Bhavan; 2001; p. 811.
- Kirtikar KR. Indian Medicinal Plants. Dehradun: M/s. Bishensingh Mahendra Palsingh; 1935. pp. 1494–6.
- Misra G, Mitra CR. Constituents of leaves, hard wood and root of *Mimusops elengi*. *Phytochem* 1968; 7:501–2.
- Satyavati GV, Gupta AK. Medicinal Plants of India, 2. New Delhi: Indian Council of Medical Research; 1987. pp. 257–61.
- Shahwar D, Raza A. In vitro antibacterial activity of extract of *Mimusops elengi* against gram positive and gram negative bacteria. *Afri J Micro Res* 2009; 3:458–62.
- Katedeshmuk RG, Shete RV, Otari KV, Bagade MY, Pattewar A. Acute toxicity and diuretic activity of *Mimusops* extracts. *Inter J Pharma Biosci* 2010; 1:1–6.
- Rajkumara S, Pandiselvi A, Sandhiya G. Isolation of Chemical Constituents from *Mimusops elengi* bark and Evaluation of Anti-inflammatory activity. *Inter J Phytopharm* 2012; 3:9–15.
- Manjeshwar SB, Ramakrishna JP, Harshith PB, Princy LP, Rekha B. Chemistry and medicinal properties of the Bakul (*Mimusops elengi* Linn): A review. *Food Res Inter* 2011; 44:1823–9.
- Gami B, Parabia MH. Pharmacognostic evaluation of bark and seeds of *Mimusops elengi* linn. *Inter J Pharma and Pharmaceut Sci* 2010; 2:110–3.
- Mitra R, Yadav KC. Pharmacognostic study of bakul: *Mimusops elengi* linn. *Leaf. Ind J For.* 1980; 3:15–23.
- Jana GK, Dhanamjayarao M, Vani M. Evaluation of anthelmintic potential of *Mimusops elengi* linn. (Sapotaceae) leaf. *J Pharm Res* 2010; 3:2514–5.
- Ganu G, Garud A, Agarwal V, Suralkar U, Jadhav S, Kshirsagar A. Anti-anxiety activity of *Mimusops elengi* barks extract in experimental animals. *Res J Pharmaceut Biol Chem Sci* 2011; 2:405.
- Prakash D, Koti BC, Vijay T, Chandrakala, Katagi MS. Antiulcer activity of *Mimusops elengi* bark extracts against serotonin induced ulcer in rats. *Int Res J Pharm* 2011; 2:173–6.
- Ashok P, Koti BC, Vishwanathswamy AH. Antiuro lithiatic and antioxidant activity of *Mimusops elengi* on ethylene glycol-induced urolithiasis in rats. *Ind J Pharmacol.* 2010; 42(6): 380–383.
- Ali MA, Mozid MA, Yeasmin S, Khan AM, Sayeed MA. An Evaluation of Antimicrobial Activities of *Mimusops elengi* Linn. *Res J Agric Biol Sci* 2008; 4:871–4.
- Murudkar SS, Mundhada PA. Antibacterial activity of *Mimusops elengi* linn bark against dental pathogens. *Ind J Pharm Edu Res* 2007; 41:114–20.
- Gerald SL, Diane MC, David RK, David JM, Roger EP, George R. Definitions and guidelines for assessment of wounds and evaluation of healing. *Wound Repair Regen* 1994; 2:165–70.
- Clark RA. Wound repair an overview and general consideration. In: Clark RA, Henson PM, editors. *Molecular and Cellular Biology of Wound Repair*. The Plenum Press. New York. 1996; 473–88.
- Gupta N, Jain UK. Investigation of wound healing activity of methanolic extract of stem bark of *Mimusops elengi* Linn. *Afri J Tradit Complement Altern med (AJTCAM)* 2011; 898–103.
- Richardson M. Acute Wound: an overview of the physiological healing process. *Nurs Times* 2004; 100:50–3.

21. Diegelmann RF, Evans MC. Wound healing: an over view of acute, fibrotic and delayed wound healing. *Front Biosci* 2004; 9:283-9.
22. Edward R, Harding KG. Bacteria and Wound healing. *Curr Opin Infect Dis* 2004; 17:91-6.
23. Ehrlich HP, Hunt TK. Effect of cortisone and vitamin A on wound healing. *Ann Surg* 1968; 167:324-5.
24. Cross K, Mustoe T. Growth factors in wound healing. *Surg Clin North Am* 2003; 83:531-45.
25. Iba Y, Shibata A, Kato M, Masukawa T. Possible involvement of mast cells in collagen remodeling in the late phase of cutaneous wound healing in mice. *Inter Immunopharmacol* 2004; 4:1873-80.
26. Abdollah GP. Wound Healing Activity of Extracts of *Malva sylvestris* and *Stachys lavandulifolia*. *Int J Biol* 2011; 3:1.

CURRENT AUTHOR ADDRESSES

M. Swapna Reddy, Department of Biotechnology, Gokaraju Rangaraju College of Pharmacy, Hyderabad, Andhra Pradesh, India.

Swapna Aleti, Department of Biotechnology, Gokaraju Rangaraju College of Pharmacy, Hyderabad, Andhra Pradesh, India. Email: swapnapharma@yahoo.co.in (Corresponding author)

J. A. Sneha, Department of Biotechnology, Gokaraju Rangaraju College of Pharmacy, Hyderabad, Andhra Pradesh, India.

N. V. L. Suvarchala, Department of Biotechnology, Gokaraju Rangaraju College of Pharmacy, Hyderabad, Andhra Pradesh, India.