

Effect of Aqueous Extract of Walnut Septum on Blood Glucose and Pancreatic Structure in Streptozotocin-Induced Diabetic Mouse

FARZANEH DEGHANI^{1, 2*}, TAHEREH MASHHOODY³, MOHAMMADREZA PANJEHSHAHIN⁴

For author affiliations, see end of text.

Received April 12, 2011; Revised July 9, 2011; Accepted September 5, 2011

This paper is available online at <http://ijpt.iuums.ac.ir>

ABSTRACT

Walnut is a medicinal plant that its different parts such as leaf, seed, root and green husk was shown to reduce blood glucose. In Iranian traditional medicine, septum of walnut shell (SWS) was recommended to reduce blood glucose. But this effect should be determined with scientific researches. Therefore, the aim of this study is to evaluate the effect of the aqueous extract of SWS on blood glucose and histopathological structure of pancreas. For this purpose, 41 male bulb/C mice 25-30 gm were divided into five groups. All the animals received IP injection of streptozotocin (STZ) (220 mg/kg). Two weeks later, the diabetic animals were received daily oral treatment of normal saline and aqueous extract of SWS (200, 400, 600 and 800 mg/kg) respectively for four weeks. Blood samples were taken from retro-orbital sinus before the start of the experiment and repeated each two week. At the end of experiment, the animals were sacrificed and the pancreatic tissues were fixed, prepared and stained by Hematoxylin-Eosin for light microscope studies. The results showed that in each group, the SWS extract reduced blood glucose in long time ($p < 0.05$), but this effect was not dose-dependent between groups. This study also showed that the SWS extract had not any effect on pancreatic structure. It seems that aqueous extract of SWS may reduce blood glucose without any effect on pancreatic structure. However, more investigations should be done to clarify these results.

Keywords: *Septum of walnut shell, Streptozotocin, Blood sugar, Pancreas, Langerhans' island*

Diabetes mellitus is a metabolic disorder that affect on carbohydrate, lipid and protein metabolism [1-2]. This syndrome is usually accompanied with oxidative stress and changes in antioxidants levels [3]. Common treatments of diabetes are insulin, oral anti-diabetic drugs, exercise and diet [4,5].

Herbal traditional medicines derived mainly from plants have played major role in the management of diabetes mellitus. Researches have shown that some Asian herbal medicine such as Cinnamon, *Senna alata*, seed of Jamun, root of Kadali, *Feronia limonia* Fruit, *Artocarpus heterophyllus* Bark and rhizomes of

Sansevieria senegambica have been demonstrated for diabetes and diabetic complications treatment [6-10].

The decoction of walnut is widely used to treat hyperglycemia in folk medicin. Walnut (*Juglans regia*) is a plant in the family of *juglandaceae*. Various parts of this plant such as leaf, seed, root and Green husk have a significant hypoglycemic effect [11-13]. In Iranian traditional medicine, septum of walnut shell is used for diabetes treating [14-15]. However, scientific studies are necessary to prove this idea. Therefore, the aim of this study is to evaluate the effect of septum of walnut shell (SWS) on blood glucose and histopathological changes in pancreas in diabetic mouse.

Table 1: Effect of aqueous extract of *walnut ridge* on blood glucose level between different groups in streptozotocin -induced diabetic mouse

Groups	FBS Level (mg/dl)			
	1 day	14 day	28 day	42 day
Group1 (STZ+NS) N=6	162.8±8.6	371.3±121.2 *	418.2±199.4 * **	301.5±129.1 * ** ***
Group2 (EXT200mg/kg+STZ) N=9	160.1±25.6	404.9±135.0 *	479.3±239.9 * **	348.3±168.8 * ** ***
Group3 (EXT400 mg /kg+STZ) N=7	146.8±28.8	396.7±126.2 *	451.0±146.5 * **	345.7±121.9 * ** ***
Group5 (EXT800 mg /kg+STZ) N=10	165.0±18.0	322.8±138.6 *	296.4±172.3 * **	215.8±114.9 * **

* $p < 0.05$ compared with 1st day (before injection STZ)

** $p < 0.05$ compared with 14th day

*** $p < 0.05$ compared with 28th day

MATERIALS AND METHODS

Experimental Animals

This study was done from July 2009 to December 2009. Male bulb/C mice weighing 25-30 g were obtained from the Laboratory Animal Center of Shiraz University of Medical Sciences, (Shiraz, Iran). The animals were housed in standard cages, (four mice/cage), maintained in experimental conditions (12 h light/dark cycles, temperature 22±2 °C and free access to food and water. The experimental procedure was approved by the Ethical Committee of Shiraz University of Medical Sciences, Shiraz, Iran.

Extract preparation

Walnut (*Juglans regia*) in the family *Juglandaceae* was obtained from a local supplier in Shiraz, Iran, during September-October, and identified by specialized botanist. Septum of walnut shell (300g) was separated and shed dried (at 25 °C) ground and mixed with water by blender. After 24 h, the mixture was filtered through Wattman filter, evaporated by rotatory evaporator and dried in a desiccator. The extract was obtained with the percolation method. The final yield was 30 g powdered extract.

Diabetes induction

The animals were fasted for 24 h, with free access to water. Diabetes was induced by intraperitoneal injection of a single dose of Streptozotocin (STZ, Sigma, Aldrich, 220 mg/kg in 0.1 M citrate buffer, pH 4.4). Blood samples were taken from retro-orbital sinus before the start of the experiment and repeated each two week. The fasting blood glucose levels were estimated on days 1, 14, 28 and 42. Mice with blood glucose (fasting) level > 300 mg/dl for 2 weeks or longer and before day 28 after injection of STZ were considered diabetic and used for the study. The blood glucose (mg/dl) was measured by

'One Touch-ULTRA' glucometer (Johnson & Johnson Company, USA). Blood sampling in all animals were done by a micropipette from retro-orbital sinus under deep anesthesia.

Experimental groups

Animals were randomly divided into five groups:

Group I: diabetic mice served as diabetic-control and received the vehicle (0.2 ml normal saline/day/mouse) orally by gavage for 28 day (n=6)

Group II: diabetic mice were administered aqueous extract of SWS (200 mg/kg/day) in normal saline orally by gavage for 28 day (n=9)

Group III: diabetic mice were administered aqueous extract of SWS (400 mg/kg/day) in normal saline orally by gavage for 28 day (n=7)

Group IV: diabetic mice were administered aqueous extract of SWS (600 mg/kg/day) in normal saline orally by gavage for 28 day (n=9)

Group V: diabetic mice were administered aqueous extract of SWS (800 mg/kg/day) in normal saline orally by gavage for 28 day (n=10).

All the mice were fasted for 16 h before experimentation, but free access to water was allowed.

Tissue preparation

After 42 days, animals were sacrificed under deep anesthesia then perfused, first with saline solution (0.9% NaCl) until the organs had blanched, and then with 10% formalin, pH 7.4. After perfusion, the pancreases were removed, fixed in 10% formalin solution and processed by the paraffin technique. Sections of 5μ thickness were cut and stained by Haematoxylin and Eosin (H&E) for histological examination. Five normal mice selected and scarified for study of normal pancreas.

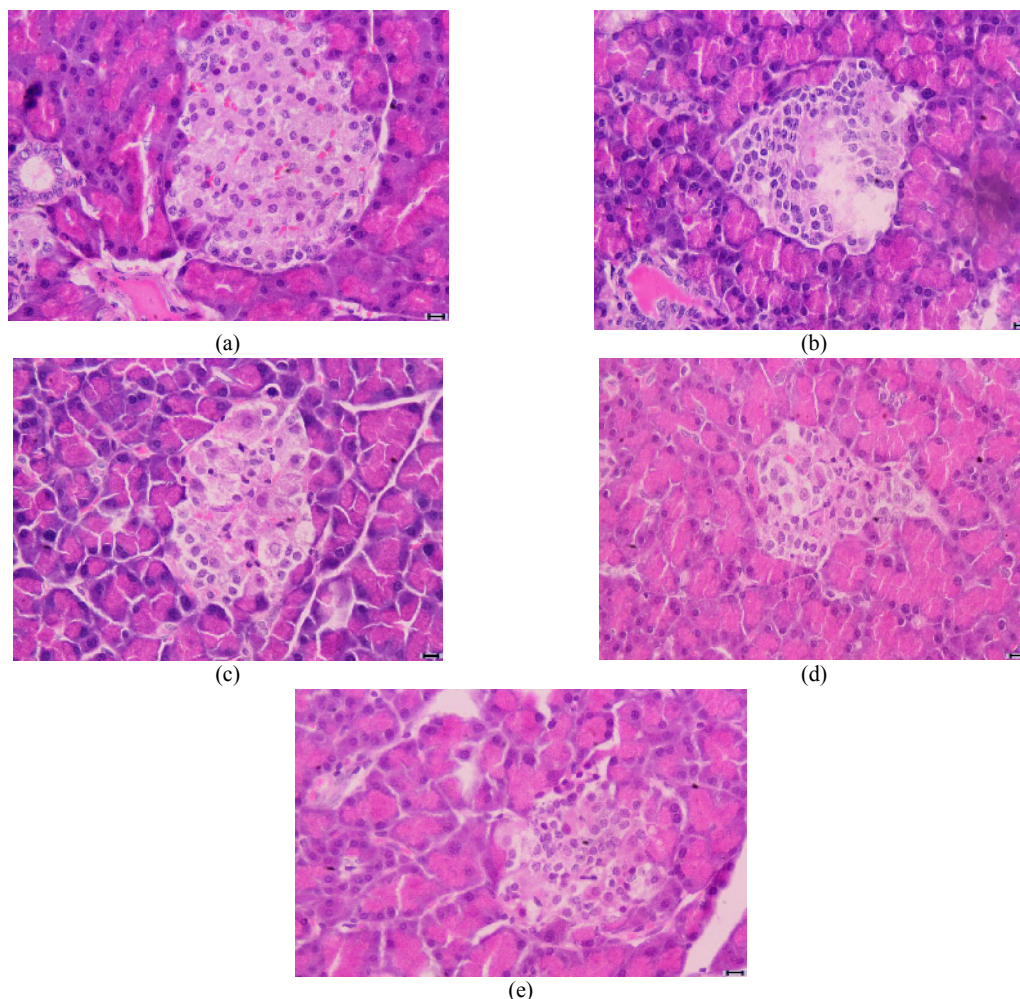


Fig 1. photomicrographs mouse pancreas stained by Hematoxylin-Eosin ($\times 400$):
 Normal mouse with no treatment.
 Diabetic mouse with no treatment.
 Diabetic mouse treated with 200mg/kg of aqueous extract of *walnut ridge*.
 Diabetic mouse treated with 400mg/kg of aqueous extract of *walnut ridge*.
 Diabetic mouse treated with 800mg/kg of aqueous extract of *walnut ridge*.

Statistical analysis

The results were analyzed using ANOVA and T-pair test. $p < 0.05$ was considered statistically significant.

RESULTS

Blood collection and Biochemical analysis

The present study reports the effect of aqueous extract of walnut septum on STZ-induced diabetic rats. According to data, blood glucose levels in all animals were normal at the start of experiment (at day 1). Administration STZ resulted in significant ($p \leq 0.05$) hyperglycemia in all the experimental groups after 14 days. As shown in Table 1, the aqueous extract in three different doses (200, 400 and 800 mg/kg) did not have any significant difference on blood glucose level, however, in each group, led to a significant reduction in

blood glucose level during four weeks. For example, in group 5, blood glucose decreased from 322 mg/dl in day 14 to 220 mg/dl in day 42 ($p \leq 0.05$). Although the walnut septum extract did not have dose-dependent effect but it showed time-dependent effect on blood glucose levels (Table 1).

Histopathological finding

Fig1 depicts the islet β -cells of the mice in different groups. Fig 1a shows normal islet with normal β -cells that were at the center of langerhans'islands. In untreated animals, the sections showed intense degenerative necrotic cells. Some β -cells had vacuolated cytoplasm with pyknotic nucleus (Fig 1b). Treatment of diabetic mice with the extract of walnut septum in groups 200 to 800 mg/kg did not cause any significant improvement in pancreatic architecture compared to untreated diabetic mouse (Fig 1c,d,e).

DISCUSSION

Regulation of blood glucose concentration plays an important role in diabetic patient. The degree of oxidative stress in diabetes makes them prone to oxidative injury [16]. Studies have shown that pancreatic damage occurs following STZ injection in animal model. STZ increased oxidative stress in diabetes through free radical generation [10,17]. So, it needs to explore methods for oxidative damage protection in this syndrome [2,18]. Hypoglycemic effects have been proved for some plants containing phenolic compounds [19,7]. Researches show that different parts of walnut tree such as leaf, root, seed and green husk have a significantly hypoglycemic effect [11-13]. The anti-oxidative of polyphenol-rich of walnut extract in diabetic animal has been investigated [20-21]. Walnut leaves have constituted a source of phenol component that inhibit production of free radicals, suggesting that it could be useful in the prevention of diabetes [21-22]. Walnut green husk have some phenolic compound such as flavonoid that reduce blood sugar in diabetes [12].

In this study, SWS did not have dose-dependent effect on blood glucose but had time-dependent effect on blood glucose level. Complex behavior of the plant extract may be originated from the competition between different compounds, so that dose-independent substances suppress dose-dependent effect [23]. In long term model, walnut leaf maintains the reduced blood glucose level permanently [24]. Therefore it seems usage of long term of septum extract may be reducing blood glucose.

In this research, SWS did not effect on the β -cells regeneration. Therefore, this mechanism might have been due to the increase of insulin from remnant β -cells [25-26] It might facilitate utilization of glucose by a insulin dependent glucose transporter [27]. It seems, continuous consumption of aqueous extract of SWS reduce blood sugar but cannot play a role on repairing beta-cells of langerhan's island. It may be useful for diabetic patients through reducing blood glucose. More studies should be conducted to reach firm conclusions.

ACKNOWLEDGMENTS

This study was supported by the vice-chancellor for Research of Shiraz University of Medical Sciences. The authors thank the Laboratory Animal House of the University. The research was done in Histomorphometry and Stereology Research Center, Shiraz University of Medical Sciences, Shiraz, Iran.

REFERENCES

- Dehwah MAS, Shuang Z, Huang QY. The Association between ACE gene I/D polymorphism and type 2 diabetes in Han Chinese in Hubei. *Int J Osteopor Metabol Disord* 2008; 1:1-7.
- Alhazza IM, Bashandy SAE. Hypoglycemic, hypolipidemic, antioxidant and male sexual improvement potentials of olive oil in alloxan treated rats. *J Pharmacol Toxicol* 2007; 2: 427-36.
- Kesavulu MM, Rao BK, Giri R, Vijaya J, Subramanyam G, Apparao C. Lipid peroxidation and antioxidant enzyme status in type 2 diabetic with coronary heart disease. *Diabetes Res Clin Pract* 2001; 53: 33-9.
- Srinivasan BT, Jarvis J, Khunti K, Davies MJ. Recent advances in the management of type 2 diabetes mellitus: a review. *Postgrad J Med* 2008; 84:524-31.
- Gaesser GA, Angadi SS, Sawyer BJ. Exercise and diet, independent of weight loss, improve cardiometabolic risk profile in overweight and obese individuals. *Phys Sports Med* 2011; 39:87-97.
- Soliman MM, Attia HF, El-Shazly SA, Saleh OM. Biomedical effects of cinnamon extract on obesity and diabetes relevance in Wistar Rats. *Am J Biochem Mol Biol* 2012; 2:133-45.
- Okpuzor J, Ogbunugafor H, Kareem GK, Igwo-Ezike MN. In vitro investigation of antioxidant phenolic compounds in extracts of Senna alata. *Res J Phytochem* 2009; 3:68-76.
- Mallick Ch, Maiti R, Ghosh D. Antidiabetogenic Effects of separate and composite extract of seed of Jamun (Eugenia jambolana) and root of Kadali (Musa paradisiaca) in streptozotocin-induced diabetic male Albino rat. A comparative study. *Int J Pharmacol* 2006; 2:492-503.
- Chigozie IJ, Chidinma IC. Hypoglycemic, hypocholesterolemic and ocular-protective effects of an aqueous extract of the Rhizomes of Sansevieria senegambica Baker (Agavaceae) on alloxan-induced diabetic Wistar rats. *Am J Biochem Mol Biol* 2012; 2:48-66.
- Mohana priya E, Gothandam KM, Karthikeyan S. Antidiabetic activity of Feronia limonia and Artocarpus heterophyllus in streptozotocin-induced diabetic rats. *Am J Food Technol* 2012; 7: 43-9.
- Jelodar GH, Maleki M, Shahram S. Effect of walnut leaf, coriander and pomegranate on blood glucose and histopathology of pancreas of alloxan-induced diabetic rats. *Afr J Trad CAM* 2007; 4:299-305.
- Shirdel Z, Madani H, Mirbadalzadeh R. Investigation into the hypoglycemic effect of hydroalcoholic extract of Ziziphus Jujuba Leaves on blood glucose and lipids in Alloxan-Induced diabetes in rats Iran. *J Diabet Lipid Disord*; 2009; 13-9.
- Tian Ying A, Li Hong H, Rong Min C, Zhong Liang C, Jia L, Qiang SH. Anti-diabetes Agents I: Tetralone derivative from Juglans regia. *Chin Chem Lett* 2003; 14:489-90.
- Mirheidar H. Knowledge of plants. THIRAN: Amir Kabir Press 1995; 317-9.
- Zargari A. Medical plants. Tehran: Tehran University Press 1990; 459-60.
- Navaei-Nigjeh M, Rahimifard M, Pourkhalili N, Nili-Ahmadabadi A, Pakzad M, Baeri M, Abdollahi M. Multi-organ protective effects of cerium oxide nanoparticle/selenium in diabetic rats: evidence for more efficiency of nanocerium in comparison to metal form of cerium. *Asian J Animal Vet Adv* 2012; 7:605-12.
- Jasmine R, Daisy P. Hypoglycemic and hypolipidemic activity of Eugenia jambolana in streptozotocin-diabetic rats. *Asian J Biochemi* 2007; 2:269-73.
- Oboh G, Nwanna EE, Elusiyana CA. Antioxidant and Antimicrobial Properties of Telfairia occidentalis (Fluted pumpkin) Leaf Extracts. *J Pharmacol Toxicol* 2006; 1:167-75.
- Hasani-Ranjbar S, Larjani B, Abdollahi M. A systematic review of Iranian medicinal plants useful in diabetes mellitus. *Arch Med Sci* 2008; 4:285-92.
- Pereira JA, Oliveira I, Sousa A, Ferreira IC, Bento A, Estevinho L. Bioactive properties and chemical composition of six walnut (Juglans regia L.) cultivars. *Food Chem Toxicol* 2008; 46:2103-11.
- Pereira JA, Oliveira I, Sousa A, Valentão P, Andrade PB, Ferreira IC, Ferreres F, Bento A, Seabra R, Estevinho L. Walnut (Juglans regia L.) leaves: phenolic compounds, antibacterial activity and antioxidant potential of different cultivars. *Food Chem Toxicol* 2007; 45:2287-95

22. Fukuda T, Ito H, Yoshida T. Effect of the walnut polyphenol fraction on oxidative stress in type 2 diabetes mice. *BioFactors* 2004; 21:251-3.
23. Fathiazad F, Garjani A, Motavallian naini A. Study of hypoglycemic activity of the hydroalcoholic extract of *Juglans regia* in normal and diabetic rats. *J Pharm Sci* 2006; 2:13-7.
24. Teimori M, Montasser Kouhsari S, Ghafarzadegan R, Hajiaghache R. Study of Hypoglycemic Effect of *Juglans regia* Leaves and its Mechanism. *J Med Plants* 2010; 9:57-65.
25. Esmacili MA, Yazdanparas R. Hypoglycemic effect of *Teucrium polium* studies with rat pancreatic islets. *J Ethnopharmacol* 2004; 95:27-30.
26. Sharma SB, Nasir A, Prabhu KM, Murthy PS. Antihyperglycemic effect of the fruit-pulp of *Eugenia jambolana* in experimental diabetes mellitus. *J Ethnopharmacol* 2006; 104:367-73.
27. Obatomi DK, Bikomo EO, Temple VJ. Antidiabetic properties of the African mistletoe in streptozotocin-induced diabetic rats. *J Ethnopharmacol* 1994; 43:13-7.

CURRENT AUTHOR ADDRESSES

Farzaneh Dehghani, Histomorphometry and Stereology Research Center, Shiraz Medical School, Shiraz University of Medical Sciences; Department of Anatomy, Shiraz Medical School, Shiraz University of Medical Sciences, Shiraz, Iran. Email: dehghanf@sums.ac.ir (Corresponding author)

Tahereh Mashhoodi, Department of Pharmacology, Shiraz Medical School, Shiraz University of Medical Sciences, Shiraz, Iran.

Mohammadreza Panjeshahin, Natural and Medicinal Chemistry Research Center, Department of Pharmacology, Shiraz Medical School, Shiraz University of Medical Sciences, Shiraz, Iran.