

Effect of Methotrexate on AgNOR Count in Liver of Wistar Rats

DEEPTHINATH RAGHUNATHAN, LAXMINARAYANA BAIRY KURADY and RAMACHANDRA BHAT

For author affiliations, see end of text.

Received May 9, 2008; Accepted November 5, 2008

This paper is available online at <http://ijpt.iums.ac.ir>

ABSTRACT

A study was undertaken to evaluate the Nucleolar organizing regions (NOR) count and histopathological changes in rat's liver treated with methotrexate (MTX). Male Wistar rats aged 4 months, maintained in our institution were used in the present study. Animals were injected intraperitoneally with 3 different doses of methotrexate on alternative days for one week and the animals were sacrificed on the seventh day by using ether. Paraffin slides were prepared and histopathology as well as AgNOR studies were done. In the histopathological study, liver showed disruption of normal hepatic plates, vaculation of the hepatocytes, nuclear variability and enlarged blood vessels. In AgNOR study, data showed an overall decrease in the total count (numerical) from normal to 12 mg dose MTX. The total count includes small, medium and large sized AgNORs. A statistically high significant difference was found from normal to 12 mg dose MTX as well as between the doses. In conclusion, the genotoxicity in rats is well documented with high dose of methotrexate (12 mg/kg) compared to low dose (8 mg/kg). Methotrexate treatment reduces the transcription rate and ploidy. Methotrexate reduces the cell proliferation. Thus it reduces the count.

Keywords: comma separated keywords

Nucleolar organizing regions (AgNORs) are loops of ribosomal DNA present in the nuclei of cells, which are involved in synthesizing rRNA [1]. They are commonly called as AgNORs because of their strong affinity for silver [2, 3]. AgNORs are concerned with proliferative activity of cells and are useful for studying the nuclear variations in normal and abnormal situations [4]. AgNOR is used as a predictor in non-Hodgkin's lymphoma [5]. Methotrexate (MTX) is an antiproliferative agent. It's an antimetabolite, antineoplastic agent that inhibit folate metabolism by its effects on dihydrofolate reductase. It directly inhibits thymidilate synthetase and several enzymes of de novo synthesis. MTX is an analogue of folic acid and acts as folic acid antagonist. Folic acid is a dietary factor for the production of tetrahydrofolate cofactor which in turn is required for cell division. MTX as folate antagonist, inhibits the dihydrofolate reductase and kills the cells during the 'S' phase of the cell cycle [6]. The main objective of the study was to determine whether the AgNOR count increases or decreases with different doses of MTX.

MATERIALS AND METHODS

Study design. The rats were divided in to four groups. Each group contains 6 animals. The animals

were injected intraperitoneally with three different doses (8 mg, 10 mg and 12 mg) of methotrexate in alternative days for one week and the animals were sacrificed on the seventh day by using ether.

Sample size. Male Wistar rats aged 4 months, maintained in our institution were used in the present study. Animals were maintained under controlled conditions of light, temperature and humidity in an air conditioned animal house. The average weights of the animal were 200gm.

Tissue processing

Perfusion. The animals were deeply anesthetized with ether and fixed in a dissection board and its chest cavity is opened to expose the heart. About 15 ml of 0.9 % saline was perfused through left ventricle at the rate of 1ml / minute. This is followed by perfusion of 10 % formalin about 250 ml for adult rats at the same flow rate. The organs were removed and kept in 10 % formalin for 48 hrs (post fixation). Paraffin blocks were made in an embedding bath. Sections of 3-5 microns thickness were cut from the blocks using rotary microtome. Sections were mounted on air dried gelatinized slides.

Haematoxyline and Eosin Staining

The tissues were de-paraffinized in xylene and transferred to water through descending grade of alcohol (absolute, 90 %, 70 %, 50 % alcohol). Sections were washed in tap water and stained with Erlich's Haematoxyline for 5 minutes and washed in tap water. Then stained with 1 % of eosin for 30 seconds and dehydrated with ascending grades of alcohol, cleared in xylene and mounted in Canada Balsam and observed under microscope for assessing the histological state of the tissue.

AgNOR STUDY

Preparation of AgNO₃ solution

To prepare 50% of silver nitrate solution 5 gm of silver nitrate powder was dissolved in 10 ml of distilled water and filtered through Whatman filter paper 1 in dark. The solution was stored in dark at 4^o C, and used within one week.

Preparation of Gelatin

1 gm of powdered gelatin was dissolved in 49 ml of distilled water and 1 ml of formic acid. To dissolve faster, mixture was kept in hot water bath at 60^o C for at least 10 minutes. The solution was stored in dark at 4^oC and used within one week.

Silver Nitrate staining

A rapid staining and de-staining method developed in our lab [7] was used through out the study.

- 4 drops of silver nitrate solution and 2 drops of gelatin solution were added on to the slide.
- Solutions were gently mixed and spread over the slide.
- Slides were gently warmed and passed to and fro few inches over the flame of Bunsen burner for 15-20 seconds (till the slides turned to golden yellow).
- During the staining process precautions were taken to avoid over heating of the slides.
- Slides were then rinsed in distilled water and air dried.

De-staining method

Over stained slides were flooded with either 50% Hydrogen peroxide for one second or 25% Hydrogen peroxide for 15 seconds. The process could be monitored under the microscope, and did not alter cellular architecture, composition and even staining ability. The dissolved silver was washed from the sections under running water.

Inclusion and exclusion criteria

Standard protocols were followed for recording number and quantitation of size and shape of dots [8].

AgNOR count

Areas with minimal cell overlap and no artifact were demarcated for counting. Weak or dark stained slides were not evaluated. The s appeared as black dots within the orange colored nuclear background. Dots were defined as discrete homogenous silver precipitates with well defined edges. Overlapped dots with well defined

edges were counted as greater than one when these appeared on viewing through different focal planes. Dots lying in a group with indistinguishable boundaries were treated as one dot. Dots outside the nucleolus were not considered. Observations were completed within a week of staining due to fading of stain on prolonged storage. Counting was performed, using oil immersion at 400X.

Size

Size were classified in to three groups on the basis of their diameter (Small \leq 1 μ m, Medium $>$ 1 and \leq 3 μ m and Large $>$ 3 μ m).

Shape

On the basis of the shape, s was classified in to regular (with round or oval well-defined margin) and irregular (with irregular serrated margin) dots. In each category size (maximum diameter) of all dots were documented.

Tools used

Tools were measured using ocular micrometer (calibrated with stage micrometer).

Statistical methods used

Data on mean count; size wise distribution of dots was tested using one way ANOVA. Since the test of homogeneity of variance showed high significance between different groups, data were reanalyzed using square root transformation. For each dose and distribution, mean count, standard deviation, f-ratio and p-value were computed.

RESULTS

The histopathological study of methotrexate as well as the dose wise expression of s in liver was considered in the present study. Data were collected and analyzed. Liver showed disruption of normal hepatic plates, vacuolation of the hepatocytes, nuclear variability and enlarged blood vessels.

Data showed an overall decrease in the total AgNOR count (numerical) from normal to 12 mg dose MTX. The total count includes small, medium and large sized AgNORs. A statistically high significant difference was found from AgNORmal to 12 mg dose MTX as well as between the doses.

Large sized AgNORs (> 3 μ m) (Figs 1 and 5)- Data showed an overall numerical decrease in the large sized AgNORs from control to 12 mg dose MTX. A statistically significant difference was found between control and the different doses. But there was no statistical difference between 8 mg dose vs 10 and 12 mg doses of MTX as well as between 10 and 12 mg doses of MTX.

Medium sized AgNORs (> 1-3 μ m) (Figs 1 and 5)- Medium sized AgORs showed a statistically high difference between control and 12 mg dose MTX. However there was a numerical decrease between control and 10 mg dose MTX and an increase thereafter.

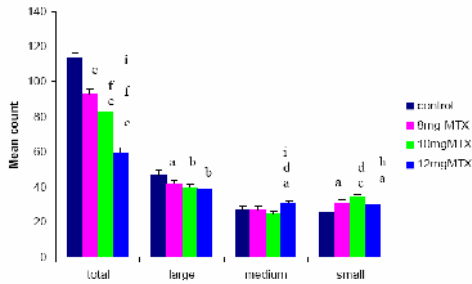


Fig 1. Size wise distribution of AgNORs in liver- Total count and size wise distribution of s in control and drug treated groups. Each value represents mean of + S.D from 6 animals/group. Significant values are represented as, control vs 8 mg, 10 mg and 12 mg - <0.05= a, <0.01= b and, <0.001=c. Between 8 mg vs 10 mg and 12 mg - <0.05= d and <0.001= f. Between 10 mg and 12 mg- <0.01= h and <0.001= i. (One way ANOVA and Banferroni post test)

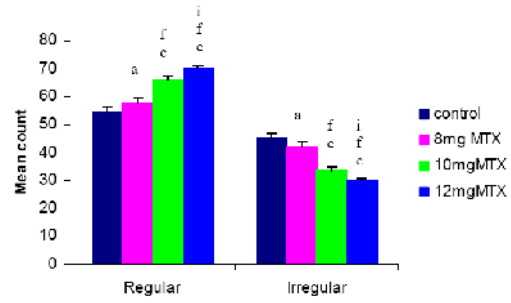


Fig 2. Shape wise distribution of AgNORs in liver- Shape wise distribution of s in control and drug treated groups. Each value represents mean of + S.D from 6 animals/group. Significant values are represented as, control vs 8 mg, 10 mg and 12 mg - <0.05= a and <0.001=c. Between 8 mg vs 10 mg and 12 mg - <0.001= f. Between 10 mg and 12 mg- <0.001= i.

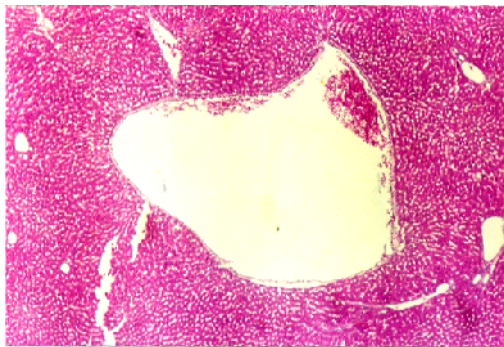


Fig 3. Photograph showing Liver of 12 mg MTX treated rat. H & E stain (20 x).

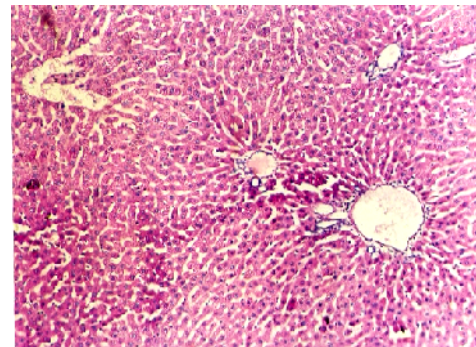


Fig 4 Photograph showing liver of control rat. H & E stain (40 x).

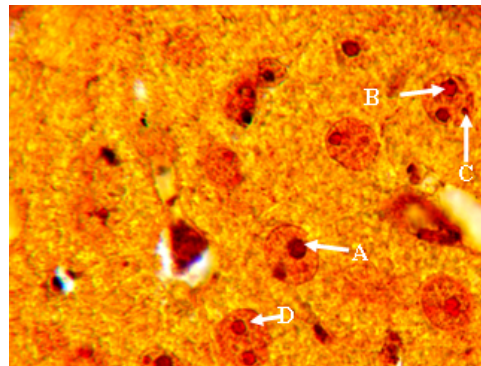


Fig 5. A– Regular shaped B– Large sized C– Small sized D– Medium sized AgNOR

Small sized AgNORs (< 1 μm) (Figs 1 and 5)

Small sized AgNORs showed a numerical increase from control to 10 mg dose MTX and there after a decrease between 10 and 12 mg doses of MTX. The data showed a highly statistically significant difference from control to 10 mg dose and between the doses.

Regular shaped AgNORs (Figs 2 and 6)

Data showed a numerical increase in the values from control to 12 mg dose MTX. And it showed a highly statistically significant difference from control to 12 mg dose as well as between the doses.

Irregular shaped AgNORs (Figs 2 and 6)

The data showed a numerical decrease from control to higher doses and a highly statistically significant difference from the control to the higher doses as well as between the doses.

DISCUSSION

Methotrexate (MTX) is an antimetabolite widely used in cancer chemotherapy, which can cause intestinal mucosal injury. The antimitotic effect of MTX is known to give rise to malabsorption syndrome. It inhibits the enzyme dihydrofolate reductase (DHFR) which is required for DNA synthesis and cell division [9].

In the present study liver showed disruption of normal hepatic plates, vaculation of the hepatocytes, nuclear variability and enlarged blood vessels (Fig 3). MTX is a novel xenobiotic inducer of rat liver and intestinal sulfotransferase. Intestinal inductions were found to be much greater than those found in liver. MTX is the first antifolate apoptosis-inducing drug to show induction of intestinal sulfotransferase [10]. Methotrexate therapy is associated with liver damage, both acute (notably after high dose) and more seriously in chronic cases (generally after long term administration) [11-13]. Hepatic fibrosis and cirrhosis may develop without signs of hepatotoxicity and have led to eventual death. Reversible evaluation of hepatic enzymes may occur in some patients [14]. Administration of methotrexate increased mortality in patients with primary biliary cirrhosis [15].

Argyrophilic nucleolar organizer regions were widely used in clinics, more than 500 papers on relevant field have been published in China, including the application in different kinds of malignant tumors, such as stomach cancer, lung cancer, liver cancer, colon cancer, and breast cancer. In differential diagnosis of malignant lymphoma and benign lymph node diseases, is more valuable [16].

Studies suggest potential usefulness of AgNOR parameters, such as mean count and area of distribution within the nucleus, in diagnosis and prognosis of various neoplasms [17-23], especially oral squamous cell carcinoma [18, 21, 24, 25]. Mean AgNOR counts can be useful in diagnosing histological features representing oral leukoplakia (18) and have been shown to correlate with clinical outcomes of various cancers [24, 26, 27, 28]. Chia et al analysed the AgNOR pattern in urinary cytology in samples from 70 patients and concluded that a combined qualitative and quantitative AgNOR analysis can be useful in the differential diagnosis of urinary cytology (19). Jay et al emphasized that since mean AgNOR count of a lesion is an easily reproducible measure, it would serve as a more objective criterion than hematoxylin and eosin (H&E) stain-based assessment for diagnosing epithelial dysplasia [29]. Further, AgNORs are sound replicatory markers and H&E criteria are subjective, it is conceivable that the H&E-based 'gold standard' misclassifies some of these lesions.

In conclusion, the genotoxicity in rats is well documented with high dose of methotrexate (12 mg/kg) compared to low dose (8 mg/kg). Methotrexate treatment reduces the transcription rate and ploidy. It also reduces the cell proliferation. Thus it reduces the AgNOR count. Higher the dose lesser the AgNOR count and the irregularity of AgNORs.

REFERENCES

1. Fawcett DW. A text book of histology. 12th ed, Chapman and Hall, New York: 1994; pp1-56.
2. Ploton D, Menager M, Jeannesson P, Himber G, Pigeon F, Adnet JJ. Improvement in the staining and in the visualization of the argyrophilic proteins of the nucleolar organizer region at the optical level. *Histochem J* 1986; 18:5-14.
3. Fakan S, Hernandez-Verdun D. The nucleolus and the nucleolar organizer regions. *Biol Cell* 1986; 56:189-205.
4. Howell W M. Selective staining of nucleolar organizing regions (NORs). In: The cell nucleus, Vol. XI (ed. Busch H, Rothblum L), Academic press, New York, 1982; pp 89-142.
5. Vail DM, Kisseberth WC, Obradovich JE, Moore FM, London CA, MacEwen EG, Ritter MA. Assessment of potential doubling time (Tpot), argyrophilic nucleolar organizer regions (AgNOR), and proliferating cell nuclear antigen (PCNA) as predictors of therapy response in canine non-Hodgkin's lymphoma. *Exp Hematol* 1996; 24:807-15.
6. Borchers AT, Keen CL, Cheema GS, Gershwin ME. The use of methotrexate in rheumatoid arthritis. *Semin Arthritis Rheum* 2004; 34:465-83.
7. Dhar PK, Kumar MR, Nayak S, Rao TR, Joseph A, Devi S, Kumari U, Bhat SM, Bhat KR. A rapid silver staining and destaining technique for the nucleolar organizer region. *Biotech Histochem* 1995; 70:302-3.
8. Crocker J, Boldy DA, Egan MJ. How should we count AgNORS? Proposals for a standardized approach. *J Pathol* 1989; 158:185-8.
9. Jolivet J, Cowan KH, Curt GA, Clendeninn NJ, Chabner BA. The pharmacology and clinical use of methotrexate. *N Engl J Med* 1983; 309:1094-104.
10. Maiti S, Chen G. Methotrexate is a novel inducer of rat liver and intestinal sulfotransferases. *Arch Biochem Biophys* 2003; 418:161-8.
11. Zachariae H. Methotrexate induced liver cirrhosis. *Br J Dermatol* 1980; 102: 407-12.
12. Klaber MR. Prospective study of liver biopsies in patients with psoriasis receiving methotrexate therapy. *Br J Dermatol* 1982; 107 (suppl.22): 28.
13. Kevat S. Hepatotoxicity of methotrexate in rheumatic diseases. *Med Toxicol* 1988; 3: 197-208.
14. Doroshov JH, Locker GY, Gaasterland DE, Hubbard SP, Young RC, Myers CE. Ocular irritation from high-dose methotrexate therapy. *Cancer* 1981; 48:2158-62.
15. Gong Y, Gluud C. Methotrexate for primary biliary cirrhosis. *Cochrane Database Syst Rev* 2005; 20:CD004385.
16. Xu LZ. Retrospect and prospect of clinical oncocytological research. *AiZheng* 2004; 23:1717-20.
17. Chattopadhyay A. AgNORs in tumoral pathology. Review literature observations technique reaction normal oral epithelium. *Indian J Dent Res* 1993; 4: 47-53.
18. Chattopadhyay A, Chawda JG, Doshi JJ. Silver-binding nucleolar organizer regions: a study of oral leukoplakia and squamous cell carcinoma. *Int J Oral Maxillofac Surg* 1994; 23: 374-7.
19. Cia EMM, Trevisan M, Metze K. Argyrophilic nucleolar organizer regions (AgNOR) technique: a helpful tool for differential diagnosis in urinary cytology. *Cytopathology* 1999; 10: 30-9.
20. Ielmini MV, Heber E, Schwint AE, Cabrini RL, Itoiz ME. AgNORs are sensitive markers of radiation lesions in squamous epithelia. *J Dent Res* 2000; 79: 850-6.
21. Schwint AE, Folco A, Morales A, Cabrini RL, Itoiz ME. AgNOR mark epithelial foci in malignant transformation in hamster cheek pouch carcinogenesis. *J Oral Pathol Med* 1996; 25: 20-4.
22. Crocker J, Skilbeck N. Nucleolar organizer region associated proteins in cutaneous melanotic lesions: a quantitative study. *J Clin Pathol* 1987; 40: 885-9.
23. Jan- Mohammed RM, Armstrong SJ, Crocker J. The relationship between number of interphase NORs and NOR bearing chromosomes in non-Hodgkin's lymphoma. *J Pathol* 1989; 158: 3-7.
24. Piffkò J, Bánkfalvi A, Ofner D, Bryne M, Rasch D, Joos U, Böcker W, Schmid KW. Prognostic value of histological factors (malignancy grading and AgNOR content) assessed at the

- invasive tumor front of oral squamous cell carcinoma. *Br J Cancer* 1997; 75: 1543–6.
25. Piffkò J, Bánkfalvi A, Ofner D, Bryne M, Rasch D, Joos U, Böcker W, Schmid KW. Standardized demonstration of silver-stained nucleolar organizer regions-associated proteins in archival oral squamous cell carcinomas and adjacent non-neoplastic mucosa. *Mod Pathol* 1997; 1098–104.
 26. Giuffrè G, Fulcheri E, Gualco M, Fedele F, Tuccari G. Standardized AgNOR analysis as a prognostic parameter in endometrial carcinoma, endometrioid type. *Anal Quant Cytol Histol* 2001; 23: 31–40.
 27. Tuccari G, Abbona GC, Giuffrè G, Papotti M, Gasparri G, Barresi G, et al. AgNOR quantity as a prognostic tool in hyperplastic and neoplastic parathyroid glands. *Virchows Archiv* 2000; 437: 298–303.
 28. Xie X, Norgard S, Halvorsen TB, Franzen G, Boysen M. Prognostic significance of nucleolar organizer regions in adenoid cystic carcinomas of the head and neck. *Acta Otolaryngol Head Neck Surg* 1997; 123: 615–20.
 29. Ray GJ, Chattopadhyaya A, Caplan JD. Usefulness of AgNOR counts in diagnosing epithelial dysplasia. *J Oral Pathol Med* 2003; 32:71-6.

CURRENT AUTHOR ADDRESSES

Deepthinath Raghunathan, Assistant Professor of Anatomy, Melaka Manipal Medical College (Manipal Campus) Karnataka, INDIA.

Laxminarayana bairy kurady, Professor of Pharmacology Kasturba Medical College Manipal, Karnataka, INDIA.

Ramachandra Bhat, Professor of Anatomy, Kasturba Medical College Manipal, Karnataka, INDIA.