

Wound Healing and Antioxidant Activities of *Morinda citrifolia* Leaf Extract in Rats

VIJAYKUMAR PANDURANG RASAL, ARULMOZHI SINNATHAMBI, PURNIMA ASHOK and SRIDHAR YESHMAINA

For author affiliations, see end of text.

Received August 10, 2007; Revised June 27, 2008; Accepted October 5, 2008

This paper is available online at <http://ijpt.iuims.ac.ir>

ABSTRACT

Morinda citrifolia (Noni) has been traditionally used for bone and wound healing. The present study was carried out to investigate the effect of *Morinda citrifolia* leaves on experimental wounds and lipid peroxide levels in rats. Effect of aqueous extract of leaves of *Morinda citrifolia* (200 mg/kg) on excision, resutured incision and dead space wound models were studied. Changes in blood malondialdehyde (MDA) levels and histopathological studies were also carried out. There was a significant increase ($p < 0.0001$) in wound contraction rate, tensile strength, granuloma breaking strength, collagen content, dry granuloma weight ($p < 0.01$) and hydroxyproline content. A significant decrease ($p < 0.0001$) in epithelialisation period and MDA levels in *Morinda citrifolia* leaf extract treated group were observed when compared to control group. From the results, it may be concluded that the *M. citrifolia* aqueous leaves enhances the wound healing and possess antioxidant activity.

Keywords: *Morinda citrifolia*, Wound healing, Antioxidant, Lipid peroxidation

Herbal and natural products of folk medicine have been used for centuries in every culture throughout the world. The ancients observed that some ingredients used in food had the specific properties of relieving or eliminating certain diseases and maintaining good health. Among the medicinal plants discovered by the Indian ancestors, *Morinda citrifolia* (Rubiaceae) commonly known as Noni is a small tree native to South Eastern Asia [1]. It is also called as Indian Mulberry, Ba Ji Tian, Nono or Nonu, Cheese fruit, and Nhau in various cultures throughout the world. The components isolated from Noni include scopoletin, octoanoic acid, potassium, vitamin C, terpenoides, alkaloids, anthroquinones, sitosterol, β -carotene, vitamin A, flavone glycosides and linoic acid [2]. The leaf contains flavanol glycosides, beta-carotene and iridoid glycosides [3,4]. It is also reported to have a broad range of nutritional and therapeutic values for cancer, infection, arthritis, diabetes, asthma, hypertension and pain. It also has smooth muscle stimulatory activity and histaminergic effects along with antibacterial, antiviral, anti-tubercular, antitumor, anthelmintic, analgesic, hypotensive and immunological activities [2]. Noni was a traditional remedy used to treat broken bones, deep cuts, bruises, sores and wounds [5]. The fresh leaf is used for the treatment of wounds and also as a poultice for broken bones and sprains [6]

in most parts of India. However the detailed information regarding the wound healing activity of *M. citrifolia* is not scientifically documented. In the present investigation an attempt was made to assess the effect of *Morinda citrifolia* leaf extract on wound healing and lipid peroxide levels in rats.

MATERIALS AND METHODS

Plant material

The leaves of *Morinda citrifolia* were collected from the damp fields around Belgaum and authenticated by Botanical Survey of India, Pune and a voucher specimen has been deposited at BSI, Pune, India (AS-3).

Animals

Healthy Albino Wistar rats (150-200 g) of either sex obtained from Central animal house, Jawaharlal Nehru Medical College, Belgaum were used for the study. They were housed individually under standard laboratory conditions and fed with pellet rodent diet and water *ad libitum*. CPCSEA guidelines were adhered to during the maintenance and experiment. The study was approved by Institutional Animal Ethics Committee (IAEC), K.L.E.S's College of Pharmacy, Belgaum.

Table 1. Effect of *Morinda citrifolia* on excision wounds and MDA levels.

Parameter	Control	<i>M. citrifolia</i> treated
% of wound contraction		
Day 4	18.26 ± 0.96	30.24 ± 0.72***
Day 8	72.38 ± 0.58	82.36 ± 0.42***
Day 12	78.36 ± 0.40	92.36 ± 0.62***
Day 16	88.26 ± 0.14	96.78 ± 0.20***
Day 20	90.72 ± 0.38	99.8 ± 0.008***
Epithelialisation period (days)	24.66 ± 0.84	18.16 ± 0.30***
Scar area (Sq.mm)	33.34 ± 2.12	24.34 ± 1.20**
MDA level (Day 21) (nmol/100ml blood)	171.82 ± 5.48	134.6 ± 3.34**

values are represented as mean ± SEM (n = 6)

Student's 't' test

p*<0.001, *p*<0.0001 when compared to control.

Preparation of the extract

The fresh leaves were ground to paste and macerated for 7 days using distilled water. The aqueous extract was filtered with Whatmann No.2 filter paper, filtrate was collected and evaporated under reduced pressure using vacuum evaporator. The concentrated material obtained was reduced to thick mass at room temperature and water was removed by placing it in dessicator. The extract was dissolved in water and used for the studies.

Acute toxicity studies

Acute toxicity studies of *M. citrifolia* extract did not show any marked toxicity up to 2000 mg/kg body weight [7] and 1/10th of the oral dose (200 mg/kg) of leaf extract was used for the study.

Experimental protocol

Animals were divided into two groups (control and test) of six animals each. The test group received *Morinda citrifolia* leaf extract (200 mg/kg body weight) daily for 10 consecutive days in incision, dead space wound models and for 21 days in the excision wound model. The control group was administered with normal saline.

Wound Models

Excision wounds

Animals were anaesthetized with anaesthetic ether and placed in operation table in its natural position. An impression was made on the dorsal thoracic central region 5 mm away from the ears by using a round seal of 2.5 cm diameter. The skin of the impressed area was

excised to full thickness to obtain a wound area of about 500 sq mm. The wounds were traced on graph paper on the day of wounding and subsequently on day 4, 8, 12, 16, and 20. Scar residue, area and time for complete epithelialisation were also measured. The percentage of wound closure and period of epithelialisation were recorded [8]. The blood was collected on day 21 by retro-orbital puncture and plasma lipid peroxide levels were estimated by using thiobarbituric acid [9].

Incision wounds

Two paravertebral straight incisions of 6 cm were made through the entire thickness of the skin on either side of the vertebral column of rats under light ether anesthesia [10]. The wounds were closed with interrupted sutures, which were removed on day 8 of the wounding. Wound breaking strength was measured on day 10 [11]. Simultaneously, blood was withdrawn on day 10 and plasma lipid peroxide levels were estimated [9].

Dead space wounds

Granuloma formation was induced by subcutaneous implantation of sterile cotton pellets [12] and sterilized grass piths (25 × 3 mm) in the groin. On day 10, the granuloma were excised and tested for tensile strength [11]. The hydroxyproline content of the granulation tissue was estimated. The granuloma excised were stained using H & E stain and observed under light microscope (100 X) for the histopathological changes [13]. The cotton pellet granuloma excised from dead space wounds were dried overnight at 60°C and the dry weight was expressed as mg/100 g of body weight [14].

Table 2. Effect of *Morinda citrifolia* on incision, dead space wounds and MDA levels

Wound Model	INCISION WOUNDS			DEAD SPACE WOUNDS	
	Tensile Strength (g)	MDA levels (nmol/100ml)	Breaking strength (g)	GRANULOMA WEIGHT (G/ 100 G B.W.)	HYDROXYPROLINE CONTENT (G)
Groups					
CONTROL	254.12 ± 1.80	186.54 ± 2.84	207.92 ± 6.024	35.0 ± 1.74	6.2 ± 0.12
MORINDA CITRIFOLIA TREATED	395.66 ± 2.58***	138.4 ± 5.24***	270.4 ± 3.46***	47.16 ± 2.6*	8.4 ± 0.68*

Values are represented as mean ± SEM (n = 6)

Student's 't' test

p*<0.01, **p*<0.0001 compared to control.

Table 3. Effect of *Morinda citrifolia* leaf extract on collagen content of the granuloma tissue.

DAY	Collagen in mg/g	
	CONTROL	<i>M. citrifolia</i> treated
4	11.56 ± 0.32	18.28 ± 0.22***
8	22.62±0.84	32.55±0.70***
12	31.91±0.64	38.42±0.42***
16	34.23±0.38	41.77±0.66***
20	38.36±0.42	44.15±0.64***

Values are represented as Mean ± SEM

Student's 't' test ***- $p < 0.001$.

Estimation of collagen in the regenerated tissues

The animals were divided into two groups of six animals each. Excision wound and treatment to all the animals were made in the same manner as mentioned in excision wounds [8]. The regenerated tissues were extracted from the wounds of each group on day 4, 8, 12, 16 and 20 and estimated for collagen content [15].

Estimation of Malondialdehyde (MDA) in blood [9]

Plasma (0.75ml) was mixed with 3ml of reagent [75mg Thiobarbituric acid (TBA), 15 gm Trichloro acetic acid (T.C.A) and 2.08 ml 0.2N HCl in 100 ml water] and kept in boiling water bath for 15 min, cooled, centrifuged for 10 min at 10,000 rpm. Absorbance of the supernatant is read against the blank at 535nm.

MDA nanomoles/100 ml of blood

= Absorbance of test × Total volume (3.75 ml)

Nanomolar extinction × sample volume

Coefficient (1.56×10^5) (0.75ml)

= Absorbance of test × 3205.

Statistical analysis

Results were expressed as mean ± SEM and evaluated for statistical significance by unpaired Student's t-test. Value of $p < 0.05$ were considered statistically significant.

RESULTS

Wound healing studies

The extract facilitated the wound contraction rate (Table 1). The scar residue left behind after the treatment with extract was superficial when compared to the scar residue left behind by the control, which were deep and unsightly.

In the incision wound model, the wound breaking

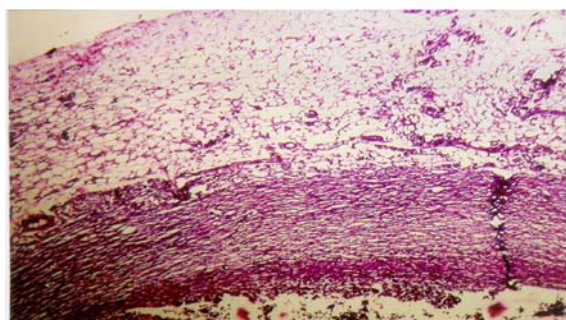


Fig 1. Histopathology of control. H & E stain, 100 X

strength was significantly ($p < 0.001$) increased on day 10 in *M. citrifolia* treated group when compared to control (Table 1). Tensile strength of the granuloma tissue, weight of the tissue and hydroxyproline content were also significantly ($p < 0.0001$, $p < 0.01$ respectively) increased in leaf extract treated group when compared to control group in dead space wounds (Table 2).

Histochemical studies

The extract significantly increased ($p < 0.001$) the collagen in the test wounds on day 4, 8, 12, and 16 when compared to control. The rise in collagen content in regenerated tissue was maximum on day 8 (Table 3).

Malondialdehyde (MDA)

Extract showed significant ($p < 0.001$) decrease in mean blood MDA levels when compared to control group (Table 1 and 2) in incision and excision wound models.

Histopathological studies

Histopathological studies showed significant neovascularisation, epithelialisation and fibroblast in *M. citrifolia* treated group (Fig 2) compared to the control (Fig 1).

DISCUSSION

Wounds are common clinical entities in day-to-day life, which may be major or minor. The process of wound healing can be classified into five phases- cellular phase (granulation), narrowing of wound area (wound contraction), collagen deposition (collagenation), epithelial covering (Epithelialisation) and scar remodeling (cicatrisation). These phases are concurrent but independent of each other. Any agent which accelerates the process is a promoter of wound healing [16].

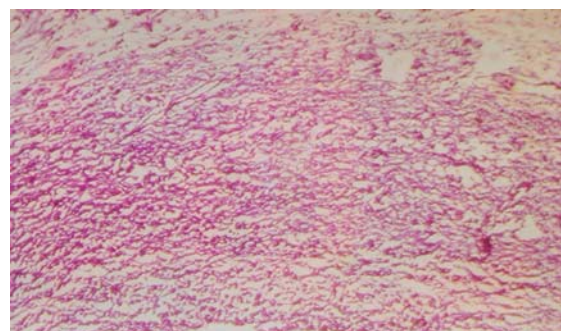


Fig 2. Histopathology of *M. citrifolia* showing increased epithelialisation. H & E stain, 100 X

The findings of the present study showed a significant increase in wound contraction rate, skin breaking strength reflecting increased collagen levels. The increase in dry granuloma weight and granuloma breaking strength indicates better maturation of collagen by increased cross-linking. This is confirmed by the increase in collagen content in granuloma excised from the wound. Collagen contains large molecules of glycine, proline, hydroxyproline [16]. Treatment with *Morinda citrifolia* increased the hydroxyproline content which further confirms the involvement of collagen in the present study. The treated wound epithelialised faster and the rate of wound contraction was higher as compared to control. The scar residue in the extract treated group was superficial. Histopathological studies revealed a significant increase in epithelialisation in *Morinda citrifolia* treated group. All these evidences confirm that *Morinda citrifolia* enhances the wound healing by acting on various phases of the wound healing process.

Elimination of reactive oxygen species is reported to be an important strategy to improve healing of wounds. Several antioxidants such as ascorbic acid, catalase were found to improve healing. Ascorbic acid has a role in both the formation and maintenance of collagen in healing wounds. Catalase was found to detoxify hydrogen peroxide which can otherwise inflict severe damage to regenerating cells. A combination of antioxidants comprising vitamin E, sodium pyruvate and fatty acids have been employed for enhancing healing in normal and immunocompromised wounds [17]. In the present study, decrease in lipid peroxide level was observed in the *M. citrifolia* treated group which may be because of the presence of β - carotene, flavonol glycosides and iridoid glycosides which have antioxidant activity [3,4]. Preliminary qualitative chemical tests also confirmed the presence of flavanoids in the extract.

In condensation, the results indicated the beneficial effects of *M. citrifolia* by reduced lipid peroxide levels in treated wounds, which may in turn be responsible for acceleration of the healing process.

ACKNOWLEDGEMENT

We are thankful to Dr. F. V. Manvi, Principal, K.L.E.S's College of Pharmacy, Belgaum for providing the necessary facilities to carry out the research work.

REFERENCES

1. Thomas Fleming. PDR of Herbal medicines, 2nd edn. Montvale, New Jersey: Medical economics company; 2000.
2. Wang Mian-Ying, Brett J West, Jarakae Jensen C, Diane Nowicki, Su Chen, Afa K. Paul, Gary Anderson. *Morinda citri-*

folia (Noni): A literature review and recent advances in Noni research. *Acta Pharmacol. Sin.* 2002; 23(12): 1127-1141.

3. Sang S, Cheng X, Zhu N, Wang M, Jhoo JW, Stark RE, Badmaev V, Ghai G, Rosen RT, Ho CT. Iridoid glycosides from the leaves of *Morinda citrifolia*. *J. Nat. Prod.* 2001; 64(6): 799-800.
4. Sang S, Cheng X, Zhu N, Stark RE, Badmaev V, Ghai G. Flavonolglycosides and novel iridoid glycoside from the leaves of *Morinda citrifolia*. *J. Agri. Food Chem.*, 2001; 49(9): 4478-4481.
5. Singh Y, Ikahihifo T, Pnuve M, Slatter C. Folk medicine in Tonga: A study on the use of herbal medicines for obstetric and gynecological conditions and disorders. *J. Ethnopharm.* 1984; 12: 305 – 25.
6. Ivan A Ross. Medicinal plants of the world, Vol. 2. Totowa, New Jersey: Humana press inc.; 2001.
7. "Guidance document on acute oral toxicity testing" Series on testing and assessment No. 24, 2001 Organisation for economic co-operation and development, OECD Environment, health and safety publications, Paris (www.oecd.org/ehs).
8. Morton JJP, Malone HH. Evaluation of vulnerary activity by an open wound procedure in rats. *Arch.Int. pharmacodyn. Ther.* 1972; 196: 117-126.
9. el Hafidi M, Banos G. In vivo plasma lipid oxidation in sugar-induced rat hypertriglyceridemia and hypertension. *Hypertension* 1997; 30(3 Pt 2): 624 – 628 .
10. Ehrlich HP, Hunt TK. Effect of cortisone and anabolic steroids on the tensile strength of healing of wounds. *Ann.Surg.* 1969; 170(2): 203.
11. Lee KH. Studies on mechanism of action of salicylates II. Retardation of wound healing by aspirin. *J. Pharm. Sci.* 1969; 57:1042-1043.
12. Turner RA. Screening methods in pharmacology, 2nd ed. New York: Academic Press; 1965.
13. Drury RAB, Wallington EA. Carleton's histological techniques, 5th ed. London : Oxford University Press; 1980.
14. Dispasquale G, Meli A. Effect of body weight changes on the formation of cotton pellet induced granuloma. *J. Pharm. Pharmacol.* 1965; 17: 379.
15. Udupa KN. Advances in research in Indian medicine, Varanasi: Banaras Hindu University; 1970.
16. Smith R. Recovery and Tissue Repair. *British Medical Bulletin* 1985; 41(3): 295-301.
17. Soneja A, Drews M, Malinski T. Role of nitric oxide, nitroxidative and oxidative stress in wound healing. *Pharmacol. Rep.* 2005; 57 (Suppl): 108 – 119.

CURRENT AUTHOR ADDRESSES

Vijaykumar Pandurang Rasal, Department of Pharmacology, K.L.E.S's College of Pharmacy, J.N. Medical College Campus, Belgaum – 590 010. E.mail: pharमारुl@gmail.com (Corresponding author)

Arulmozhi Sinnathambi, 2Department of Pharmacology, Allana College of pharmacy, Azam Campus, Camp, Pune – 411 001.

Purnima Ashok, Department of Pharmacology, K.L.E.S's College of Pharmacy, II Block, Rajaji Nagar, Bangalore – 560 010.

Sridhar Yeshmaina, Department of Pharmacology, K.L.E.S's College of Pharmacy, J.N. Medical College Campus, Belgaum – 590 010.