



## Protection of alloxan monohydrate-induced testicular toxicity by *Gundelia tournefortii* aerial parts aqueous extract in male mice

Samaneh Goorani<sup>1</sup>, Mohammad Kazem Koochi<sup>1</sup>, Niloofar Seydi<sup>2</sup>, Akram Zangeneh<sup>2,3\*</sup>,  
Mohammad Mahdi Zangeneh<sup>2,3</sup>

<sup>1</sup> Department of Toxicology, Faculty of Veterinary Medicine, University of Tehran, Tehran, Iran

<sup>2</sup> Department of Clinical Science, Faculty of Veterinary Medicine, Razi University, Kermanshah, Iran

<sup>3</sup> Biotechnology and Medicinal Plants Research Center, Ilam University of Medical Sciences, Ilam, Iran

### Please cite this article as:

Goorani S, Koochi MK, Seydi N, Zangeneh A, Zangeneh MM. Protection of alloxan monohydrate-induced testicular toxicity by *Gundelia tournefortii* aerial parts aqueous extract in male mice. Iranian J Pharmacol Ther. 2018 (December);16: 1-9.

### ABSTRACT

For a long period, ethno medicinal plants have been a valuable source of natural products for maintaining human health, especially in the last decade, with more intensive studies for natural therapies. The use of ethno medicinal plant for pharmaceutical purposes has gradually increased in Iran. *Gundelia tournefortii* has been used as an antibacterial, anti-fungal, antipyretic, anti-inflammatory, and antioxidant agent in Iran. In the recent examination, the testicular protective effect of *G. tournefortii* aerial parts aqueous extract on diabetic mice has been evaluated. Seventy mice were used and diabetes was induced by administration of 150 mg/kg of alloxan monohydrate intraperitoneally in 60 mature male mice and they were randomly divided into six groups. The treatment groups received glibenclamide 10 mg/kg and 5, 10, 20 and 40 mg/kg of *G. tournefortii* through gavage for 20 days. Also, one group was considered as the non-diabetic control. At 20<sup>th</sup> day, the mice were killed, dissected, then blood and testis samples were collected for biochemical and stereological parameters analysis. The data were analyzed by SPSS-21 software. *G. tournefortii* at all doses (especially GT40) and glibenclamide significantly ( $p \leq 0.05$ ) ameliorated the concentrations of fasting blood glucose, testosterone, superoxide dismutase, catalase, glutathione reductase, and glutathione peroxidase. Also, multiple doses of *G. tournefortii* (especially GT40) and glibenclamide increased the weight and volume of the testis, the volumes of the tubule and interstitial tissue, the length and diameter of the tubule, the height of the germinal epithelium, and the number of the Leydig cell compared to the diabetic untreated group. According to the obtained results, *G. tournefortii* aerial parts aqueous extract can regulate the concentrations of biochemical parameters and inhibit testicular damages in alloxan monohydrate induced diabetic mice. It seems that *G. tournefortii* can be offered as a testicular protective supplement or drug for prevention, control, and treatment of testicular toxicity in diabetic patients.

Conflicts of Interest: Declared None

Funding: None

### Keywords

*Gundelia tournefortii*,  
Aqueous extract,  
Testicular toxicity,  
Alloxan monohydrate

### Corresponding to:

Akram Zangeneh,  
Department of Toxicology,  
Faculty of Veterinary Medicine,  
University of Tehran, Tehran,  
Iran, & Department of Clinical  
Science, Faculty of Veterinary  
Medicine, Razi University,  
Kermanshah, Iran

Email:

[akramzangeneh@yahoo.com](mailto:akramzangeneh@yahoo.com)

Received: 15 October 2018

Revised: 11 November 2018

Accepted: 15 December 2018

### INTRODUCTION

Diabetes is a group of metabolic disorders in which there are high blood sugar concentrations over a prolonged period [1]. Symptoms of high blood sugar include frequent

urination, enhanced thirst, and enhanced hunger [1]. If left untreated, diabetes can cause many complications. Acute complications can include hyperosmolar hyperglycemic

state, diabetic ketoacidosis, or death [2]. Serious long-term complications include damage to the eyes, foot ulcers, chronic kidney disease, stroke, and cardiovascular disease [2]. Also, diabetes has been associated with reproductive impairment of both men and women. About 90% of diabetic patients have turbulence in sexual function that includes reducing in libido, impotence, and infertility [3,4]. Previous studies revealed that two factors, enhanced oxidative stress and changes in antioxidant capacity are playing an important role in the pathogenesis of chronic diabetes [3-5]. Diabetes-inducing drugs are cytotoxic substances that induces diabetes in experimental animals. Moreover, they cause testicular dysfunction and degeneration by changing the antioxidant status in animal models [6].

Findings from different ethno medicinal plants screening have revealed their antioxidant and protective effects against diabetes-inducing drugs by increasing the concentrations of antioxidant enzymes [7-10]. Medicinal plants are popular remedies used by most people. The effect of ethno medicinal plants in the prevention, control, and treatment of diseases are irrecusably [11-13].

Population rise, inadequate supply of drugs, the prohibitive cost of treatments, side effects of several synthetic drugs and development of resistance to currently used drugs for infectious diseases have led to increased emphasis on the use of plant materials as a source of medicines for a wide variety of human ailments [14-16].

One of the most important herbal medicines, which is widely consumed in Iranian traditional medicine for treatment of testicular toxicity is *Gundelia tournefortii* from Asteraceae family [17]. It is a thistle plant that grows in some countries including Iran, Azerbaijan, Armenia, Iraq, and Turkey [17]. *G. tournefortii* is one of the edible plants which have generated a lot of interest throughout human history as a medicinal plant [18,19].

Several extracts of this plant have been traditionally used in treating parasitic, viral, fungal, and bacterial diseases [18,19]. Also, *G. tournefortii* has been consumed as an anti-inflammatory and antioxidant supplement in Iran [17]. High prevalence of testicular toxicity in the whole world has drawn the attention of researchers in finding remedial and preventive methods to control and treat the disease. In this regard, we attempted to study the testicular protective effect of *G. tournefortii* aerial parts aqueous extract on the treatment of testicular toxicity in male mice.

## MATERIALS AND METHODS

### Animals

Seventy Balb/c male mice weighing 38-40 g were procured from laboratory animal center of Kermanshah University of Medical Sciences, Kermanshah, Iran. The animals were housed in an air-conditioned room (22±2 °C) with 12 h light/dark cycle and had free access to standard pellet diet and water. The study was approved by Local Research Ethics Committee of Razi University, Kermanshah, Iran on 2018/06/18 with the ethical code of 397-3-002.

### Plant extraction

*G. tournefortii* was collected from Kermanshah city (geographical coordinates: 34.3277° N, 47.0778° E), Kermanshah province, Iran during March 2017. Then, the aerial parts of the plant were dried in shadow and after grinding, each time 200 gr of the obtained powder was dissolved in 2000 cc distilled water and put in Soxhlet extractor for 8 h (Total 2000 gr). The collected extract was filtered by Whatman filter paper no 1 and steamed into a glass container at the solvent temperature. The remaining dried extract was poured into a glass container and weighed. The powder of the obtained extract was weighed as required depending on the dose [20-22]. Distilled water was used for dissolve the aqueous extract of the plant.

### Experimental design

Diabetes was induced by a single intraperitoneal (IP) administration of alloxan monohydrate (150 mg/kg.bw). Fasting blood glucose concentration was assessed every day by Easy Gluco glucometer (Ames, Korea). A fasting blood glucose level higher than 250 mg/dL was considered diabetic.

In our study, the mice were divided into seven following groups ( $n=10$ ):

- (1) Control (Non diabetic) group which received 200  $\mu$ L normal saline orally.
- (2) The untreated-diabetic group which received 200  $\mu$ L normal saline orally.
- (3) Treated diabetic mice which received 10 mg/kg glibenclamide for 20 days.
- (4) Treated diabetic mice which received 5 mg/kg of the aqueous extract of *G. tournefortii* aerial parts aqueous extract for 20 days.
- (5) Treated diabetic mice which received 10 mg/kg of the aqueous extract of *G. tournefortii* aerial parts aqueous extract for 20 days.
- (6) Treated diabetic mice which received 20 mg/kg of the aqueous extract of *G. tournefortii* aerial parts aqueous extract for 20 days.
- (7) Treated diabetic mice which received 40 mg/kg of the aqueous extract of *G. tournefortii* aerial parts aqueous extract for 20 days.

### Blood sampling and determination of biochemical parameters

Blood samples were obtained in 0, 7, 13, and 20 days of the experiment from the tail vein in routine tubes to assess the blood glucose level by Easy Gluco glucometer (Ames, Korea). At the end of the 20<sup>th</sup> day of treatment, the animals of all groups were euthanized by xylazine (5 mg/kg) and ketamine HCl (40 mg/kg). For separation of serum, the samples were centrifuged at 10,000 rpm for 15 min [7-10]. The concentration of testosterone was evaluated in the serum by the enzyme-linked immunosorbent assay method and hormone measurement kit (Immunotech SA, France, PI-1119). The capacity of antioxidant enzymes was evaluated

by determining the activity of superoxide dismutase (SOD) [23], catalase (CAT) [24], glutathione reductase (GR) [24], and glutathione peroxidase (GPx) [24] in right testis of each group.

### Stereological study

The left testis of each mouse was removed and the epididymis was separated. The testes were then weighted and the primary volume was estimated using the immersion method [25]. Afterward, the testes were immersed in %10 buffered formalin for one week. To estimate reference volume (total volume), the tissue shrinkage was determined first. Estimation of tissue shrinkage and also total length of seminiferous tubules required isotropic uniform random (IUR) sections. These sections were obtained through orientator method [26,27]. The testis was placed on a circle, such that each half of was divided into 10 equal parts. A random number between 0 and 9 was selected. The testis was sectioned into two parts at the direction of the selected number. The cut surface of one part of the testis was then placed parallel to the 0-0 direction of the second circle with 10 unequal divisions. The circle division was done according to the cosine of the angles. Then, another random number was selected and the second cut was done. The cut surface of the other part of the testis was placed vertically on the second circle. Again, a new number and direction were selected and cut. These parts were entirely sectioned into parallel slabs at the direction of the selected numbers. Overall, 8-10 slabs were collected from each testis. For estimating tissue shrinkage, a circle was punched from a testis slab by a trocar. The diameter of the circular piece of the testis was measured by a micrometer and the area of the circle was estimated, using the usual formula for calculating the area of a circle. The cut surfaces of all slabs and circular piece were embedded in paraffin, sectioned (5  $\mu\text{m}$  thicknesses) and stained by Hematoxylin and Eosin method. After staining, the area of the circular piece was measured again and volume shrinkage was calculated from the following formula [27]:

$$\text{Volume shrinkage} = 1 - (\text{AA} / \text{AB})^{1.5}$$

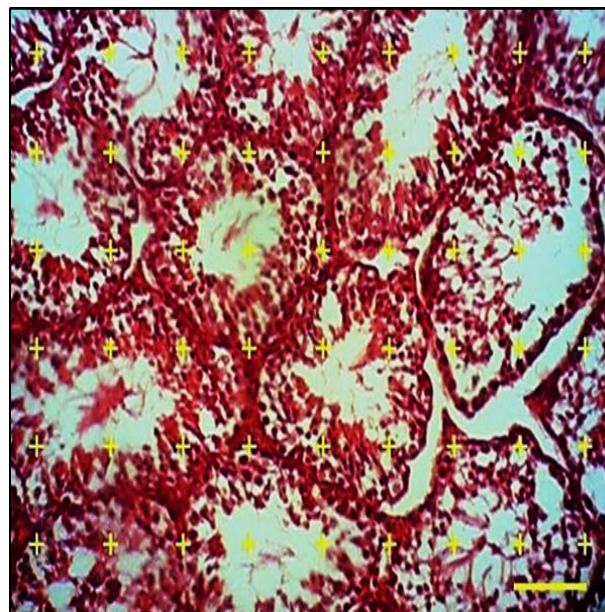
Where, AA and AB are the diameter of the punched circle after and before tissue processing and staining.

The final volume of the testis was calculated using the following formula:

$$V_{\text{final}} = V_{\text{primary}} \times (1 - \text{volume shrinkage})$$

### Volume estimation

All sampled sections were analyzed by using a video microscopy system consisting of a microscope (Olympus CX2, Japan) linked to a video camera (Dinocapture ver.5, dino-lit.com 30.5 mm), a computer and a flat monitor to determine the parameters. The point probe (10 $\times$ 10 cm composed of 25 points) was superimposed upon the images of the tissue sections viewed on the monitor, and volume density ( $V_v$ ) of seminiferous tubules and interstitial tissue were obtained using a point-counting method from following formula [26]:



**Figure 1.** Point counting method: to estimate volume density of the seminiferous tubules and interstitial tissue a point probe was superimposed on the images of the tissue sections. The total number of points hitting each component was divided by the total number of the points hitting the reference space (Hematoxyline and Eosin  $\times 100$ , scale bar: 50  $\mu\text{m}$ ).

$$V_v = P_{\text{structure}} / P_{\text{reference}}$$

In this formula  $P_{\text{structure}}$  and  $P_{\text{reference}}$  were the numbers of test points falling on the structures profile and the reference space, respectively. Fourteen microscopic fields were examined in each testis (Fig. 1).

The absolute volume of the parameters was estimated by multiplying the fractional volume by the final volume of the testis to prevent the reference trap [27, 28].

### Length estimation

The length density of the seminiferous tubules was estimated using a counting probe (740 $\times$ 740 $\mu\text{m}$ ) and the following formula [27, 28]:

$$L_v = 2(\Sigma Q / a(\text{frame}) \times \Sigma(\text{frame}))$$

Where  $\Sigma Q$  is the sum of the structures counted,  $a(\text{frame})$  is probe area, 547600  $\mu\text{m}^2$  and  $\Sigma(\text{frame})$  is the total number of the counted frames. The diameter of the tubules was measured perpendicular to the long axis where the tubule was widest. An average of 100 profiles was counted per testis.

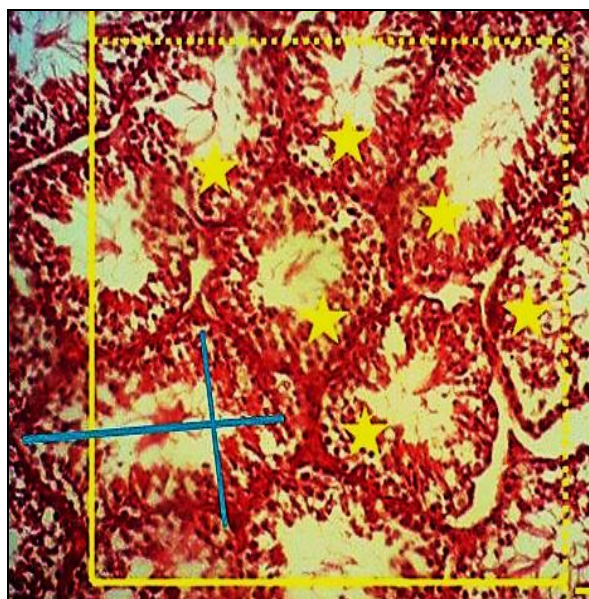
### Estimation of the germinal epithelium height

The height of the germinal epithelium was estimated using the following formula [27]:

$$H = V_v / S_v$$

In which  $V_v$  and  $S_v$  were the volume density and surface density of the germinal epithelium, respectively. The volume density of the germinal epithelium was obtained by point counting method and the surface density of the germinal epithelium was estimated using a linear test probe (Fig. 2).





**Figure 2.** The length density of seminiferous tubules was estimated by superimposing an unbiased counting frame with inclusion (dashed) lines and exclusion (thick) lines on the images of the tissue sections. The tubule profiles completely inside the counting frame or partly inside the counting frame but only touching the inclusion lines were counted (here 6 tubules Hematoxyline and Eosin  $\times 100$ , scale bar: 50  $\mu\text{m}$ ).

#### Estimation of Leydig cells number

The total number of Leydig cells per testis was estimated using the physical disector method [29]. Approximately 10 pairs of serial sections were sampled from each testis. Two disector probe (740 $\times$ 740  $\mu\text{m}$ ) with exclusion lines (the left and lower borders) and inclusion lines (the right and upper borders) were superimposed on the images of the first section as the reference plane and second section as the look-

up plane at the total magnification 400x. The counting rules of physical disector were applied. A cell was considered if it was found in the reference plane but not in the look up the plane as well as didn't hit the lower and left lines of the probe. At least 200 cells per testis were counted. The numerical density was estimated using:

$$N_v = \Sigma Q / a (\text{frame}) \times h \times \Sigma P$$

Where  $\Sigma Q$  is the sum of the counted cells,  $a$  (frame) is probe area,  $\Sigma P$  is the total number of the examined fields and  $h$  is disector height.

The Leydig cells were recognized in the interstitium as relatively large ovoid shaped cell with an eccentric nucleus. The nucleus contained a prominent nucleolus and peripherally localized chromatin. The total number of the Leydig cells was estimated by multiplying the numerical density by the final testis volume.

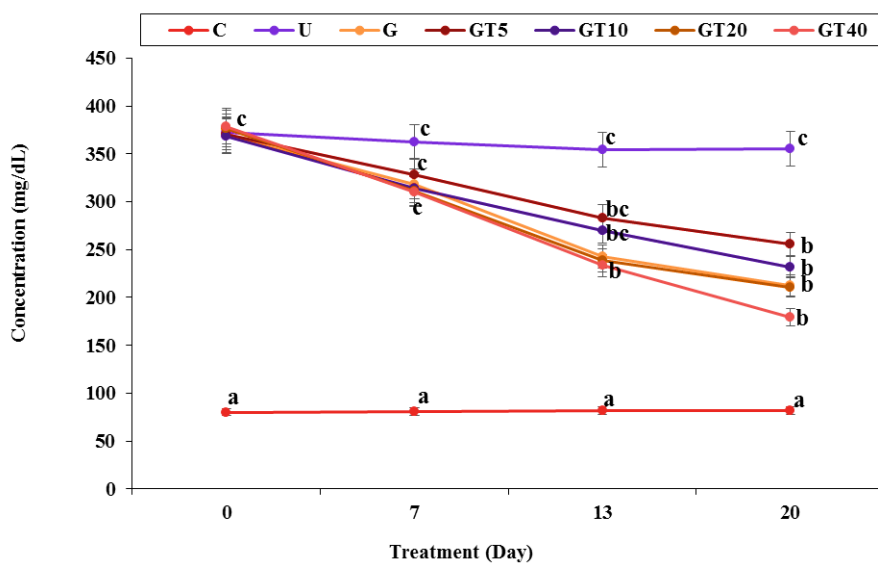
#### Statistical analysis

Data expressed as mean  $\pm$  SD and were analyzed by one way ANOVA and Duncan's test.  $P \leq 0.05$  was considered significant.

## RESULTS

### Effect of *G. tournefortii* aerial parts aqueous extract on the fasting blood glucose concentration

The effect of the *G. tournefortii* aerial parts aqueous extract on the fasting blood glucose concentration in the diabetic mice has been indicated in Figure 3. There was no remarkable change ( $p \leq 0.05$ ) in fasting blood glucose concentration of normal control mice throughout the study. The fasting blood glucose concentration of untreated diabetic mice increased to approximately 350% ( $p \leq 0.05$ ) of the control mice in a time-dependent manner. However, treatment of alloxan monohydrate-diabetic mice with the *G. tournefortii* at all doses could significantly ( $p \leq 0.05$ ) decrease



**Figure 3.** Fasting blood glucose concentration in several groups. C: Control, U: Untreated, G: Glibenclamide, GT: *Gundelia tournefortii*. Non-like letters show a remarkable change between the several groups ( $p \leq 0.05$ ).

the fasting blood glucose concentration similar to the glibenclamide-treated at the end of the experiment. The *G. tournefortii* has the most effect on day 20 of the experiment.

#### Effect of *G. tournefortii* aerial parts aqueous extract on the biochemical parameters concentrations

The concentrations of testosterone, SOD, CAT, and GPx were decreased and the concentration of GR was increased significantly ( $p \leq 0.05$ ) in untreated diabetic mice. Treatment with *G. tournefortii* aerial parts aqueous extract at all doses significantly ( $p \leq 0.05$ ) improved the concentrations of the above parameters in comparison of untreated diabetic mice.

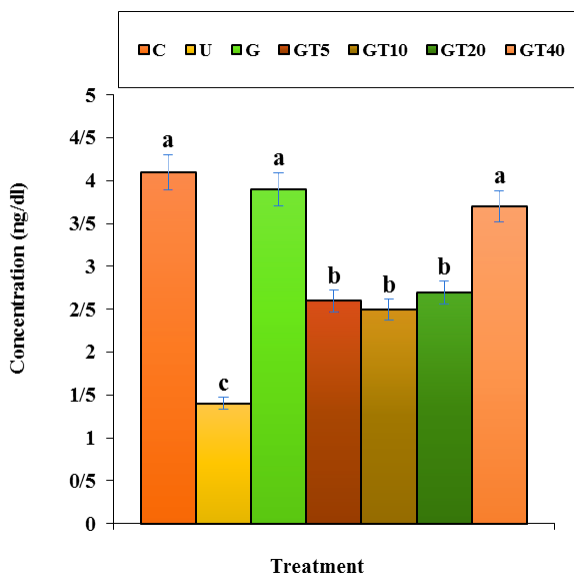


Figure 4. Testosterone concentration in several groups. C: Control, U: Untreated, G: Glibenclamide, GT: *Gundelia tournefortii*. Non-like letters show a remarkable change between the several groups ( $p \leq 0.05$ ).

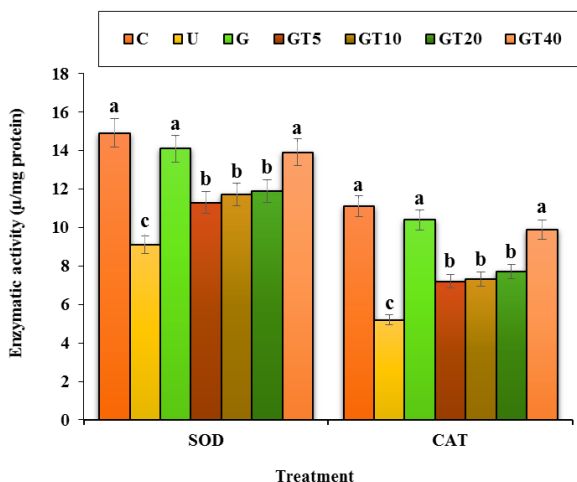


Figure 5. Testis SOD and CAT concentrations in several groups. C: Control, U: Untreated, G: Glibenclamide, GT: *Gundelia tournefortii*, SOD: Superoxide dismutase, CAT: Catalase. Non-like letters show a remarkable change between the several groups ( $p \leq 0.05$ ).

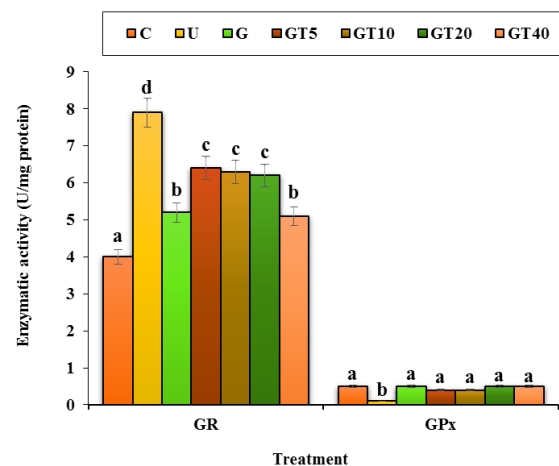


Figure 6. Testis GR and GPx concentrations in several groups. C: Control, U: Untreated, G: Glibenclamide, GT: *Gundelia tournefortii*, GR: Glutathione reductase, GPx: Glutathione peroxidase. Non-like letters show a remarkable change between the several groups ( $p \leq 0.05$ ).

Administration of GT40 and glibenclamide could significantly ( $p \leq 0.05$ ) increase the concentrations of testosterone, SOD, and CAT similar to that of the control group. No remarkable change ( $p \leq 0.05$ ) was observed among *G. tournefortii*, glibenclamide, and control groups in the concentration of GPx. In details, the effect of the *G. tournefortii* on the biochemical parameters concentrations in the diabetic mice has been shown in Figures 4-6.

#### Effect of *G. tournefortii* aerial parts aqueous extract on the stereological parameters levels

Administration of *G. tournefortii* aerial parts aqueous extract at all doses could significantly ( $p \leq 0.05$ ) increase the

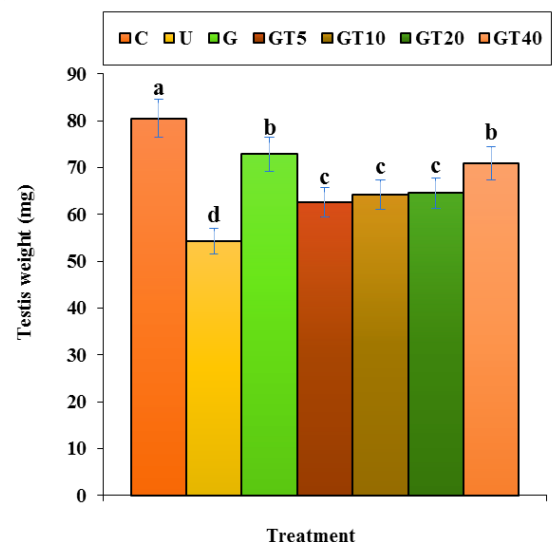
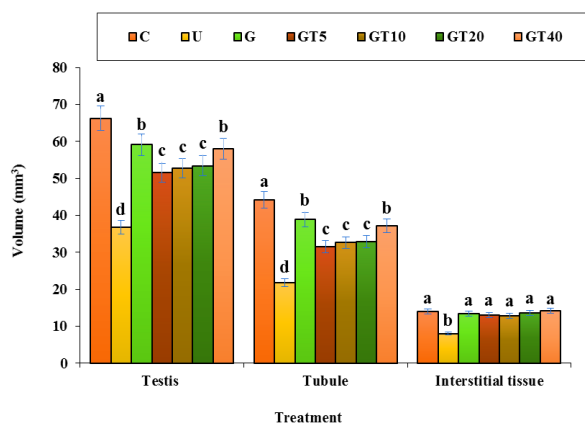
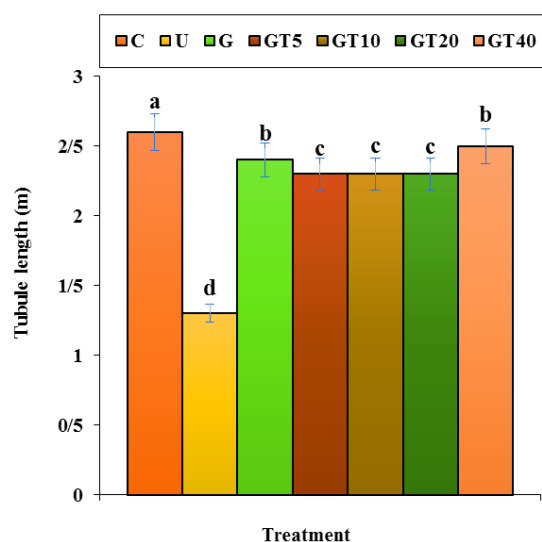


Figure 7. Testis weight in several groups. C: Control, U: Untreated, G: Glibenclamide, GT: *Gundelia tournefortii*. Non-like letters show a remarkable change between the several groups ( $p \leq 0.05$ ).



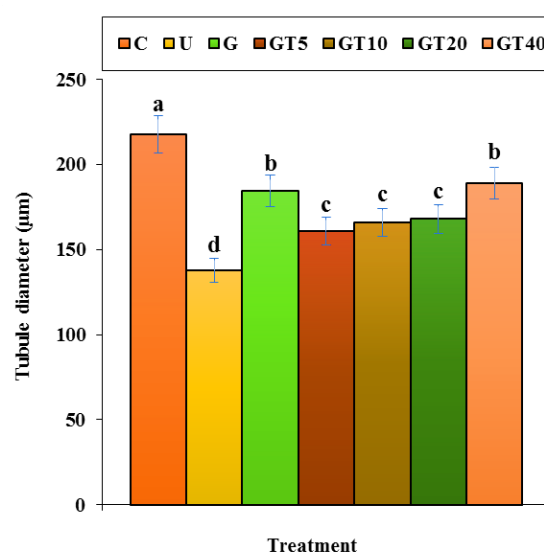
**Figure 8.** Testis, tubule, interstitial tissue volumes in several groups. C: Control, U: Untreated, G: Glibenclamide, GT: *Gundelia tournefortii*. Non-like letters show a remarkable change between the several groups ( $p \leq 0.05$ ).



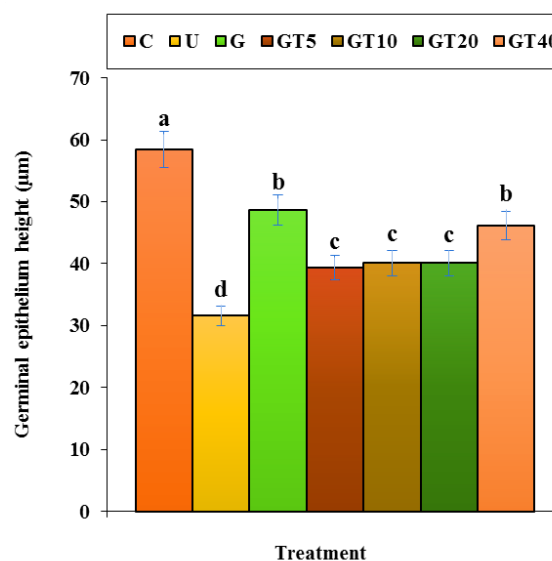
**Figure 9.** Tubule length in several groups. C: Control, U: Untreated, G: Glibenclamide, GT: *Gundelia tournefortii*. Non-like letters show a remarkable change between the several groups ( $p \leq 0.05$ ).

testis weight compared to the untreated group (Fig. 7). No remarkable change was noticed ( $p \leq 0.05$ ) between GT40 and glibenclamide groups in the monitored parameter.

The volumes of the testis, tubule, and interstitial tissue, the length and diameter of the tubule, the height of the germinal epithelium, and the number of the Leydig cell decreased significantly ( $p \leq 0.05$ ) in the untreated mice group in comparison with the control ones (Figs. 8-12). Administration of *G. tournefortii* aerial parts aqueous extract at all doses could significantly ( $p \leq 0.05$ ) increase the above parameters. There wasn't a significant difference ( $p \leq 0.05$ ) in the above parameters between GT40 and the glibenclamide group. Gavage of *G. tournefortii* at all doses and glibenclamide could significantly ( $p \leq 0.05$ ) increase the volume of interstitial tissue and the length of tubule similar



**Figure 10.** Tubule diameter in several groups. C: Control, U: Untreated, G: Glibenclamide, GT: *Gundelia tournefortii*. Non-like letters show a remarkable change between the several groups ( $p \leq 0.05$ ).

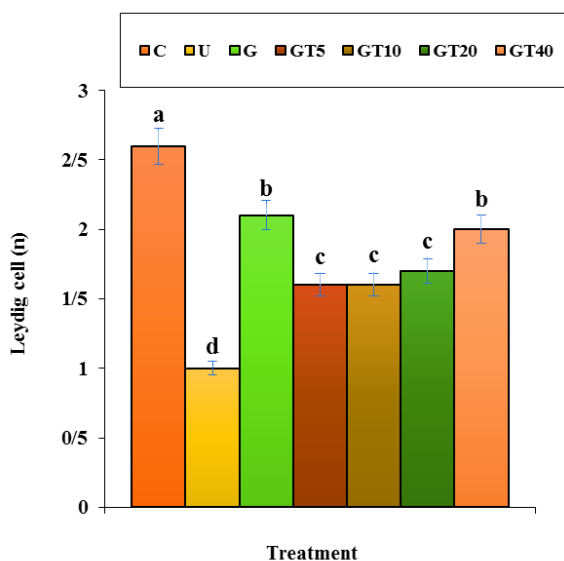


**Figure 11.** Germinal epithelium height in several groups. C: Control, U: Untreated, G: Glibenclamide, GT: *Gundelia tournefortii*. Non-like letters show a remarkable change between the several groups ( $p \leq 0.05$ ).

to that of the control group.

## DISCUSSION

The therapeutical benefits of herbal medicine have been recognized for centuries by clinical experience and practice [30-33]. They have the immense potential on the management and treatment of every disease such as testicular toxicity [34]. Considerable number of ethno medicinal plants are consumed for their testicular protective, including; *Allium sativum*, *Lagenaria breviflora* Robert,



**Figure 12.** Leydig cell number in several groups. C: Control, U: Untreated, G: Glibenclamide, GT: *Gundelia tournefortii*. Non-like letters show a remarkable change between the several groups ( $p \leq 0.05$ ).

*Azadirachta indica* A., *Aegle marmelos*, *Garcinia cambogia*, *Dendrophthoe falcate*, *Juniperus phoenicea* L., *Rosmarinus officinalis* L., *Quassia amara*, *Martynia annua*, *Mentha arvensis*, *Hibiscus sabdariffa*, *Cestrum parqui*, *Tropaeolum tuberosum*, *Curcuma longa* L., and *Barleria prionitis* [34].

*G. tournefortii* as a plant in Iranian traditional medicine has been demonstrated to have some optimal treatment effects, due to its antioxidant effects both in vitro and in vivo. It also indicated protective activities against toxicity most of the body organs [17]. But, to our knowledge, this is the first time *G. tournefortii* aerial parts aqueous extract with these doses has been used for experimentally induced diabetes in mice and, except its antioxidant, anti-inflammatory, and antimicrobial properties; there is no information about other beneficial effects of *G. tournefortii* aerial parts aqueous extract.

In our study, Diabetes was induced in all mice by single intraperitoneal injection of alloxan monohydrate. In diabetes, partially annihilates the beta cells of Langerhans islets, hepatocytes, nephron, RBC, and testicular cells resulting in inexpressive insulin secretion causing type 2 diabetes, hepatotoxicity, nephrotoxicity, hematotoxicity, and especially testicular toxicity [35].

About testicular toxicity, toxic substances such as diabetes-inducing drug, pesticides, radiation, cigarette smoking, alcohol, marijuana or taking certain medications, such as select antibiotics, antihypertensives, anabolic steroids or others can imbalance the core body temperature and affect sperm and testosterone production [3,6]. Abnormal glucose homeostasis has adverse outcomes for the reproductive function in the male gametes [3]. Testicular function and spermatogenesis are affected in both type 1 and type 2 diabetic men [3]. Traditional light microscopic

analysis of the ejaculate suggests that the effect of diabetes on semen quality is negligible and molecular investigation techniques have demonstrated that diabetic men have a dramatically higher percentage of sperm with nuclear and mitochondrial DNA fragmentation and that the damage is oxidative in nature [3,6]. Sperm DNA damage is known to be associated with the decreased embryo quality, the lower implantation rates, and, possibly, the early onset of some childhood diseases [3,6].

The results of serum fasting blood glucose concentration revealed that all doses of *G. tournefortii* on days 16 and 20 showed a remarkable change in comparison with the untreated diabetic group. But there was no remarkable change between the experimental doses of *G. tournefortii* and classic antidiabetic drug, glibenclamide, these days. In agreement with the present results, there is a study which has shown the antidiabetic activity of *Gundelia* genus with decreasing of fasting blood glucose concentration in diabetic mice [36].

In the recent examination, *G. tournefortii* aerial parts aqueous extract at all doses similar to that of the glibenclamide could significantly ( $p \leq 0.05$ ) increase the concentrations of testosterone, SOD, CAT, and GPx and decrease the concentration of GR. In several studies, phenolic compounds such as Quercetin refined from *G. tournefortii* extract [37]. Quercetin is the most numerous natural flavonoid in vegetable and plant, but it is a group of flavonoid without glycoside. Flavonoids without glycoside have more strong antioxidants related to their glycoside flavonoid [38-40]. Other study indicated the strong antioxidant activity of Quercetin against copper-producing free radicals [41]. In a study, *G. tournefortii* rich of Quercetin had the high capacity of antioxidant against 2,2-diphenyl-1-picrylhydrazyl and improved the capacity of antioxidant enzymes [18].

Oxidative stress, lipid peroxidation, and change in membrane characteristics cause death of the generative cell in several stages of growth and cause to reduce of sperm amount and peroxide of hydrogen can immobile sperms. Antioxidant therapy, is a protection defense against oxidative stress and ameliorating fertility parameters [42-45]. Quercetin as strong antioxidant compound available in *G. tournefortii* has protective activity on spermatogonia cells under oxidative stress and by giving the electron to active oxygen types (ROS) reduce destruction DNA [46,47]. Quercetin reduces destructive activity of 2, 3, 7, 8 tetra chlorodibenzo-pdioxin (TCDD) on testis tissue and sperm parameters and testosterone hormones, so the levels of these parameters increases [48]. The positive role of Quercetin on the testosterone concentration of men is proof and it is clear that Quercetin raise the concentration of testosterone in men [49,50].

The results of stereological study indicated that several doses of *G. tournefortii* aerial parts aqueous extract (especially GT40) and glibenclamide raised the weight and volume of testis, the volumes of tubule and interstitial tissue, the length and diameter of tubule, the height of germinal



epithelium, and the number of Leydig cell compared to the diabetic untreated group. Increasing of testis weight and volume probably is because of Quercetin. Because Quercetin due to its powerful antioxidant properties, with developing of the seminiferous tube and interstitial tissue or increasing number of cells such as spermatozoid and Leydig in testis, increases the weight and volume of testis [51].

## CONCLUSION

From the observations and monitored parameters, it can be concluded that all doses of *G. tournefortii* aerial parts aqueous extract (especially GT40) has a testis protective activity against testis structural changes induced by STZ in diabetic mice. Additional clinical trials studies would be needed to justify the potential of the *G. tournefortii* as a testis protective agent in the human.

## CONFLICTS OF INTEREST

The author(s) declare(s) that there is no conflict of interest regarding the publication of this article

## REFERENCES

- Kitabchi AE, Umpterrez GE, Miles JM, Fisher JN. Hyperglycemic crises in adult patients with diabetes. *Diabetes. Care* 2009;32(7):1335–1343.
- Chiang JL, Kirkman MS, Laffel LMB, Peters AL. Type 1 Diabetes Through the Life Span: A Position Statement of the American Diabetes Association. *Diabetes. Care* 2014;37(7):2034–2054.
- Shi-Liang FENG, Shu-Hua LI, Yan WANG, Chang-Chun CHEN, Bin GAO. Effect of ligustrum fruit extract on reproduction in experimental diabetic rats. *Asian. J Androl* 2001;3(1):71–73.
- Jiang GY. *Practical Diabetes*. 1st Edition. Beijing: People's Health Publishing House. 1996: 295.
- Baynes JW, Thorpe SR. Role of oxidative stress in diabetic complications: a new perspective on an old paradigm. *J Diabetes* 1999;48(1):1–9.
- Shrilatha B, Muralidhara. Early oxidative stress in testis and epididymal sperm in streptozotocin-induced diabetic mice: its progression and genotoxic consequences. *J Reprod Toxicol* 2007;23(4):578–587.
- Hagh-Nazari L, Goodarzi N, Zangeneh MM, Zangeneh A, Tahvilian R, Moradi R. Stereological study of kidney in streptozotocin-induced diabetic mice treated with ethanolic extract of *Stevia rebaudiana* (bitter fraction). *Comp Clin Path* 2017;26(2):455–463.
- Najafi F, Goodarzi N, Zangeneh MM, Zangeneh A, Hagh-Nazari L. Antidiabetic and hepatoprotective effects of bitter fraction of *Stevia rebaudiana* alcoholic extract on streptozotocin-induced diabetic male mice. *J. Rafsanjan. Univ Med Sci* 2017;16(6):493–504.
- Zangeneh MM, Zangeneh A, Amiri H, Amiri N, Tahvilian R, Moradi R, et al. Nephroprotective activity of *Alyssum meniocoides* Boiss aqueous extract on streptozotocin-induced diabetic nephrotoxicity in male mice. *Comp Clin Path* 2018;27(5):1147–1154.
- Zangeneh MM, Goodarzi N, Zangeneh A, Tahvilian R, Najafi F. Amelioration of renal structural changes in STZ-induced diabetic mice with ethanolic extract of *Allium saralicum* R.M. Fritsch. *Comp Clin Path* 2018;27(4):861–867.
- Musabayane CT. The effects of medicinal plants on renal function and blood pressure in diabetes mellitus. *Cardiovasc. J Afr* 2012;23(8):462–468.
- Sherkatolabbasieh H, Hagh-Nazari L, Shafiezhadeh S, Goodarzi N, Zangeneh MM, Zangeneh A. Ameliorative effect of the ethanolic extract of *Allium saralicum* R.M. Fritsch on CCl<sub>4</sub>-induced nephrotoxicity in mice: a stereological examination. *Arch Biol Sci* 2017;69(3):535–543.
- Faramarzi E, Zangeneh MM, Zangeneh A, Moradi R. Effect of *Cinnamomum zelanicum* oil on hyponeophagia anxiety test in Balb C male mice. Online. *J Vet Res* 2017;21(2):77–80.
- Foroughi A, Pournaghi P, Najafi F, Zangeneh A, Zangeneh MM, Moradi R. Antibacterial effect and phytochemical screening of essential oil of *Pimpinella anisum* against *Escherichia coli* O157:H7 and *Staphylococcus aureus*. *Int J Curr Med Pharm Res* 2016;7(6):367–371.
- Tahvilian R, Moradi R, Zhaleh H, Zangeneh MM, Zangeneh A, Yazdani H, et al. Chemical composition and screening of antibacterial activity of essential oil of *Pistacia khinjuk* against two selected pathogenic bacteria. *Ann Trop Med Public Health* 2017;10(5):1159–1164.
- Ghashghaii A, Hashemnia M, Nikousefat Z, Zangeneh MM, Zangeneh A. Wound healing potential of methanolic extract of *Scrophularia striata* in rats. *Pharm Sci* 2017;23(4):256–263.
- Jamshidzadeh A, Fereidooni F, Salehi Z, Niknahad H. Hepatoprotective activity of *Gundelia tourenfortii*. *J Ethnopharmacol* 2005;101(1-3):233–237.
- Coruh N, Sagdicoglucelep AG, Ozgokce F, Iscan M. Antioxidant capacities of *Gundelia tournefortii* L. extracts and inhibition on glutathione-s-transferase activity. *Food Chem* 2007;100(3):1249–1253.
- Sharaf KH, Ali JS. Hypolipemic effect of Kuub (*Gundelia tournefortii* A.) oil and clofibrate on lipid profile of atherosclerotic rats. *Vet Archive* 2004;74(5):359–369.
- Zangeneh MM, Salmani S, Zangeneh A, Khedri R, Zarei MS. Histopathological and biochemical effects of aqueous extract of *Tragopogon graminifolius* on the liver tissues of Wistar rats fed with high-fat diet. *Com Cli Path* 2018b.
- Zangeneh MM, Zangeneh A, Tahvilian R, Moradi R. Antidiabetic, hematoprotective and nephroprotective effects of the aqueous extract of *Falcaria vulgaris* in diabetic male mice. *Arch Biol Sci* 2018c.
- Zangeneh MM, Zangeneh A, Tahvilian R, Moradi R, Zhaleh H, Amiri-Paryan A, Bahrami E. Hepatoprotective and hematoprotective effects of *Falcaria vulgaris* aqueous extract against CCl<sub>4</sub>-induced hepatic injury in mice. *Comp Clin Path* 2018d;27(5):1359–1365.
- Martin JP, Dailey M, Sugarman E. Negative and positive assays of superoxide dismutase based on hematoxylin autoxidation. *Arch Biochem Biophys* 1987;255(2):329–336.
- Abel H. Catalase. In: Bergmeyer HU, Ed. *Methods of enzymatic analysis*. New York: Academic Press. 1974.
- Silva MAJ, Merzel J. Stereological determination of the volume of the rat hemimandible rat tissue. *Anat Rec* 2001;263(3):255–259.
- Gundersen HJ, Bendtsen TF, Korbo L, Marcussen N, Moller A, Nielsen K. Some new, simple and efficient stereological methods and their use in pathological research and diagnosis. *J Pathol Microbiol Immunol* 1988;96(5):379–394.
- Nyengaard JR. Stereologic methods and their application in kidney research. *J Am Soc Nephrol* 1999;10(5):1100–1123.
- Mandarim-de-Lacerda CA. Stereological tools in biomedical research. *An Acad Bras Cienc* 2003;75(4):469–486.
- Sterio DC. The unbiased estimation of number and sizes of arbitrary particles using the disector. *J Microsc* 1984;134(2):127–136.
- Sayyedrostami T, Pournaghi P, Ebrahimi Vosta-Kalaeae S, Zangeneh MM. Evaluation of the wound healing activity of *Chenopodium botrys* leaves essential oil in rats (A short-term study). *J Essent Oil Bear Pl* 2018;21(1):164–174.
- Zhaleh M, Sohrabi N, Zangeneh MM, Zangeneh A, Moradi R, Zhaleh H. Chemical composition and antibacterial effects of essential oil of *Rhus coriaria* fruits in the west of Iran (Kermanshah). *J Essent Oil Bear Pl* 2018;21(2):493–501.
- Hamelian M, Zangeneh MM, Amisama A, Varmira K, Veisi H. Green synthesis of silver nanoparticles using *Thymus kotschyanus* extract and evaluation of their antioxidant, antibacterial and cytotoxic effects. *Appl Organometal Chem* 2018;32(9):e4458.
- Farzaei MH, Zangeneh MM, Goodarzi N, Zangeneh A. Stereological assessment of nephroprotective effects of *Trachyspermum ammi* essential oil against carbon tetrachloride-induced nephrotoxicity in mice. *Int J Morphol* 2018;36(2):750–757.
- D'Cruz SC, Vaithinathan S, Jubendradass R, Mathur PP. Effects of



- plants and plant products on the testis. *Asia J Androl* 2010;12(4):468-79.
35. Saini R, Patil SM. Anti-diabetic activity of roots of *Quercus fectoria* Olivier in alloxan induced diabetic rats. *Int J Pharm Sci Res* 2012;3(4):1318-1321.
36. Hamdan II, Afifi F.U. Studies on the in vitro and in vivo hypoglycemic activities of some medicinal plants used in treatment of diabetes in Jordanian traditional medicine. *J Ethnopharmacol* 2004;93(1):117-121.
37. Apak R, Guclu K, Demirata B, Ozyürek M, Celik SE, Bektaşoğlu B, et al. Comparative evaluation of various total antioxidant capacity assays applied to phenolic compounds with the CUPRAC assay. *Molecules* 2007;12(7):1496-547.
38. Heim KE, Tagliaferro AR, Bobilya DJ. Flavonoid antioxidants: Chemistry, metabolism and structure activity relationships. *J Nutr Biochem* 2002;13(10):572-584.
39. Justesen U, Knuthsen P. Composition of flavonoids in fresh herbs and calculation of flavonoid intake by use of herbs in traditional Danish dishes. *Food Chem* 2001;73(2):245-250.
40. Suzuki Y, Ishihara M, Segami T, Ito M. Antiulcer effects of antioxidants, quercetin, alphatocopherol, nifedipine and tetracycline in Rats. *Jpn J Pharmacol* 1998;78(4):435-441.
41. Filipe P, Haigle J, Silva JN, Freitas J, Fernandes A, Mazière JC, et al. Anti-and pro-oxidant effects of quercetin in copper-induced low density lipoprotein oxidation. Quercetin as an effective antioxidant against pro-oxidant effects of urate. *Eur J Biochem* 2004;271:1991-1999.
42. Khaki A, Fathiazad F, Nouri M, Afshin Khaki A, Ozanci CC, Ghafari-Novin M, et al. The effects of Ginger on spermatogenesis and sperm parameters of rat. *Iran J Reprod Med* 2009;7(1):7-12.
43. Acharya UR, Mishra M, Patro J, Panda MK. Effect of vitamins C and E on spermatogenesis in mice exposed to Cadmium. *Reprod Toxicol* 2008;25(1):84-88.
44. Agarwal A. Significance of oxidative stress and sperm chromatin damage in male infertility. In: Armand B, Christophe R, Stephanie R, and De Vriese. Male fertility and lipid metabolism. Champaign, Illinois: AOCS Publishing. 2003:157-183.
45. Yousef MI. Protective role of ascorbic acid to enhance reproductive performance of male rabbits treated with stannous chloride. *Toxicol* 2005;207(1):81-89.
46. Li G, Ma A, Shi W, Zhong X. Quercetin protects hamster spermatogenic cells from oxidative damage induced by diethylstilboestrol. *Andrologia* 2010;42(5):285-290.
47. Vargas AJ, Burd R. Hormesis and synergy: Pathways and mechanisms of quercetin in cancer prevention and management. *Nutr Rev* 2010;68(7):418-428.
48. Ciftci O, Aydin M, Ozdemir I, Vardi N. Quercetin prevents 2, 3, 7, 8-tetrachlorodibenzo-p-dioxin induced testicular damage in rats. *Andrologia* 2012;44(3):164-173.
49. Barney P. Doctor's guide to natural medicine. 1st ed. Utah: Woodland Publishing. 1998:45.
50. Ma Z, Nguyen TH, Huynh TH, Tien Do P, Huynh H. Reduction of rat prostate weight by combined quercetin-finasteride treatment is associated with cell cycle deregulation. *J Endocrinol* 2004;181(3):493-507.
51. Taepongsorat L, Tangpraprutgul P, Kitana N, Malaivijitnond S. Stimulating effects of quercetin on sperm quality and reproductive organs in adult male rats. *Asia J Androl* 2008;10(2):249-258.