

Effect of Short and Long Term Intake of Traditional Aphrodisiac Cantharis Q on Liver of Male Albino Rat

ROSHAN CLARENCE D'SOUZA and RAGHUNANDAN P. ATHALYE

For author affiliations, see end of text.

Received February 28, 2013; Revised June 12, 2013; Accepted August 5, 2013

This paper is available online at <http://ijpt.tums.ac.ir>

ABSTRACT

Cantharis Q has a long history in both folk and traditional medicine being used as an aphrodisiac. It is a crude alcoholic extract of blister beetle *Lytta vesicatoria* commonly known as Spanish fly having cantharidin, a venomous substance present in it. The aim of the present study was to evaluate the clinical application of Cantharis Q by assessing its effect on the vital organ, liver, for a short and long period in male albino rat. The recovery study was also carried out in order to establish the reversibility of the treatment. Male albino rats of Wistar strain were given daily oral dosage of 500 µg/Kg body weight Cantharis Q for 15 and 60 days. One group of 60-day treated rats was then kept for recovery without dosing for 30 days. The biochemical analysis of liver showed that the activity of alkaline and acid phosphatase enzymes decreased in the treated rats for both durations of treatment. Livers of 15-day treated animals had significantly increased RNA and total protein. Sixty days treatment led to a significant increase in cholesterol and significant decrease in glycogen, total protein and RNA levels in liver. Recovery animals had liver glycogen content significantly depleted whereas cholesterol, total protein and RNA increased significantly. The histopathology showed loss of cytoarchitecture in various areas of liver, vacuolation and inflammatory cellular infiltration in all the groups. Thus, it was observed that oral intake of Cantharis Q had a negative impact on the hepatic function of male rats and the recovery was also not found to be significant.

Keywords: *Cantharis Q, Aphrodisiac, Clinical application, Liver, Biochemical analysis, Histopathology*

In many developing countries, traditional medicines are widely utilized in the treatment of various ailments including male reproductive function on an empirical basis. Fruits of *Piper guineense* are used as aphrodisiac and have been shown to stimulate sexual behaviour of mature male rats [1-2]. *Litsea chinensis* and *Ochis maculata* are used for their aphrodisiac activity [3]. Leaves of *Hibiscus macranthus* and *Basella alba* have androgenic property [4-5]. A recent review states that randomized clinical trials have shown that extracts of *Lepidium meyenii*, known commonly as maca, has favorable effects on energy and mood, may decrease anxiety and improve sexual desire [6]. Small-scale clinical trials performed in men have shown that extracts of maca can heighten libido and improve semen quality [7-8], improve sperm production, sperm

motility, and semen volume [6] and hence is used as an aphrodisiac.

Study of medicinal plants in order to develop a new fertility-enhancing drug is an attractive preposition. Similarly, in homeopathy a variety of plant, animal, mineral and even toxic substances in very small doses are used medicinally to stimulate the body's natural healing powers and to bring the body back into balance. Sometimes crude extracts (mother tinctures) are also used as medicine, which is termed as non-homeopathic use of the substance as is the case with Cantharis Q. It is a crude alcoholic extract of blister beetles called *Lytta vesicatoria*, commonly called blister beetle and popularly known as Spanish fly. Cantharis Q has been used non-homeopathically from ancient times as an aphrodisiac [9-10]. *Lytta vesicatoria* of Fabricius is a

beetle belonging to Phylum Arthropoda, Class Insecta, Order Coleoptera, Family Meloidae. These beetles carry a venomous substance diffused throughout their body, especially in their blood called cantharidin, a potent chemical that possesses caustic or blistering properties when the insects are accidentally crushed or handled roughly [11]. Alcoholic extract of *Lytta vesicatoria*, in homeopathy, is used in diluted potentized form for treatment of many disorders such as baldness, rheumatism, burning and cystitis, kidney and genital disorders [12]. At what period these beetles were introduced into the practice of medicine is a matter of uncertainty but find their most prominent sphere of action in exciting the animal passions. It leads to irritation, i.e. pains with burning due to vesication and produces unbounded sexual desire; also sexual erethism and excitability. Genito-urinary systems come under its sphere of action [13].

The toxic principle, cantharidin is an odourless, colourless compound that is soluble in various organic solvents but only slightly soluble in water. It is a bicyclic terpenoid having the molecular formula $C_{10}H_{12}O_4$ [14]. After ingestion, it is absorbed from the GI tract and is rapidly excreted by the kidneys. During excretion, it irritates the entire urinary tract. The irritation of the urethra increases the blood flow to this region and might result in priapism, a persistent abnormal erection of the penis. It is likely that the priapism is the origin of use of Spanish fly as an aphrodisiac [15]. The blister beetles have been reported to be consumed by humans for aphrodisiac purposes and there have been studies regarding the poisoning effect of this extract [16-17]. Lesions in the kidney and the efferent urinary tract have been reported in some cases where it was used as an aphrodisiac or to induce abortion. Though, Cantharis Q has a long history in both folk and traditional medicine and has been used since ages as a sexual stimulant and it has a wide spread reputation of being an aphrodisiac [18], the effect on the vital organ such as liver due to long term or short term use of this agent has not been investigated in the past by a systematic study using a model animal.

The objective of this research study was to carry out the primary assessment of the agent mainly through the biochemical markers and histopathological study of liver which could bring out the most relevant clinical features of the effect of this animal drug on this vital organ of rat. Hence, through this research study there is an attempt to confirm the potential clinical application of this agent and also the reversal of the effect, if any, after withdrawing the drug treatment.

MATERIAL AND METHODS

Ethics

All the experimental animals were procured from the Haffkine Biopharma. Corpn. Ltd., (A Govt. of Maharashtra undertaking), Parel, Mumbai – 400 012.

The animals were kept under the standard laboratory conditions as per the CPCSEA guidelines at the Animal Testing Centre of Ruia College, Matunga, Mumbai, Registration Number 315/CPCSEA.

Drug / study agent

Crude alcoholic extract (mother tincture) of *Lytta vesicatoria* manufactured by Sarada Homeo Laboratory (SHL), Kolkatta – 700 015 is available in the market as Cantharis Q. Drug from one batch was used throughout the experiment.

Animals and treatment

Thirty male adult albino rats (*Rattus norvegicus albinus*) – Wistar strain of body weight about 200-250 g were kept under standard laboratory conditions with a 12-h light-dark cycle. Regular rat food and water was provided *ad libitum*. The animals were acclimated for a week. After acclimation, the animals were divided into three groups of five animals each as Group I, II and III as experimental animals for 15, 60 days of treatment followed by recovery for 30 days. Corresponding groups of control animals were kept for all these durations. Experimental animals of group I, II and III were orally administered the drug at the dosage of 500 µg/kg body weight of the animals, diluted in 1 mL of distilled water as a single dose per day using GI gavage for the specified period. Control animals were orally administered 1 mL of distilled water, as a single dose per day. Group III animals of 60 days duration treatment were then kept for 30 days without any treatment in order to assess the reversibility of the drug effect.

Biochemical analysis

Sets of control and experimental animals were sacrificed using anaesthetic ether. Liver was excised from each of the dissected animals. It was cleaned in cold normal saline, blotted and immediately weighed and stored at -20°C for further biochemical analysis. From each of the liver samples, 40% tissue homogenate was made in cold distilled water using Remi Tissue Homogenizer. Different dilutions of this homogenate were used as per the different standardized biochemical methods. Biochemical assays of enzyme activities and that of metabolic parameters were carried out using Diagnostic Reagent Kit from Span Diagnostic Extraction and of DNA and RNA was done as per modified method of [19] using refrigerated centrifuge Rota – 4, Plastocraft Ltd. Chemicals of AR grade were purchased from SISCO Research Laboratories Pvt. Ltd. and Qualigens Ltd. All the colorimetric readings were taken on Systronics UV-Visible Spectrophotometer.

Histopathological analysis

After sacrificing the animal, one of the liver lobes of each animal was fixed in alcoholic Bouin's fixative for at least 24 hours for histological studies. They were washed with several changes of 70% alcohol to remove

Table 1. Effect on liver enzymes activity and liver metabolic parameters of male albino rat after 15, 60 days treatment and 30 days recovery after 60 days treatment with Cantharis Q

Parameter Assayed /gm of liver	Duration of oral intake of Cantharis Q					
	15 days Control	15 days Treated	60 days Control	60 days Treated	30 days recovery Control	30 days recovery Treated
Acid Phosphatase (IU/gm)	2.056± 0.300	0.98± 0.110*	2.196± 0.065	1.482± 0.119*	2.158± 0.193	2.34± 0.155
Alkaline Phosphatase (IU/gm)	0.13± 0.029	0.126± 0.006	0.178± 0.023	0.082± 0.008*	0.182± 0.008	0.166± 0.006
Glycogen (mg/gm)	13.71± 1.5	13.988± 2.125	14.058± 1.734	11.002± 0.853*	14.752± 1.247	11.66± 0.821*
Cholesterol (mg /gm)	6.338± 0.199	6.545± 0.375	7.29± 0.369	10.78± 0.977*	6.92± 0.107	10.157± 0.104*
Total Protein (mg /gm)	65.212± 3.159	73.212± 2.324*	74.466± 2.490	64.07± 3.580*	72.412± 1.948	77.77± 1.477*
DNA (mg/gm)	1.836± 0.175	2.052± 0.148	1.744± 0.287	1.586± 0.285	1.722± 0.269	1.792± 0.241
RNA (mg/gm)	1.67± 0.135	3.408± 0.375*	1.784± 0.323	1.406± 0.098*	1.784± 0.323	3.08± 0.071*

The number of animals in each group, n = 5. Values are expressed as Mean ± SD. Differences that are significant between the respective control and experimental groups at $p < 0.05$ are marked as *

excess of fixative. They were then dehydrated in ethyl alcohol gradients. The dehydrated tissues were cleared in chloroform and embedded in paraffin block. Sections of 7 µm thicknesses were taken on microtome (manufactured by Panchal Scientific, India). Sections were mounted on clean glass slides with a small amount of Mayer's albumin serving as an adhesive. The staining was done with hematoxylin and eosin [20] after rehydration through alcohol grades. Sections were covered with cover slip using DPX mountant. Photographs were taken using Olympus CH20i microscope with digital imaging facility.

Statistical analysis

All the data of biochemical analysis were expressed as Mean ± SD. Statistical analysis was done using two - way analysis of variance (ANOVA) followed by Dunnett's *post hoc* test. Differences at $p < 0.05$ were considered significant.

RESULTS

Effect on activity of liver marker enzymes

As depicted in Table 1, in case of 15 day-treated rats with 500 µg/kg body weight Cantharis Q, acid phosphatase decreased significantly while slight decrease was observed in the activity of alkaline phosphatase. There was a significant decrease in the activity of both the hepatic marker enzymes for 60 days treatment. However, the activities of both enzymes did not fluctuate significantly as those of their control counterparts in case of recovery animals.

Effect on liver metabolic parameters

Table 1 shows that for 15 days treatment with 500 µg/kg body weight Cantharis Q, the metabolic parameters namely cholesterol and glycogen increased

insignificantly; as was the case with DNA. However, total protein content and RNA of liver increased significantly. The chronic treatment of 60 days resulted in maximum alterations in various biochemical parameters. The cholesterol content was significantly higher than the normal controls whereas the glycogen content was significantly depleted. Even, the total protein and RNA level of liver was diminished remarkably in comparison with the control group. However, DNA content of the treated animals' liver decreased only slightly i.e. insignificantly as that of their controls. Chronically-treated rats that were kept for the recovery period of 30 days showed fluctuations in the liver biochemical parameters like cholesterol, RNA and total protein which were significantly increased whereas, the glycogen content significantly decreased. Activities of both hepatic marker enzymes as well as the DNA content were at par with those of their control counterparts. The changes in the biochemical parameters did not indicate significant recovery.

Effect on liver histology

As depicted in Fig 1, 500 µg/kg body weight Cantharis Q treatment of 15 days resulted in damage to the liver parenchyma of midzonal area. A ballooning degeneration of hepatocytes was noticed in form of vacuolation with fat droplets. A lot of congestion was observed in the portal triad showing cellular inflammation which was also observed in the periportal area.

Fig 2 shows that histopathology of chronically treated rat livers depicted the picture like that of the acute hepatitis. There was chronic inflammatory infiltration of portal triad with lymphocytes and plasma cells. Injury was also seen in the centrilobular area showing vacuolation and loss of hepatocytes. The damage was also extended to the midzonal area with the loss of hepatic cytoarchitecture. Histological studies also gave similar observations in case of recovery rats

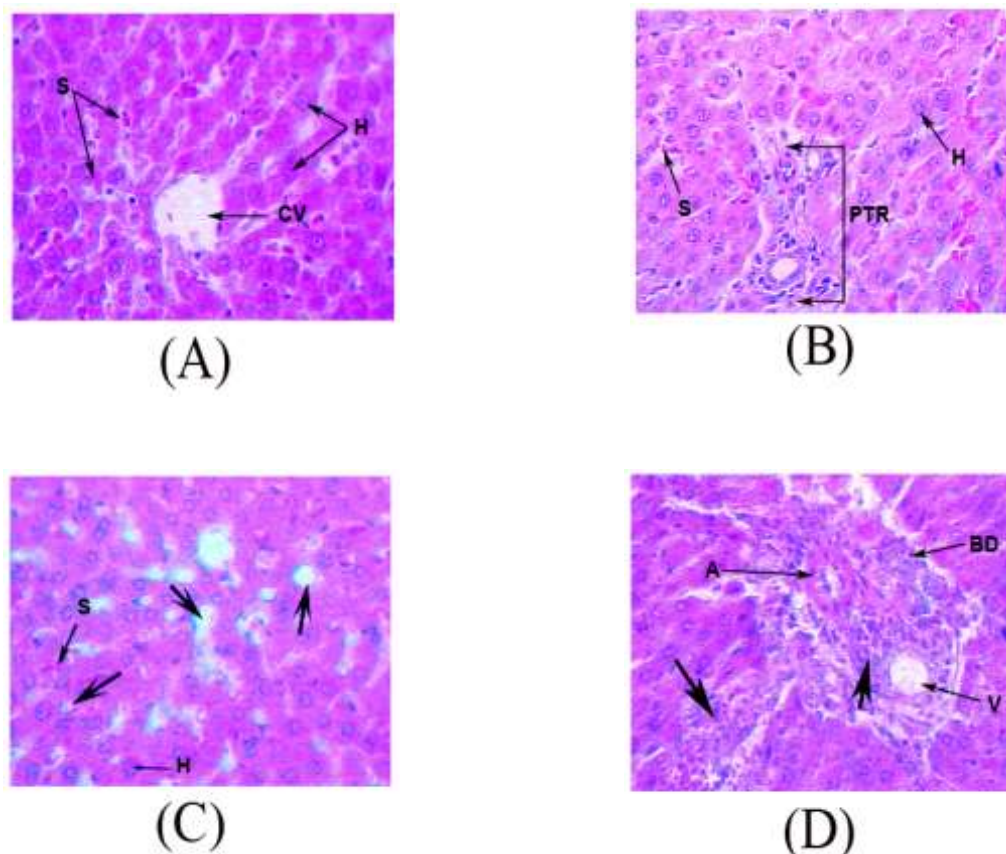


Fig 1. T. S. of liver of 15 days treated rats showing histopathological changes. Control rat showing (A) normal hepatic architecture of the centrilobular area and the midzonal area and (B) normal structure of the portal triad area and the periportal area (400 \times). (C) Experimental rat showing degenerative patches marked by the thick arrows (400 \times). (D) Experimental rat showing inflammation of the portal triad as well as the periportal area as shown by the thick arrows (400 \times).

H- normal hepatocytes, S- sinusoids, CV-centrilobular vein, PTR- portal triad, BD- bile duct, A- branch of the hepatic artery, V- branch of the portal vein.

where infiltration of lymphocytes and plasma cells was seen as intense as in the chronically treated group. However, midzonal area appeared to be normal with slight damage still persistent in the centrilobular area (Fig 2). Hence, the damage to the portal triad was not significantly recovered.

Fig 3 shows that there was a significant decrease in the weight of liver for treated animals of 15 and 30 days recovery. A significant increase was observed for the 60 days duration of treatment.

DISCUSSION

Biochemical and histopathological changes in the tissues affect the overall weight of that organ. Chronic treatment of 60 days with Cantharis Q resulted in a significant increase in the weight of liver which corroborates with other reports based on chronic toxicity studies [21-22]. Acid phosphatase (E.C 3.1.3.2) and Alkaline phosphatase (E.C 3.1.3.1) are said to be the marker enzymes of liver indicating its various

pathological conditions. Decrease in liver acid phosphatase enzyme activity, as was observed in the present study, has been reported in many hepatotoxicity studies which were accompanied with detrimental histopathological changes [23-26]. Similar research studies have reported lowered liver alkaline phosphatase activity in rats associated with damage to liver by hepatotoxins [24,27-28] thus confirming impairment in liver physiology. It could be inferred that short- as well as long-term treatment with Cantharis Q affected the liver which is further supported by the histological studies that revealed damage to the hepatocytes which probably lowered the phosphatase activities in liver.

Liver plays an important role in the metabolism of carbohydrates, lipids and proteins. Glycogen synthesis and degradation are coordinated by several amplifying reaction cascades. Protein phosphatase 1 (PP1) accelerates glycogen synthesis and hence decreases the rate of glycogen breakdown [29] Cantharidin, the main component of Cantharis Q, is a strong inhibitor of the activity of serine / threonine PP1 and PP2A. [30-35]. This inhibitory effect of Cantharis Q on PP1 has been

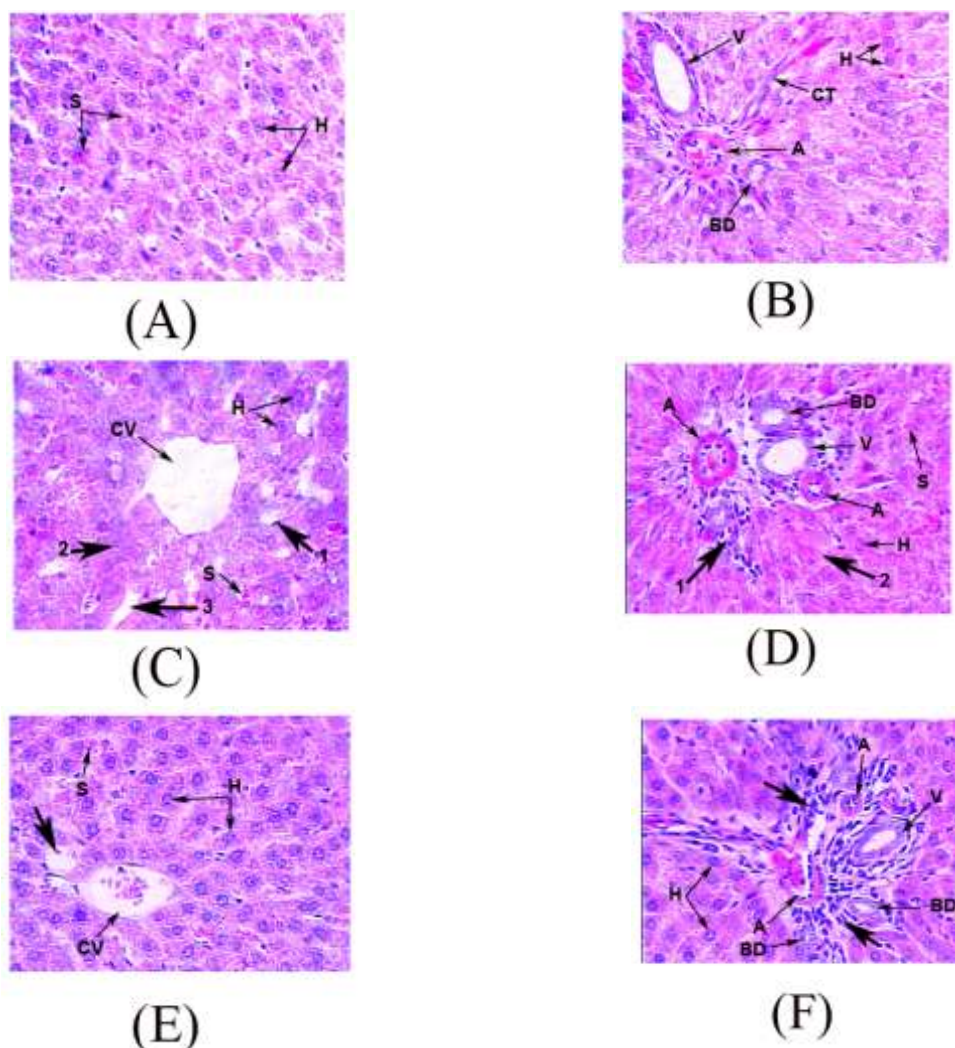


Fig 2. T. S. of liver of 60 days treated and recovery rats showing histopathological changes. Control rat showing (A) normal hepatic structure of the midzonal area and (B) normal structure of the portal triad area with normal hepatocytes, the sinusoids and the collagenous tissue. (400 \times). (C) Experimental rat of recovery group showing centrilobular area. Thick arrow 1- degenerated vacuolated hepatocytes Thick arrow 2- loss of hepatocytic architecture, Thick arrow 3 – dilated sinusoid, (D) 60 days experimental rat. Thick arrow 1- portal triad area with inflammatory cellular infiltrate. Thick arrow 2 - periportal area with degenerating hepatocytes lacking nuclei. (E) Experimental rat of the recovery group showing normal hepatic architecture of the centrilobular and the midzonal area except for a few patches having vacuolation marked by Thick arrow. (F) Experimental rat of the recovery group showing infiltration of the portal triad area by lymphocytes and plasma cells marked by Thick arrows.

H- normal hepatocyte, S- sinusoid, BD- bile duct, CT- collagenous tissue, A- branch of the hepatic artery, V- branch of the portal vein, CV- centrilobular vein

reflected in the chronically treated rats for 60 days as well as the recovery group where a significant decrease in glycogen content of liver was reported in the present study. PP2A plays an important role in fatty acid metabolism [29]. Cantharidin which is a potent inhibitor of PP2A, therefore, most probably interferes with fatty acid metabolism thus having its negative impact on liver lipid metabolism. Cantharidin decreases LH induced StAR protein levels [33, 36] due to which transport of cholesterol to its site for steroid synthesis is in turn impaired. Thus there was an increased accumulation of cholesterol in hepatocytes there by increasing the liver cholesterol content. This was also seen in the light microscopic histology studies of the liver sections of the treated rats where ballooning of hepatocytes due to fat accumulation was revealed. Further, this could also

result in the impaired steroid synthesis that could in turn affect the normal spermatogenesis process.

Various hepatotoxicity studies like effect of beryllium [37], ethanolic extract of *Crotalaria juncea* (Leguminosae) seeds [38] and CCl_4 treatment [39] have reported significantly decreased glycogen content in liver of such treated albino rats. Histological damages have also been reported in such treatments. Cholesterol is reported to accumulate at higher levels than normal in liver during hepatic malfunctioning [22, 28, 40]. Nature of fluctuations of protein levels may vary as per the toxicant or drug under study and also the dosage; though decrease rather than increase in liver protein levels is more often seen in such hepatic damage studies [38, 41-45].

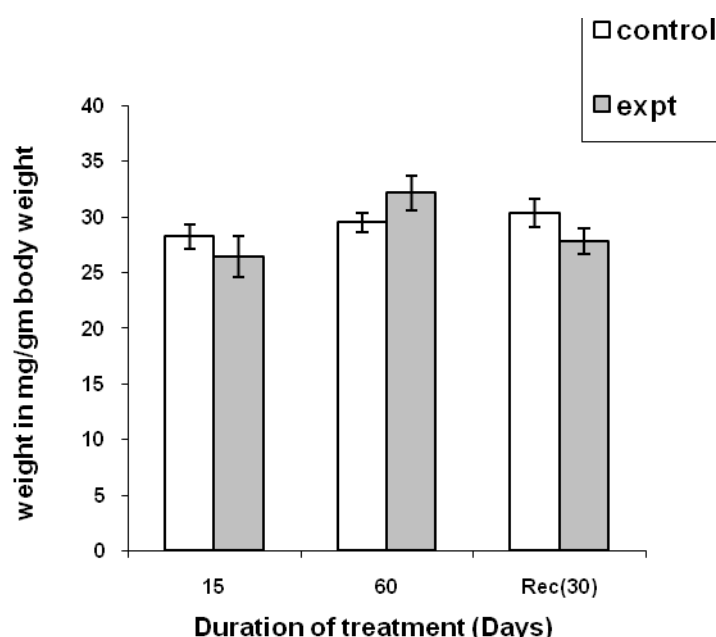


Fig 3. Effect on weight of liver (mg /gm body weight) in control and experimental male albino rats after 15, 30, 60 days treatment and 30 days recovery after 60 days treatment.

The number of animals in each group, $n =$ five, values are expressed as Mean \pm SD. Significant differences between the respective control and experimental groups at $p < 0.05$ are marked as*

The present study with Cantharis Q also reported alterations such as significant increase in protein for 15 days as well as recovery period and decrease for 60 days, it being significant only for the latter. The initial increase in protein could be due to decreased catabolism of protein by hepatocytes due to their damage as reported in the histological observations. However, as the treatment progressed, probably there was an inhibition of protein synthesis. This is in accordance the role of cantharidin as PP1 and PP2A inhibitors.

Histological analysis of the present study indicated damage to the hepatic architecture which also explains the significant alterations in hepatic protein metabolism. Thus, in present study, initial increase in the liver proteins could probably be attributed to decreased catabolism of protein rather than increase in protein synthesis because Cantharis Q is a known inhibitor of protein synthesis. As the treatment progressed, Cantharis Q exerted its inhibitory influence on protein synthesis as was seen in results of 60 days treatment. Recovery animals showed the effect similar to that of 15-day treated which could be due to withdrawal of long term treatment. However, significant alterations in liver histology continued with respect to their controls, which therefore did not indicate a good deal of recovery. Protein synthesis is mediated by the coordinated interplay of DNA and RNA, liver DNA and RNA assays are important. Changes in RNA indicate toxicant-induced changes in protein synthesis [46].

Cell division, cell repair mechanisms could also be influenced especially by DNA synthesis [29]. The

trends observed in fluctuations of DNA and RNA levels could be quite different in various studies when related with liver protein content as reported in various hepatotoxic studies [42, 47-50]. This could be due to the much complicated mechanisms involved in nucleic acid and protein metabolism. In the present study, increased DNA as well as RNA levels in liver of 15-day treated animals was probably due to decreased catabolism of nucleic acids as in the case with the associated protein metabolism where protein degradation was affected. This could be corroborated with the hepatotoxic study results of [43]. The recovery animals showed a marginal increase in DNA levels and a significant increase in RNA and protein levels. This result could be due to the stopping of treatment of Cantharis Q since increase in DNA and RNA levels also indicate tissue rejuvenation [45] This may hold good as Cantharis Q is known to be an anti-proliferative agent where it affects the cell cycle and DNA synthesis by alternating the dephosphorylation of extra cellular regulated kinases 1 and 2 [35]. The activity of these kinases is switched on by the serine-threonine specific phosphatase which then initiates mitosis [29]. As mentioned earlier, Cantharis Q has been known to be the inhibitor of such protein phosphatases thereby affecting cell repair mechanism. Withdrawal of the treatment of the Cantharis Q could slightly alleviate this effect. However, histological analysis did not indicate a total recovery of normal hepatic architecture. Hence, damage caused by the chronic treatment with cantharis Q might be an irreparable damage to certain hepatic areas like

periportal and portal triad as in case of chronic type of hepatic damage, there is a cellular inflammation of the portal tract which may also extend into the parenchyma; the portal triads show a conspicuous infiltration with the lymphocytes and plasma cells and the lobular architecture is disturbed [51]. Various toxicological studies have shown such histopathological changes associated with the biochemical changes in the liver [21, 22, 38, 40, 52-54].

Thus, in the present research study, there was an attempt to comprehensively evaluate the function and physiology of the treated animals through biochemical and histological investigations of liver which is the largest gland that performs many important functions. It is probable from the above references and the results of the present study on Cantharis Q that hepatic damages essentially altered the biochemical status of the organ. The damage had been proportional to the duration of the treatment. The recovery animals of the treated group also did not show improvement of the lesions reported for the chronic treatment. Hence, it could be said that withdrawal of the treatment for a period of 30 days did not lead to a significant recovery. These findings could help in establishing the clinical potential of this animal drug.

ACKNOWLEDGEMENT

We would like to thank Dr. RT Sane, Former Principal of R. Ruia College, Mumbai for granting the facility of the CPCSEA registered Animal House of this institution. We are grateful to The University Grants Commission for awarding the financial grant through fellowship. We acknowledge Dr. CV Rao, Former Head of Zoology Department, St. Xavier's College, Mumbai for his valuable guidance in liver histopathological studies.

REFERENCES

- Kamtchouing P, Mbongue GY, Dimo T, Watcho P, Jatsa HB, Sokeng SD. Effects of *Aframomum melegueta* and *Piper guineense* on sexual behaviour of male rats. *Behav Pharmacol* 2002; 13: 243-7.
- Mbongue GY, Kamtchouing P, Essame OJL, Yewah PM, Dimo T, LontsiDimo D. Effect of the aqueous extracts of dry fruits of *Piper guineense* on the reproductive function of adult male rats. *Indian J Pharmacol* 2005; 37: 30-2.
- Ageel MA, Islam MW, Ginawi OT, et al. Evaluation of the aphrodisiac activity of *Litsea chinensis* (Lauraceae) and *Orchis maculata* (Orchidaceae) extracts in rats. *Phytoether Res* 1994; 8:103-5.
- Moundipa FP, Kamtchouing P, Koueta N, Tantchou J, Foyang NP, Mbiapo FT. Effects of aqueous extracts of *Hibiscus macranthus* and *Basella alba* in mature rat testis function. *J Ethnopharmacol* 1999; 65:133-9.
- Moundipa PF, Ngouela S, Kamtchouing P, Tsamo E, Tchouanguep FM, Carreau S. Effects of extracts from *Hibiscus macranthus* and *Basella alba* mixture on testosterone production *in vitro* in adult rat testes slices. *Asian J Androl* 2006; 8:111-4.
- Gonzales GF, Gonzales C, Gonzales-Castañeda C. *Lepidium meyenii* (Maca): a plant from the highlands of Peru--from tradition to science. *Forsch Komplementmed* 2009; 16:373-80.
- Gonzales GF, Cordova A, Gonzales C, Chung A, Vega K, Villena A. *Lepidium meyenii* (maca) improved semen parameters in adult men. *Asian J Androl* 2001; 3:301-3.
- Gonzales GF, Córdoba A, Vega K, Chung A, Villena A, Góñez C, Castillo S. Effect of *Lepidium meyenii* (maca) on sexual desire and its absent relationship with serum testosterone levels in adult healthy men. *Andrologia* 2002; 34: 367-72.
- Sandroni P. Aphrodisiacs past and present: a historical review. *Clin Auton Res* 2001; 11:303-7.
- Karras DJ, Farrell SE, Harrigan RA, Henretig FM, Gealt L. Poisoning from 'Spanish fly' (Cantharidin). *Am J Emerg Med* 1996; 14:478-83.
- Aiello SE. In: The Merck Veterinary Manual. 8th ed. Merck and Co. Inc., 1998. pp. 2028-2029.
- Ellingwood F. In: The American Materia Medica, *Therapeutics and Pharmacognosy* 1919. pp 191.
- Clarke JH. In: A Dictionary of Practical Materia Medica, presented by Medi-T. 2000.
- Davidson, Ralph IL, William F. In: Insect Pests of Farm, Garden and Orchard. John Wiley and Sons, Inc. NY. 1987.
- Metcalf CL, Flint WP. In: Destructive and Useful Insects. McGraw- Hill Book Co. NY. 1962.
- Marcovigi P, Leoni S, Calbi G, Valtancoli E, Ravaglia G. Acute poisoning caused by cantharidin ingestion for aphrodisiac purposes. A clinical case. *Minerva Anestesiol* 1995; 61:105-7.
- Polettini A, Crippa O, Ravagli A, Saragoni A. A fatal case of poisoning with cantharidin. *Forensic Sci Int* 1992; 56:37-43.
- Moed L, Shwayder TA, Chang MW. A blistering defence of an ancient medicine. *Arch. Dermatol* 2001; 137:1357-60.
- Munro HN, Fleck A. In: Methods of Biochemical Analysis, Vol. 14. Edited by Glick. D. Interscience, NY. 1967; pp 113
- McManus JFA, Mowry RW. 1964. In: Staining Methods: Histologic and Histochemical. 1st ed. Hoeber International Reprint, London and Tokyo.
- Choudhary N, Sharma M, Verma P, Joshi SC. Hepato and nephrotoxicity in rat exposed to endosulfan. *J Environ Biol* 2003; 24:305-8.
- Pereira C, Mapuskar K, Rao CV. Chronic toxicity of diethyl phthalate in male Wistar rats - A dose - response study. *Reg Toxicol and Pharmacol* 2006; 45:169-77.
- Sato R. Clinical and experimental histochemical studies on the activities of liver lysosomal enzymes and gamma-glutamyl transpeptidase (gamma-GTP). *Hokkaido Igaku Zasshi* 1978; 53: 287-303.
- Rao CV. PhD Thesis, Mumbai Univ. Polychlorinated biphenyls (PCBs) Residues in human systems and their effects on experimental animal model. 1987.
- Abraham P. Lysosomal enzyme activity during development of carbon tetrachloride induced cirrhosis in rats. *Indian J Physiol Pharmacol* 2004; 48:206-12.
- Rahman MF, Siddiqui MK. Biochemical effects of vepacide (from *Azadirachta indica*) on Wistar rats during sub chronic exposure. *Ecotoxicol Environ Saf* 2004; 59:332-9.
- El-Demerdash FM. Antioxidant effect of vitamin E and selenium on lipid peroxidation, enzyme activities and biochemical parameters in rats exposed to aluminium. *J Trace Elem Med Biol* 2004; 18:113-21.
- Singh VK, Dixit P, Saxena PN. Cybil induced hepatobiochemical changes in Wistar rats. *J Environ Biol* 2005; 26:725-7.
- Stryer L. In: Biochemistry 4th ed. W.H. Freeman and Co. NY. 1995.
- Honaken RE. Cantharidin, another natural toxin that inhibits the activity of serine/threonine protein phosphatases types 1 and 2A. *FEBS Lett* 1993; 330:283-6.
- Knapp J, Bokník P, Huke S, Gombosová I, Linck B, Lüss H, Müller FU, Müller T, Nacke P, Schmitz W, Vahlensieck U,

- Neumann J. Contractility and inhibition of protein phosphatases by cantharidin. *Gen Pharmacol* 1998; 31:729–33.
32. McCluskey A, Walkom C, Bowyer MC, Ackland SP, Gardiner E, Sakoff JA. Cantharimides: A new class of modified cantharidin analogues inhibiting protein phosphatases 1 and 2A. *Bioorg Med Chem Lett* 2001; 11:2941–6.
 33. Yu CC, Chen WY, Li PS. Protein phosphatase inhibitor cantharidin inhibits steroidogenesis and steroidogenic acute regulatory protein expression in cultured rat preovulatory follicles. *Life Sci* 2001; 70:57–72.
 34. Poderoso C, Paz C, Gorostizaga A, Cornejo Maciel F, Mendez CF, Podesta EJ. Protein serine / threonine phosphatase 2A activity is inhibited by cAMP in MA-10 cells. *Endocr Res* 2002; 28:319–23.
 35. Williams LA, Moller W, Merisor E, Kraus w, Rosner H. In vitro anti-proliferation / cytotoxic activity of cantharidin (Spanish Fly) and related derivatives. *West Indian Med J* 2003; 52:10–3.
 36. Clarke BJ, Stocco DM. Expression of the steroidogenic acute regulatory (StAR) protein: A novel LH – induced mitochondrial protein required for the acute regulation of steroidogenesis in mouse Leydig tumour cells. *Endocr Res* 1995; 21:243–57.
 37. Mathur R, Nirala SK, Mathur A. Comparative effectiveness of CaNa_2DTPA and tiron along with alpha-tocopherol against beryllium-induced biochemical alterations in rats. *Indian J Exp Biol* 2004; 42:570–4.
 38. Prakash AO, Dehadrai S, Jonathan S. Toxicological studies on the ethanolic extract of *Crotalaria juncea* seeds in rats. *J Ethnopharmacol* 1995; 45:167–76.
 39. Bhandarkar M, Khan A. Protective effect of *Lawsonia alba* Lam., against CCl_4 induced hepatic damage in albino rats. *Indian J Exp Biol* 2003; 41:85–7.
 40. Augusti KT, Anuradha, Prabha SP, Smitha KB, Sudheesh M, George A, Joseph MC. Neutraceutical effects of garlic oil, its nonpolar fraction and a *Ficus* flavanoid as compared to vitamin E in CCl_4 induced liver damage in rats. *Indian J Exp Biol* 2005; 43:437–44.
 41. Olagunju JA, Ogunfeibo AB, Ogunbosi AO, Taiwo OA. Biochemical changes elicited by isosaline leaf and stem-bark extracts of *Harungana madagascariensis* in the rat. *Phytother Res* 2004; 18:588–91.
 42. Das KK, Das SN. Studies on the role of ascorbic acid on nickel induced hepatic nucleic acids concentrations in rats. *J Basic Clin Physiol Pharmacol* 2004; 15:18–95.
 43. Dhar A, Banerjee PK. Impact of lead on nucleic acids and incorporation of labeled amino acids into protein. *Int J Vitam Nutr Res* 1983; 53:349–54.
 44. Shih CC, Wu YW, Lin WC. Aqueous extract of *Anoectochilus formosanus* attenuate hepatic fibrosis induced by carbon tetrachloride in rats. *Phytomedicine* 2005; 12:453–60.
 45. Shailajan S, Sane RT, Menon SK. Effect on *Ascarantha longifolia* Nees. against CCl_4 induced liver dysfunction. *Indian J Exp Biol* 2005; 43:445–9.
 46. Wallace HA. Principles and Methods of Toxicology. 2nd ed. Raven Press, NY. pp 599. 1989.
 47. de la Fuente M, Hernanz A, Alia M. Effect of semicarbazide on the perinatal development of the rat: changes in DNA, RNA and protein content. *Methods Find Exp Clin Pharmacol* 1983; 5:287–97.
 48. Bell AN, Mehendale HM. Comparative changes in hepatic DNA, RNA, protein, lipid, and glycogen induced by a subtoxic dose of CCl_4 in chlordecone, mirex and phenobarbital pretreated rats. *Toxicol Lett* 1987; 35:191–200.
 49. Ku WW, Shih LM, Chapin RE. The effects of boric acid (BA) on testicular cells in culture. *Reprod Toxicol* 1993; 7:321–31.
 50. Wong WS, McLean AE. Effects of phenolic antioxidants and flavanoids on DNA synthesis in rat liver, spleen and testis *in vitro*. *Toxicology* 1999; 139:243–53.
 51. Boyd. In: Textbook of Pathology: Structure and Function in Disease. 8th ed. Lea and Febiger – Philadelphia. 1965.
 52. Gathumbi PK, Mwangi JW, Mugeru GM, Njiro SM. Toxicity of chloroform extract of *Prunus africana* stem bark in rats: gross and histological lesions. *Phytother Res* 2002; 16:244–7.
 53. Satturwar PM, Fulzele SV, Joshi SB, Dorle AK. Hepatoprotective activity of Haridradi ghrita on carbon tetrachloride- induced liver damage in rats. *Indian J Exp Biol* 2003; 41:1447–51.
 54. Mapuskar K, Pereira C, Rao CV. Dose-dependant sub-chronic toxicity of diethyl phthalate in female Swiss mice. *Pesticide Biochem Physiol* 2007; 87:156–63.

CURRENT AUTHOR ADDRESSES

Roshan Clarence D'souza, Department of Zoology, B. N. Bandodkar College of Science, Thane-400 601, India. E-mail: roshandc@gmail.com (Corresponding author)

Raghunandan P. Athalye, Department of Zoology, B. N. Bandodkar College of Science, Thane-400 601, India.