

# Evaluation of The Effect of *Onosma bracteatum* Wall (Boraginaceae) on Bronchial Hyperreactivity in Sensitized Guinea Pigs

KALPANA GOVINDBHAI PATEL, KIRTI VINODRAI PATEL and TEJAL RICKY GANDHI

For author affiliations, see end of text.

Received December 10, 2007; Revised July 22, 2008; Accepted July 28, 2008

This paper is available online at <http://ijpt.iums.ac.ir>

## ABSTRACT

Asthma is a chronic inflammatory disorder of the airways. The available treatment options have major limitations owing to low efficacy, associated adverse events and compliance issues. Therefore, the health burden of bronchial asthma is increasing globally at an alarming rate, providing a strong impetus for the development of new therapeutics. *Onosma bracteatum* (*O. bracteatum*) is known traditionally in Ayurveda to possess anti-asthmatic activity. Hence, the present investigation was undertaken to evaluate the effect of aerial parts of *O. bracteatum* on bronchial hyperreactivity by various *in vivo* and *in vitro* experimental models. Experimental models studied were total and differential cell estimation in bronchoalveolar lavage fluid (BALF), estimation of histamine release from lungs, *in vitro* studies on tracheal strip and histopathological studies of egg albumin-sensitized guinea pigs. Treatment with ethanolic extract of *O. bracteatum* (5 mg/kg, p.o., for 15 days) significantly decreased the total and differential leukocyte count in bronchoalveolar lavage fluid (BALF), and also blocked histamine release from chopped lung tissues of sensitized guinea pigs. Ethanolic extract of *O. bracteatum* (5 mg/kg, p.o., for 15 days) prevented the potentiation of the responses of histamine and acetylcholine which resulted in a significant decrease in pD<sub>2</sub> value of histamine and acetylcholine in guinea pig tracheal strip. Histopathological changes induced by egg albumin were also significantly reduced by the treatment with ethanolic extract of *O. bracteatum* (5 mg/kg, p.o., for 15 days). These results suggest that *O. bracteatum* decreases bronchial hyperresponsiveness by decreasing the infiltration of inflammatory mediators like eosinophils, neutrophils in BALF, inhibiting histamine release from lungs of sensitized guinea pigs and by decreasing airway inflammation.

**Keywords:** Bronchial hyperreactivity, Bronchospasm, Inflammatory mediators, *Onosma bracteatum*, Boraginaceae

Asthma is a chronic disease characterized by inflammation of the airways that is central to the airway dysfunction. Typically, the airway wall is infiltrated by a variety of inflammatory cells such as eosinophils, mast cells, and CD4<sup>+</sup> T lymphocytes that release a plethora of mediators ultimately causing the symptoms and the histopathology of asthma. Bronchial hyperresponsiveness (BHR) is also a characteristic feature of most asthmatics which correlates with the severity of the disease; although its precise mechanism remains unclear.

The prevalence and severity of allergic asthma have been steadily increasing over the past 20 years together with the number of reported cases of fatal asthma, and it affects up to 10% of the population of most developed countries [1,2]. The disease statistics clearly necessitates the increasing need for drugs targeting the mechanisms

involved in eosinophil and neutrophil activation and accumulation, for the management of asthma. Glucocorticosteroids are the only drugs currently available that effectively reduce airway inflammation in asthma [3].

As a result there is high prevalence of usage of complementary and alternative medicines for treatment of this disease [4]. Ayurveda, an ancient system of Indian medicine, has recommended several drugs from indigenous plant sources for the treatment of bronchial asthma and allergic disorders [5]. One such plant is *O. bracteatum*, Wall (Family Boraginaceae, commonly known as Gaozaban, Gojihva) which has been reported to be used in the treatment of asthma and bronchitis [6, 7]. Aerial parts of *O. bracteatum* are prescribed by many Ayurvedic practitioners in bronchial asthmatic patients. However, no scientific studies are so far carried out to investigate the antiasthmatic activity of *O. bracteatum*.

**Table 1.** Effect of ethanolic extract of *O. bracteatum* on change in histamine levels of lung due to egg albumin induced histamine release in guinea pigs

TREATMENT	HISTAMINE LEVEL IN LUNGS (ng/g)
Control	295±1.071
Sensitized (SEN)	412.5±5.663*
SEN+ <i>O. bracteatum</i>	310±1.044@**

Values are mean ± SEM, n=6 in each group

Significantly different from control group \*  $p < 0.001$ , \*\*  $p < 0.05$

Significantly different from sensitized group @  $p < 0.001$

The present study hence was undertaken to investigate the pharmacological activity of *O. bracteatum* using various invivo and invitro methods.

## MATERIALS AND METHODS

### Plant

Aerial parts of *O. bracteatum* were obtained from commercial supplier of Ahmedabad. The plant was identified and authenticated by Dr. Minoo Parabia, Head and Professor, Department of Bioscience, Veer Narmad South Gujarat University, Surat, Gujarat. A voucher specimen of plant was deposited in the herbarium of the Department of Bioscience, Veer Narmad South Gujarat University, Surat, Gujarat.

### Preparation of the plant extract

The aerial parts reduced to coarse powder were macerated with ethanol for 48 hrs, filtered and filtrate was evaporated under reduced pressure to obtain dry extract. The extract was stored in cool and dry place and used for pharmacological evaluation. (ethanolic extractive value 1 %w/w).

### Animals

Hartley strain guinea pigs (350-500 gm) of either sex housed in standard conditions of temperature ( $22 \pm 2^\circ \text{C}$ ), relative humidity ( $55 \pm 5\%$ ) and light (12 hrs light/dark cycles) were used. Guinea pigs were fed with green vegetables. Animal studies were approved by the Institutional Animal Ethics Committee (Protocol no. 6012 passed on 19/12/2006) according to the regulations of Committee for the Purpose of Control and Supervision of Experiments on Animals (CPCSEA).

### Study design for assessment of bronchial hyperre-activity

Egg albumin sensitized guinea pigs were challenged by exposure to same antigen and following parameters were evaluated for assessment of bronchial hyperre-activity: A) cell populations in BALF, B) histamine estimation in the lung tissues, C) histopathological changes in lung tissue, D) potentiation of histamine and acetylcholine response in trachea.

### Sensitization, challenge protocols and treatment

The animals were randomly divided into three groups of six animals each i.e. group-I (control), group-II (sensitized), group-III (sensitized+treatment) for all above studies. The animals of group II and group III were sensitized with egg albumin (1 ml, 10% w/v, i.p.) in saline on the first day. The animals of group I received 0.5% CMC for fifteen days. The animals of group III were dosed with ethanolic extract of *O. bracteatum* (5 mg/kg, p.o., for 15 days, once daily) suspended in 0.5 % CMC. Fifteen days later, all animals were challenged with egg albumin (0.5 ml, 2% w/v) through saphenous vein. Animals exhibited labored breathing, lacrimation and coughing. Animals which did not respond were excluded from the study. After 3 hours of the challenge of the egg albumin or just prior to death of animals, which ever was earlier, the animals were anaesthetized with diazepam (8 mg/kg, i.p.) and ketamine (5 mg/kg, i.p.).

### A. Bronchoalveolar Cell Counts and Differentiation [8]

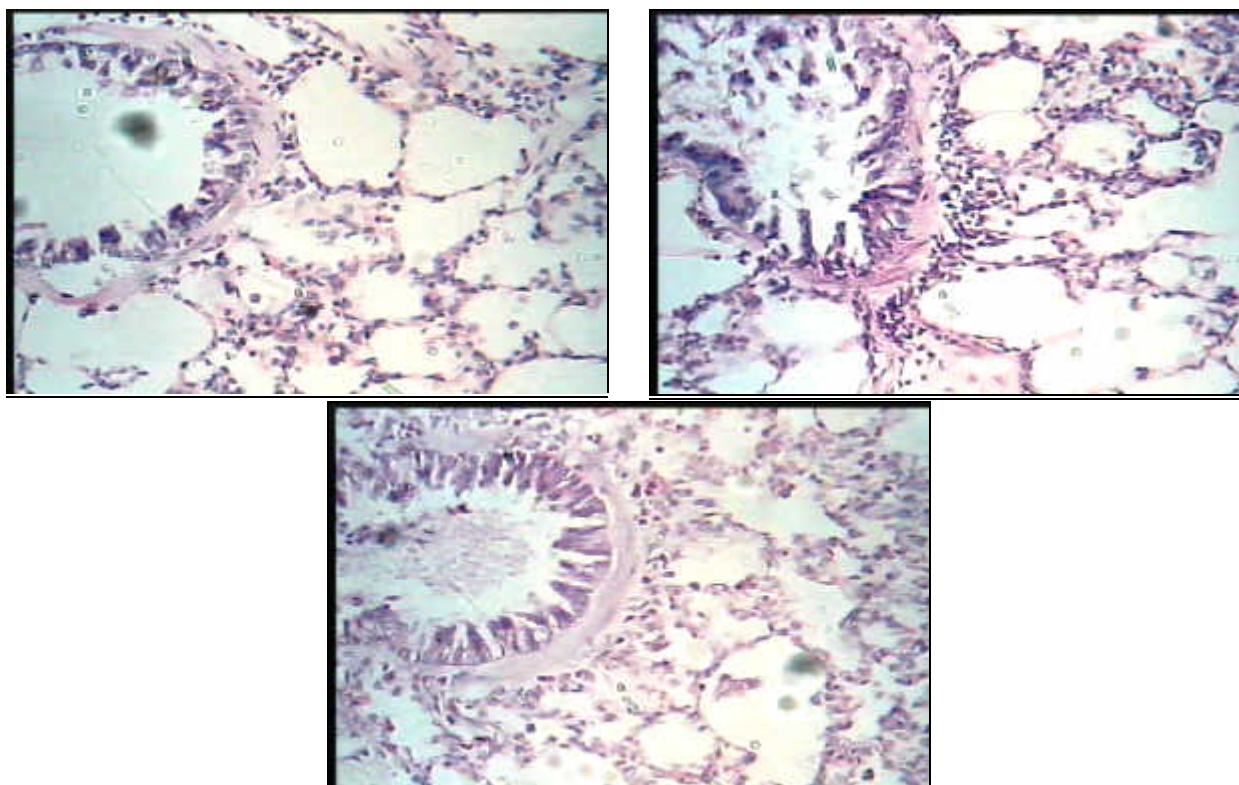
The trachea was immediately cannulated after anaesthetization and the airways lavaged with saline at  $25^\circ \text{C}$  (two aliquots of 1 mL/100 g body weight). Bronchoalveolar cells were collected in two successive lavages using saline and recovered through a tracheal cannula. The bronchoalveolar lavage fluid (BALF) was stored on ice and total WBC cell counts were performed using an automated cell counter (Cell Dyn 3200SL). Dilutions of lavage fluid (1 in 10) were made in saline, and differential WBC were counted by light microscopy stained with Leishman's stain. At least 200 cells were counted on each slide. Cells were differentiated using standard morphological criteria. All differential cell counts were performed blind and in randomized order at the end of the study.

### B. Study of histamine release from the lung tissues [9]

The lungs of the guinea pigs were chopped into fragments. The chopped lung tissues were placed in tubes with 2 ml of ice cold calcium free Tyrodes solution and kept on ice until further used. 200 mg (wet weight) of lung tissues were incubated with 1.8 mM  $\text{CaCl}_2$  for 10 min. at  $37^\circ \text{C}$ . The lung tissues were further incubated with 2 mg/ml egg albumin for 15 min. at  $37^\circ \text{C}$ . After 15 min., the reaction was stopped by filtration through nylon mesh (100  $\mu\text{m}$ ). Histamine in the solution was measured spectrofluorometrically by using o-phthalaldehyde as a substrate (Shimadzu Spectrophotofluorometer RF 5401) [10].

### C. Histopathological study

To avoid possible traumatic damage due to BAL, histopathological assessment of inflammatory changes in lung tissue were made in separate animals. The lungs were removed intact from all the three groups and then fixed by slowly inflating with buffered formalin and subsequently embedded in paraffin. A transverse section



**Fig 1.** Light micrographs of bronchiolar tissue from guinea pigs of the different experimental groups. A- Control group, B- Sensitized group and C- Sensitized + treated group (Magnification 40X)

(2–4  $\mu\text{m}$  thick) was cut from each sample and stained with haematoxylin and eosin. Histopathological assessment (light microscopy) was performed blind on randomized sections.

#### *D. Invitro studies on isolated guinea pig tracheal chain [11]*

Group I, II and III animals were stunned by a sharp blow on the head and sacrificed by cutting neck blood vessels. The trachea was rapidly dissected free of surrounding tissues and placed in Petri dish containing oxygenated Krebs-Henseleit solution (NaCl, 114.0 mM;  $\text{CaCl}_2$ , 2.5 mM; KCl, 4.7 mM; glucose, 11.7 mM;  $\text{NaHCO}_3$ , 25 mM;  $\text{MgCl}_2$ , 1.2 mM;  $\text{KH}_2\text{PO}_4$ , 1.2 mM). Tracheal strips were prepared by cutting the trachea spirally. Tracheal strip was suspended in organ tube containing Krebs-Henseleit solution at  $37 \pm 1^\circ\text{C}$  under a uniform tension of 1.5 g, continuously bubbled with 95%  $\text{O}_2$  and 5%  $\text{CO}_2$ . After an initial equilibration period of 90 min., the responses of the trachea to histamine and acetylcholine were recorded on a student physiograph (Bio Devices) using isotonic transducer.

#### *Statistical analysis*

The results of various studies were expressed as mean  $\pm$  SEM and analyzed statistically using one way ANOVA to find out the level of significance. Data were considered statistically significant at  $p < 0.05$ .

## RESULTS

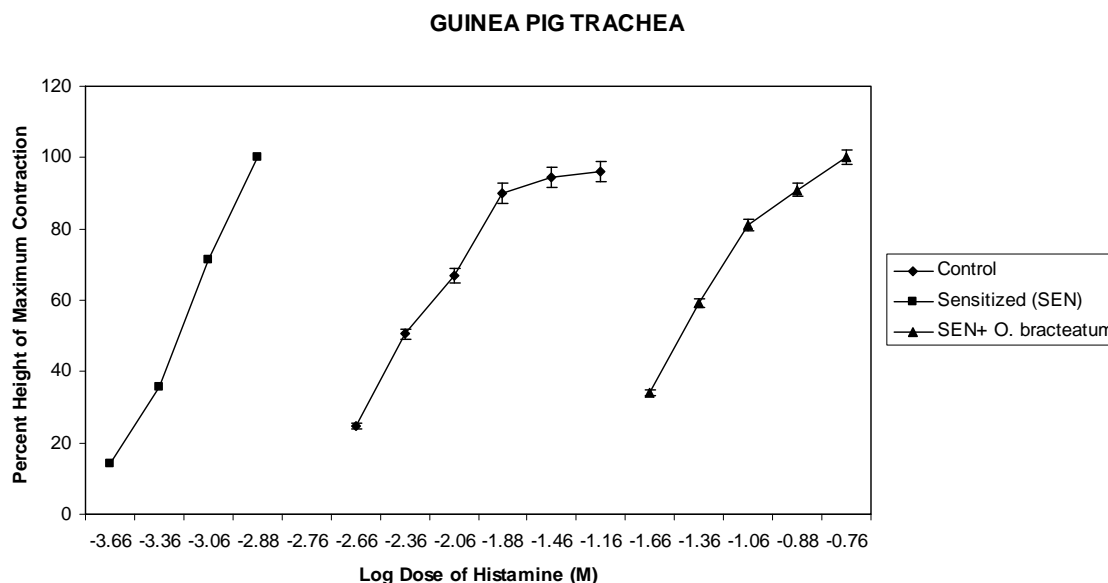
All guinea-pigs used in this study exhibited a marked reaction when challenged with antigen (egg albumin) characterized by acute dyspnoea.

#### *A. WBC cells recovered from BALF*

**Total cells** In sensitized guinea-pigs, the total number of cells ( $9500 \pm 483$  cells/mL) ( $n=6$ ) recovered in BALF was found to be significantly greater ( $p < 0.001$ ) as compared to controls ( $5500 \pm 330.7$  cells/mL) ( $n=6$ ). Treatment of sensitized guinea pigs with ethanolic extract of *O. bracteatum* (5 mg/kg, p.o., for 15 days) significantly prevented ( $p < 0.01$ ) the rise in total cell numbers in the BALF ( $6783.3 \pm 489.5$  cells/mL) ( $n=6$ ).

**Eosinophils** The number of eosinophils ( $269 \pm 32.15$  cells/mL) ( $n=6$ ) recovered in BALF from sensitized guinea-pigs was found to be significantly greater ( $p < 0.01$ ) as compared to controls ( $148.2 \pm 16.29$  cells/mL) ( $n=6$ ). Treatment of sensitized guinea pigs with ethanolic extract of *O. bracteatum* (5 mg/kg, p.o., for 15 days) was followed by a significant decrease ( $p < 0.05$ ) in the number of eosinophils in the BALF ( $192.2 \pm 10.04$  cells/mL) ( $n=6$ ).

**Neutrophils** A significant increase ( $p < 0.001$ ) in the neutrophil numbers ( $7073 \pm 464.7$  cells/mL) ( $n=6$ ) was observed in the BALF from antigen-challenged guinea pigs, as compared with controls ( $3416.7 \pm 366.8$  cells/mL) ( $n=6$ ). Treatment of sensitized guinea pigs with ethanolic extract of *O. bracteatum* (5 mg/kg, p.o.,



**Fig 2.** Effect of ethanolic extract of *O. bracteatum* on histamine induced contractions in tracheal strip preparation of guinea pigs

Each point represents Mean  $\pm$  SEM of 6 experiments

for 15 days) significantly inhibited the increase in ( $p < 0.01$ ) neutrophil numbers in the BALF ( $4398.3 \pm 568.9$  cells/mL) ( $n=6$ ).

**Monocytes** The total number of monocytes recovered in BALF from sensitized guinea-pigs was  $161 \pm 22.58$  cells/mL ( $n=6$ ), which was found to be significantly greater ( $p < 0.05$ ) as compared to controls ( $95.8 \pm 17.14$  cells/mL) ( $n=6$ ). Ethanolic extract of *O. bracteatum* (5 mg/kg, p.o., for 15 days) significantly inhibited ( $p < 0.05$ ) monocytes numbers in the BALF ( $103.5 \pm 12.11$  cells/mL) ( $n=6$ ).

**Lymphocytes** In sensitized guinea-pigs, the number of lymphocytes in BALF was  $2030.8 \pm 56.3$  cells/mL ( $n=6$ ), which was significantly greater ( $p < 0.01$ ) as compared to control ( $1746 \pm 39.9$  cells/mL) ( $n=6$ ). There was no significant change in lymphocyte numbers ( $1999 \pm 151.7$  cells/mL) ( $n=6$ ) in the BALF recovered from sensitized guinea pigs treated with ethanolic extract of *O. bracteatum* (5 mg/kg, p.o., for 15 days).

#### B. Effect on antigen induced histamine release from lung tissue of guinea pigs

There was highly significant ( $p < 0.001$ ) increase in the histamine release in the lungs of sensitized group as compared to control group. Treatment with ethanolic extract of *O. bracteatum* (5 mg/kg, p.o., for 15 days) produced a highly significant ( $p < 0.001$ ) decrease in the release of histamine as compared to sensitized group (Table 1).

#### C. Lung histology

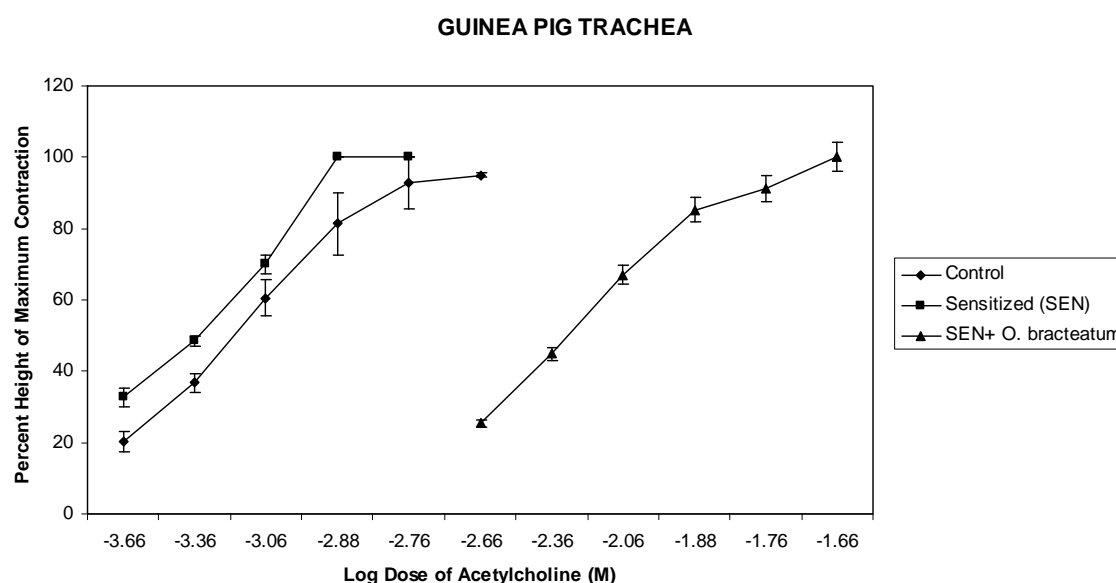
Histopathological examination of control animals revealed no significant abnormalities (fig 1A). There

was a low grade eosinophilia in some sections, but this was not associated with pathological changes. In sensitized animals, there was perivascular and peribronchiolar eosinophilia after challenge. This suggests a net movement of these cells from the vascular to the bronchiolar compartment. The presence of eosinophils in the bronchiolar area showed anatomical correlation with tissue oedema, epithelial cell hypertrophy, damage and airway lumen plugging by mucus and cells, and focal loss of integrity of the smooth muscle layer. The lumen size was reduced drastically (fig 1B). It is evident that treatment with *O. bracteatum* prevented the tissue oedema, epithelial cell hypertrophy, damage and airway lumen plugging thereby decreasing inflammation and bronchoconstriction which leads to normal lumen size (fig 1C).

#### D. Invitro studies on isolated guinea pig trachea

The responses to histamine and acetylcholine were found to be significantly potentiated in guinea pig tracheal strip in animals sensitized with egg albumin compared to control group. There was a leftward shift of dose response curve and the  $pD_2$  values of histamine and acetylcholine in tracheal strip (3.21, 3.36) in sensitized group were significantly greater than the  $pD_2$  values of histamine and acetylcholine in tracheal strip (2.36, 3.21) obtained from the control group. (Fig 2 and 3). Treatment with ethanolic extract of *O. bracteatum* (5 mg/kg, p.o., for 15 days) prevented the potentiation of the responses to histamine and acetylcholine. A rightward shift of dose response curve of histamine and acetylcholine was observed with a significant decrease in  $pD_2$  value of histamine and acetylcholine in guinea pig





**Fig 3:** Effect of ethanolic extract of *O. bracteatum* on acetylcholine induced contractions in tracheal strip preparation of guinea pigs

Each point represents Mean  $\pm$  SEM of 6 experiments

tracheal strip (1.52, 2.29) in *O. bracteatum* treated animals as compared to sensitized group. (Fig 2 and 3).

### DISCUSSION

The concomitant presence of infiltrating eosinophils and T lymphocytes in the bronchi of asthmatics plays a major role in the development of airway inflammation and in the accompanying bronchial hyperreactivity [12-15] which may result from their common pathway of adherence to endothelial cells. Indeed, eosinophils bind to activated endothelial cells by adhering to vascular cell adhesion molecule-1 (VCAM-1) [16], a ligand also involved in lymphocyte adherence to endothelium [17]. Furthermore, adhesion of eosinophils and lymphocytes to VCAM-1 is mediated by the binding of very late activation antigen-4 on their surface [16, 18], which underlines the selectivity of the mechanisms involved in their migration into inflamed tissues. Upon reaching the airways, eosinophils can release a variety of cationic proteins, such as EPO (eosinophil peroxidase) and MBP (major basic protein) that are responsible for injury and shedding of airway epithelium [19-21]. Disruption of the epithelium leads to the exposure of the underlying mucosal structures and sensory nerve endings to allergen and irritants, contributing to the developing of non-specific bronchial hyperreactivity. Moreover, it is also well-established that there are increased eosinophil numbers in the airways of patients with ongoing asthma, even those with mild disease [22], whilst autopsy and biopsy studies have revealed a characteristic eosinophil infiltration of the airway mucosa [23]. In the present study, sensitization using egg albumin (1 ml, 10% w/v, i.p.) and then second exposure to same antigen i.e. egg albumin (0.5 ml, 2% w/v) through saphenous vein

causes acute anaphylactic shock resembling the acute asthmatic attack resulting in the release of various mediators and cellular infiltration. Antigen challenge resulted in a twofold increase in the number of eosinophils in BALF. This was accompanied by intense eosinophil infiltration in the bronchopulmonary tissue, eosinophil migration, accumulation and degranulation in the guinea pig lung as evident from histopathology which is in consistence with reports in the human asthmatic lung. The present findings show that in antigen challenged animals, treatment with *O. bracteatum* significantly inhibited antigen-induced bronchial hyperreactivity by preventing the increase in total leucocyte counts (TLC), eosinophil counts. Airway hyper responsiveness after antigen challenge is supported by the inflammatory pathology suggesting the involvement of other mediators in pathogenesis of asthma. As in human asthma, leukotrienes are also implicated in the induction of antigen-induced airway hyperresponsiveness in the guinea-pig. Neutrophil numbers have also been reported to increase in bronchial lavage fluid [25, 26] in asthmatics, but neutrophilia is generally of shorter duration than eosinophilia [24, 25, 27]. This finding fits well with the current observation that pretreatment of the sensitized animals with *O. bracteatum* resulted in a significant inhibition of antigen-induced bronchial hyperreactivity by decreasing neutrophil counts. The predominant cells in BALF recovered from unchallenged guinea-pigs were those of the monocyte. The numbers of these cells were increased after challenge [28]. In this context, it is worth noting that, treatment of the sensitized animals with *O. bracteatum* produced a significant decrease in monocyte count. Although an influx of lymphocytes does not appear to be a consistent feature of airway inflammation in

this model, it remains possible that antigen specific T-lymphocytes resident in the airway wall become activated as a result of antigen challenge. Thus, T-cells may, by secreting interleukin-4 (IL-4), IL-5 and other proinflammatory cytokines, contribute to the orchestration of the ensuing allergic reaction. In line with this notion, the present findings show that treatment of the sensitized animals with *O. bracteatum* produced a non-significant decrease in lymphocyte count as compared to sensitized animals. In conclusion, the results of this study demonstrate that, in guinea-pig airways, antigen challenge induced eosinophil, neutrophil and monocyte infiltration and activation is similar to that reported in human asthmatics. Changes in the number of lymphocytes did not correlate directly with structural changes. This indicates that protective effect of *O. bracteatum* is by preventing the release of several pre-formed mediators, thereby preventing the direct damage of airway epithelium which in turn prevents airway hyperresponsiveness.

Histamine is released from guinea pig lungs during anaphylaxis by an allergic or nonallergic insult resulting in bronchoconstriction which can be attenuated by H<sub>1</sub> receptor antagonists [29, 30]. Histamine also stimulates sensitized afferent nerves and also activates eosinophils [31, 32]. Thus estimation of histamine levels in the lung tissue itself reveals the mediator release. The histamine levels which were increased due to sensitization with egg albumin were found to be significantly reduced in the *O. bracteatum* treated animals. This depicts that *O. bracteatum* inhibits the release of inflammatory mediator-histamine.

The understanding of various processes involved in bronchial asthma such as inflammatory response can explain various histopathological alterations observed. In asthma, chronic inflammation leads to bronchoconstriction. This leads to airway narrowing and decrease in the lumen size of the bronchioles [37]. This can be clearly seen by the histopathological studies of the lung tissue by observing the cross section of bronchi. In the present study, the sections of the lung tissues of animals sensitized with egg albumin depicted marked bronchitis and severe bronchoconstriction. Treatment with *O. bracteatum* prevented the inflammation and bronchoconstriction which leads to normal lumen size and normal lung cell architecture compared to sensitized group. These results suggest that *O. bracteatum* decreases bronchial hyperresponsiveness by decreasing the infiltration of inflammatory mediators like eosinophils, neutrophils in BALF, inhibiting histamine release from lungs of sensitized guinea pigs and by decreasing airway inflammation as evident from lung cytology.

The presence of acetylcholine muscarinic receptors and histamine H<sub>1</sub> sensitive excitatory receptors in airway smooth muscle of man and animals has been reported [33-36]. Antigen exposure potentiated the responses of histamine and acetylcholine. It was found that an increase in pD<sub>2</sub> value of histamine and acetylcholine in the guinea pig tracheal chain preparation obtained from animals sensitized with egg albumin indicating hyperresponsiveness to histamine and acetylcho-

line. The treatment with *O. bracteatum* decreased the pD<sub>2</sub> value which indicates that it prevents the hyperresponsiveness to histamine and acetylcholine, hence resulting in protective effects in bronchial asthma.

Phytochemical screening of *O. bracteatum* indicates the presence of various chemical constituents like saponin glycosides, anthraquinone glycosides and phenolic compounds. Glycosides are proposed to have antiasthmatic activity through several mechanisms, which includes prevention of allergen induced bronchial obstruction, inhibition of histamine release from polymorphonuclear leucocytes, anti-inflammatory action, spasmolytic activity by relaxation of smooth muscle (tracheal muscle), nonspecific anti-spasmodic action in isolated tissues of guinea pig ileum, rabbit duodenum, frog rectus and rat stomach wherein contractions had been induced by the administration of spasmolytic agents, anti anaphylactic by decreasing cutaneous anaphylaxis and bronchodilator activity by protecting against histamine induced bronchospasm (38-40). Thus it can be concluded that glycosides present contribute to the effect of *O. bracteatum* on bronchial hyperreactivity in the animal experiments in the present study. All the above findings lend credence to the beneficial use of *O. bracteatum* in the treatment of bronchial asthma.

#### ACKNOWLEDGEMENTS

The authors express sincere thanks to all those involved in the completion of work:

1) Dr. Shekhar Sharma and Dr. Prera Desai, Ayurvedic practitioner for their interest and encouragement, 2) Pharmacy Department, M.S. University, Baroda, for providing with the facility for spectrofluorophotometer for histamine estimation, 3) Mr. Dipesh V. Patel, Lecturer, Anand Pharmacy College for assistance in isolated preparations mounting.

#### REFERENCES

1. O' Byrne PM and Postma DS. The many faces of airway inflammation – Asthma and Chronic obstructive pulmonary disease. *Am J Respir Crit Care Med.* 1999; 159: S41-S66.
2. Gienbycz MA. Phosphodiesterase 4 inhibitors and the treatment of asthma- where are we now and where do we go from here. *Drugs.* 2000; 59: 193-212.
3. Barnes PJ and Pederson S. Efficacy and safety of inhaled corticosteroids in asthma. Report of a workshop held in Eze, France, October 1992. *Am Rev Respir Dis.* 1993; 148: S1-S26.
4. Salib RJ, Drake Lee A, Howarth PH. Allergic rhinitis: past, present and the future. *Clin Otolaryngol.* 2003; 28:291-303.
5. Charaka Samhita. Shri Gulabkunverba Ayurvedic Society, Jamnagar, Vol. IV, Ayurvedic Mundranalaya, Jamnagar 1949; 1952-2032.
6. Kirtikar KR, Basu BD. Indian Medicinal Plants, 2<sup>nd</sup> edition, Vol. III, International book distributors 1999; 1699.
7. Dr. KM Nadkarni's. Indian Materia Medica, 3<sup>rd</sup> revised edition, Vol I, Popular Prakashan Pvt. Ltd. 2002; 871.
8. Thomas G, Aroajo CC, Agra F. Preliminary studies on the hydroalcoholic extracts of the root of *Cissampelos sympodialis* Eichl in guinea pig tracheal strip and bronchoalveolar leucocytes. *Phytother Res.* 1995; 9:473-477.
9. Singh R, Nath A, Gupta AA, Shukla M, Khare SK, Kundu B. Antiallergic/antiasthmatic effect of novel antiallergic hexapep-

- tide-95-220 in experimental models. *Ind J Exp Biol.* 2001; 39: 871-877.
10. Shore PA, Burkhalter A, Cohn VH. A method for the fluorimetric assay of histamine in tissues. *J Pharmacol Exp Ther.* 1959; 127:182-186.
  11. Castillo JC, de Beer EJ. The tracheal chain. I. A preparation for the study of anti spasmotic with particular reference to bronchodilator drugs. *J Pharmacol Exp Ther.* 1947; 90:104-109.
  12. Azzawi M, Bradley B, Jeffrey PK, Frew AJ, Wardlaw AJ, Knowles G, Assouf B, Collins JV, Durham S and Kay AB. Identification of activated T lymphocytes and eosinophils in bronchial biopsies in stable atopic asthmatics. *Am Rev Respir Dis.* 1990; 142:1407.
  13. Bentley AM, Meng Q, Robinson DS, Humid Q, Kay AB, and Durham SR. Increases in activated T-lymphocytes, eosinophils, and cytokine mRNA expression for interleukin-5 and granulocyte/macrophage colony-stimulating factor in bronchial biopsies after inhalation challenge in atopic asthmatics. *Am J Respir Cell Mol Biol.* 1993; 8:835.
  14. Jeffery PK, Wardlaw AJ, Nelson FC, Collins JV, and Kay AB. Bronchial biopsies in asthma: an ultrastructural, quantitative study and correlation with hyperreactivity. *Am Rev Respir Dis.* 1989; 140:1745.
  15. Corrigan CJ, and Kay AB. T cells and eosinophils in the pathogenesis of asthma. *Immunol Today.* 1992; 13:501.
  16. Weller PF, Rand TH, Goetz SE, Chi-Rosso G, and Lobb RR. Human eosinophil adherence to vascular endothelium mediated by binding to vascular cell adhesion molecule 1 and endothelial leukocyte adhesion molecule. *Pro Natl Acad Sci. USA* 1991; 88:7430.
  17. Carlos TM, Schwartz BR, Kovach NL, Yee E, Rosa M, Osborn L, Chi-osso G, Newman B, Lobb R, and Harlan JM. Vascular cell adhesion molecule-1 mediates lymphocyte adhesion to cytokine-activated cultured human endothelial cells. *Blood.* 1990; 76:965.
  18. Hemler ME. VLA proteins in the integrin family: structures, functions, and their role on leukocytes. *Annu Rev Immunol.* 1990; 8:365.
  19. Motojima S, Frigas E, Loegering DA, and Gleich GJ. Gleich. Toxicity of eosinophil cationic proteins for guinea-pig tracheal epithelium in vitro. *Am Rev Respir Dis.* 1989; 139:801.
  20. Gleich GJ, Frigas E, Loegering DA, Wassom DL, and Steinmuller D. Cytotoxic properties of the eosinophil major basic protein. *J Immunol.* 1979; 123:2925.
  21. Frigas E, Loegering DA, and Gleich GJ. Cytotoxic effects of the guinea-pig major basic protein on tracheal epithelium. *Lab Invest.* 1980; 42:35.
  22. Beasley R, Roche RW, Roberts JA, Holgate ST. Cellular events in the bronchi in mild asthma and after bronchial provocation. *Am Rev Respir Dis.* 1989; 139: 806-817.
  23. Djukanovic R, Roche WR, Wilson JW, et al. Mucosal inflammation in asthma. *Am Rev Respir Dis.* 1990; 142:434-457.
  24. Diaz P, Gonzalez MC, Galleguillos FR, et al. Leukocytes and mediators in bronchoalveolar lavage during allergen induced late-phase asthmatic reactions. *Am Rev Respir Dis.* 1989; 139: 1383-1388.
  25. Metzger WJ, Zavala D, Richerson HB, et al. Local allergen challenge and bronchoalveolar lavage of allergic asthmatic lungs: description of the model and local airway inflammation. *Am Rev Respir Dis.* 1987; 135:433-440.
  26. Metzger WJ, Richerson HB, Worden K, Monick M, Hunninghake GW. Bronchoalveolar lavage of allergic asthmatic patients following allergen bronchoprovocation. *Chest.* 1986; 89: 477-483.
  27. Smith HR, Larsen GL, Cherniak RM, et al. Inflammatory cells and Eicosanoid mediators in subjects with late asthmatic responses and increases in airway responsiveness. *J Allergy Clin Immunol.* 1992; 89: 1076-1084.
  28. Tarayre JP, Aliaga M, Barbara M, Tisseyre N, Vieu S, Tisne-Versailles J. Model of bronchial hyperreactivity after active anaphylactic shock in conscious guinea pigs. *J Pharmacol Methods.* 1990 ; 23: 13-19.
  29. Bartosch H, Feldberg W, Nagel E. Das Freiwerden eines histaminähnlichen stoffes bei der anaphylaxie der Meerschweinchen, Pflungers. *Arch Ges Physiol.* 1932; 230:120-153.
  30. Holgate ST, Finnerty JP. Antihistamines in asthma. *J Allergy Clin Immunol.* 1989; 83:537-547.
  31. Empey DW, Laitinen LA, Jacobs L, Gold WM, Nadel JA. Mechanisms of bronchial hyperreactivity in normal subjects after upper respiratory tract infection. *Am Rev Respir Dis.* 1976; 113:131-139.
  32. Raible DG, Lenahan T, Fayvilevich Y, Kosinski R, Schulman ES. Pharmacologic characterization of a novel histamine receptor on human eosinophils. *Am J Resp Crit Care Med.* 1994; 149:1506-11.
  33. Chand N, Eyre P. Classification and biological distribution of histamine receptor subtypes. *Agents and Actions.* 1975; 5:277.
  34. Fleisch JH, Calkins PJ. Comparison of drug induced responses of rabbit trachea and bronchi. *J. Appl. Physiol.* 1976; 41:62.
  35. Persson Cag, Ekam N. Contractile effects of histamine in large and small respiratory airways. *Agents and Actions.* 1976; 6:389.
  36. Murray JF, Nadel JA. Textbook of Respiratory Medicine, Vol.I, 3<sup>rd</sup> edition, Philadelphia, Pa.: W.B. Saunders 2000.
  37. Dipiro JT, Talbert RL, Yee GC, Matzke GR, Wells BG, Posey LM. Pharmacotherapy, a pathophysiologic approach, fifth edition, 2002.
  38. Puri, A. et al. Immunostimulant activity of picrorhiz, the iridoid glycoside fraction of *Picrorhiza kurroa*, and its protective action against *Leishmania donovani* infection in hamsters. *Planta Medica.* 1985; 58: 528-532.
  39. Johri, R.K. et al. Effect of quercetin and *Albizia* saponins on rat mast cell. *Ind. J. Physiol. Pharmacol.* 1985; 29:43-46.
  40. Vasavada, S.A. et al. Gamma sitosterol from *Clerodendron serratum*. *Bull. Calc. Sch. Trop. Med.* 1967; 15: 61.

## CURRENT AUTHOR ADDRESSES

Kalpna Govindbhai Patel, Assistant Professor, Pharmaceutical Chemistry Department, Anand Pharmacy College, India. E-mail: [kalpana\\_jpatel@yahoo.com](mailto:kalpana_jpatel@yahoo.com) (Corresponding author)

Kirti Vinodrai Patel, Assistant Professor, Pharmacology Department, Anand Pharmacy College, India. E-mail: [kirtipatel\\_13@yahoo.com](mailto:kirtipatel_13@yahoo.com)

Tejal Ricky Gandhi, Professor and Principal, Pharmacology Department, Anand Pharmacy College, India. E-mail: [rickygandhi@hotmail.com](mailto:rickygandhi@hotmail.com)