



Original Article

IRANIAN JOURNAL OF PHARMACOLOGY & THERAPEUTICS
Copyright © 2018 by Iran University of Medical Sciences

Iranian J Pharmacol Ther. 2019 (June);17:1-10.



Comparative study of protective effect of silymarin and n-acetyl cysteine on isoniazid induced hepatotoxicity in mice

Sarwat Jahan^{1*}, Lubna Danish², Manzoor Khan³, Marva Sandhu², Naila Abrar⁴, Riffat Siddiq⁵, Abid Hussain⁶

¹ Khyber Medical College, Khyber Medical University, Peshawar, Pakistan.

² Islamic International Medical College (IIMC), Riphah International University, Rawalpindi, Pakistan.

³ Khyber teaching Hospital, Khyber Medical University, Peshawar, Pakistan. KMU Peshawar, RMC Peshawar

⁴ HITEC Institute of Medical Sciences, National University of Medical Sciences, Rawalpindi, Pakistan.

⁵ Rehman College of Dentistry, Khyber Medical University, Peshawar, Pakistan

⁶ North West School of Medicine, Khyber Medical University, Peshawar, Pakistan.

Please cite this article as:

Jahan S, Siddiq R, Khan M, Sandhu M, Abrar N, Danish L, Hussain A. Comparative study of protective effect of silymarin and n-acetyl cysteine on isoniazid induced hepatotoxicity in mice. Iranian J Pharmacol Ther. 2019 (June);17:1-10.

ABSTRACT

Drug induced liver injury (DILI) leads to acute hepatitis in 10%, liver failure, and death in 30%. One of the major drugs causing DILI is Anti-tuberculous drugs and since tuberculosis is affecting 1/3rd of the total world population, their use is quite common. Use of Isoniazid (INH) is limited owing to hepatotoxicity following the stress produced by oxidative species. Silymarin has hepatoprotective potential because of anti-oxidant property. N-Acetylcysteine (NAC) on the other hand triggers the cellular protective mechanisms by replenishing glutathione in the cells. The main aim of this study was to compare the hepatoprotective activity of Silymarin and NAC against INH induced toxicity. Total 50 BALB/C mice were sorted into a total of 5 groups, with 10 mice in each group for 2 weeks by random sampling. Control group was administered distilled water through I/P route daily. The INH group was administered I/P 100 mg/kg INH daily. The INH/Silymarin group was administered 150 mg/kg INH and 50 mg/kg Silymarin I/P daily. The INH/NAC group was administered 150mg/kg INH and 300mg/kg of NAC I/P daily. The INH/NAC/silymarin group was administered 150mg/kg INH, 300mg/kg of NAC and 50mg/kg of silymarin I/P daily. On day 14, the dissection of all the mice was done. Liver function tests were performed and histopathology was done. Both NAC and Silymarin demonstrated hepatoprotection that was statistically similar. However, the mice of silymarin group looked weak and less active and six dies within 5-8 days after the end of the experimental doses of the drugs.

Conflicts of Interest: Declared None

Funding: None

Keywords

DILI,
Hepatotoxic potential,
Oxidative stress,
Anti-oxidant

Corresponding to:

Sarwat Jahan,
Khyber Medical College, Khyber
Medical University, Peshawar,
Pakistan

Email:

sarwatt.jahan@gmail.com

Received: 10 Dec 2018

Published: 10 Jun 2019

INTRODUCTION

DILI includes varying degrees of responses that occur as a result of exposure to synthetic or natural chemical substances. DILI is a serious rising issue in the fields of medicine, science, and public health. The incidence is approximately around 10 to 15 /100,000 of individuals [1]. About 10 % of all the acute hepatitis cases worldwide are due to DILI. Medications are withdrawn from the market most

commonly due to DILI [2]. It is the major cause of acute liver failure among patients. Death rate among patients suffering from DILI is about 30 percent [2].

One of the major groups of drugs that lead to the drug induced liver injury is the Anti-Tuberculous drugs. It is one of the top 10 causes of death in the world [3]. About 1 in 3 individuals have infection of TB worldwide. In 2010, WHO

statistics showed about that around the world there are about 8.8 million of cases.

As the incidence of tuberculosis is still quite high worldwide as is the use of ATT and hence, the incidence of DILI caused by ATT. One of the notorious ATT drugs producing hepatotoxicity is Isoniazid (INH). Isoniazid is known to cause severe and sometimes fatal hepatitis. Within the first 2 months of therapy, isoniazid-induced liver toxicity occur in about 50% of patients [4]. Although the main mechanism of hepatotoxicity of INH is still to be understood but according to animal models the hepatotoxicity by INH is due to oxidative stress, lipid peroxidation, reduced levels of glutathione [5] or activation of CYP2E1 or a combination of either all or some of these mechanisms.

The hepatotoxicity leads to induction of apoptosis of hepatocytes, breaks in the DNA strands and mitochondrial membrane disruption. The reactive metabolites produced by INH metabolism, including *N*-acetylisoniazid (AcINH) and Hydrazine (Hz) damage the hepatocytes [6].

Silymarin (milk thistle) is extracted from the seeds of *Silybum marianum* has documented hepatoprotective properties. Their mechanisms of hepatoprotection are not fully understood. However, there are four proposed mechanisms: It has antioxidant property and regulates intracellular glutathione; prevents the entry of toxins in the hepatocytes by altering the membrane permeability; promotes liver regeneration by enhancing RNA synthesis; is an inhibitor the transformation of stellate hepatocytes into myofibroblasts [13].

N-Acetylcysteine (NAC) is a prodrug that forms L-cysteine primarily used as a mucolytic agent. It triggers the cellular protective mechanisms by replenishing glutathione in the cells. During oxidative burst, NAC reduces the release of reactive oxygen species from the neutrophils. It replenishes the hepatic stores of glutathione by providing the substrate cysteine. It has the capability of arresting the hepatic stellate cells in the G1 phase thus halting the process of fibrogenesis, NAC decreases the peroxidation of membrane lipids and produces anti-toxin effect as it can increase the hepatic blood flow, replenishes glutathione and scavenges free toxic radicals, NAC causes the down regulation of the enzyme glutathione S-transferase, responsible for the metabolism of glutathione and NAC inhibits the activation of NF- κ B, an important factor in fibrogenesis [8].

This study is designed to understand and compare the protective effect of Silymarin and NAC on the hepatotoxicity induced by INH.

MATERIALS AND METHODS

Study Design

This study was a laboratory based randomized controlled trial.

Study Settings

The study was carried out in the Veterinary research institute, Peshawar in collaboration with the Pharmacology

Department of, Khyber girls' medical-college and Khyber medical university, Peshawar. Male mice, 25-30 grams of weight were kept in the animal house for one week prior to the study in Veterinary research institute Peshawar under standard conditions of with temperature of 20-25°C. Mice were given proper diet and water throughout the duration of the study.

Sample Collection Technique

BALB/C mice were initially selected through random sampling method.

Sample Size

A total of 50 mice of BALB/C type were randomly sorted into a total of 5 groups; each of the groups including the one used as control had 10 animals.

Inclusion Criteria

- Male BALB/C mice
- Mice aged 5 -7 weeks
- Mice weighing 25 – 30 g

Exclusion Criteria

- Inactive mice
- Mice having a prominent deformity

Data Collection Procedure

All the animals were sacrificed on day 14. Terminal cardiac blood samples were taken for the assessment of the liver enzymes, bilirubin, enzyme alkaline phosphatase, enzyme aspartate aminotransferase and enzyme alanine aminotransferase. Liver was dissected out, preserved in 5% formalin and sent for histopathology.

Duration of Study

The study was conducted for a period of 2 weeks from 1st July 2018 to 14th July 2018.

Generation of Isoniazid Induced Hepatotoxic Model

A pilot project was carried out to confirm the hepatotoxic dose of INH and hepatoprotective doses of silymarin and NAC, in male mice of BALB/C type. INH was given 150mg per kg, 50mg per Kg Silymarin & 300mg per Kg NAC keeping the time span of 24 hours between injections for 2 weeks was given.

At the end of 2 weeks terminal sampling and dissection was selected on the basis of previous researches.

Experimental Outline

The selected mice were sorted randomly into a total of 5 groups containing 10 mice in each group for 2 weeks. Strict aseptic measures were observed during solution (drug) preparation and administration. Fresh solutions of drugs were prepared before each dose.

Group 1 (n=10) served as a control group and received intra-peritoneal doses of distilled water daily. In Group 2 (INH group), the liver toxicity was produced in total 10 mice by giving injection of INH 150mg per kg intra-peritoneally for a time interval of total 2 weeks. In Group 3 (INH/Silymarin group), 10 mice were given intraperitoneal injection of INH 150mg/kg and Silymarin 50mg per Kg for a time interval of total 2 weeks. In Group 4 (INH/NAC group), 10 mice were given intraperitoneal injection of INH

150mg/kg and NAC 300mg per Kg given one hour before INH, for a time interval of total 2 weeks. In Group 5 (INH/Silymarin/NAC group), 10 mice were given intraperitoneal injection of INH 150mg per kg, Silymarin 50mg per Kg and NAC 300mg per Kg for time interval of total 2 weeks. NAC injection was given an hour before the dose of INH.

Each dose of the drugs in every group was given at an interval of 24 hours.

Table 1. Following design was followed for the experiment

-Grouping	Isoniazid	Silymarin	NAC	Dissection
-Group 1 Mice 10	-	-	-	Day 14
-Group 2 Mice 10	150mg/kg [33, 34] of INH in water daily.	-	-	Day 14
-Group 3 Mice 10	150mg/kg of INH in water daily.	50mg/kg [35, 36] of silymarin in water daily.	-	Day 14
-Group 4 Mice 10	150mg/kg of INH in water daily.	-	300mg/kg [37] of NAC in water daily.	Day 14
-Group 5 Mice 10	150mg/kg of INH in water daily.	50mg/kg of silymarin in water daily.	300mg/kg of NAC in water daily.	Day 14

Table 2. The histopathological changes were graded according to Knodell Modified scoring system

A. Peri-portal or peri-septal interface hepatitis (piecemeal necrosis)	Grading
Observation:	
Absent	0
Mild (focal, few portal areas)	1
Mild/moderate (focal, most portal areas)	2
Moderate (continuous around, <50% of tracts or septa)	3
Severe (continuous around, >50% of tracts or septa)	4
B. Confluent necrosis	
Observation:	Grading
Absent	0
Focal confluent necrosis	1
Zone 3 (centri-lobular) necrosis in some areas	2
Zone 3 necrosis in most areas	3
Zone 3 necrosis 1 occasional portal-central (P-C) Bridging	4
Zone 3 necrosis 1 multiple P-C bridging	5
Panacinar or multi-acinar necrosis	6
C. Focal (spotty) lytic necrosis, apoptosis and focal inflammation	
Observation:	Grading
Absent	0
One focus or less per 10 X objective	1
Two to four foci per 10 X objective	2
Five to ten foci per 10 X objective	3
More than ten foci per 10 X objective	4
D. Portal Inflammation	
Observation:	Grading
None	0
Mild, some or all portal areas	1
Moderate, some or all portal areas	2
Moderate/marked, all portal areas	3
Marked, all portal areas	4
Maximum possible score for grading = 18	
Minimal inflammation = 1-3	
Mild inflammation = 4-8	
Moderate inflammation = 9-12	
Severe inflammation = 13-18	

Design of the Experiment

Blood Sampling Procedure

Terminal blood sampling was performed through cardiac puncture for all the groups at the end of 2 weeks, 24 hours after the last dose of the drugs. Animals were dissected and 0.5-1.5 ml of blood was gradually withdrawn with 1 ml syringe. Samples were taken to Clinical Pathology Laboratory where they were centrifuged for ten minutes to separate the serum for the assessment of ALT, ALP, AST and Bilirubin.

Liver Histopathology

The histopathological changes were graded according to Knodell Modified scoring system. As duration of the study was short, fibrosis was not looked for (Table 1 and Table 2).

Statistical Analysis

The expression of the obtained results was done in the form of mean value and standard deviation. The statistical analysis was done on statistical package for social sciences SPSS 23. Comparison of biochemical markers at initial and final hours in the same group was subjected to the one-way ANOVA test. The Post-Hoc test of Tukey was then applied to the data. The range of the significant value was taken to be, $p < 0.05$.

Validity of animal species or model selection

For this research study we chose BALB/C mice because of the fact that the characteristics that these mice possess make them an ideal model for hepatotoxicity studies. This

includes induction of injury to the liver in a big percentage of these animals, low cost of these mice as well as the ease of their management [9].

RESULTS

Group 1

The group 1 received I/P normal saline daily for 2 weeks. LFTs remained within normal limits. Histopathology of group 1 coincided with the biochemical parameters, graded as normal according to ISHAK's criteria (Fig. 1).

Group 2

INH receiving mice were less active and worn-down as compared to mice of control Group 1 during the experimental period. Liver enzymes were significantly raised and light microscopy of slides classed slides as moderate damage (Fig. 2). All the mice in this group died within 2 to 3 days after receiving the last experimental dose of INH.

Group 3

In Group 3 which received isoniazid 150mg/kg and Silymarin 50mg/kg daily intraperitoneally for 2 weeks, the liver function test parameters remained within normal limits. In this group, after light microscopy of H & E stained slides were classed to have minimal histopathological changes (Fig. 3). On observation however, the mice of this group were weak and less active. Six out of the ten mice in the group died within 5-8 days after the last doses of the experimental drugs.

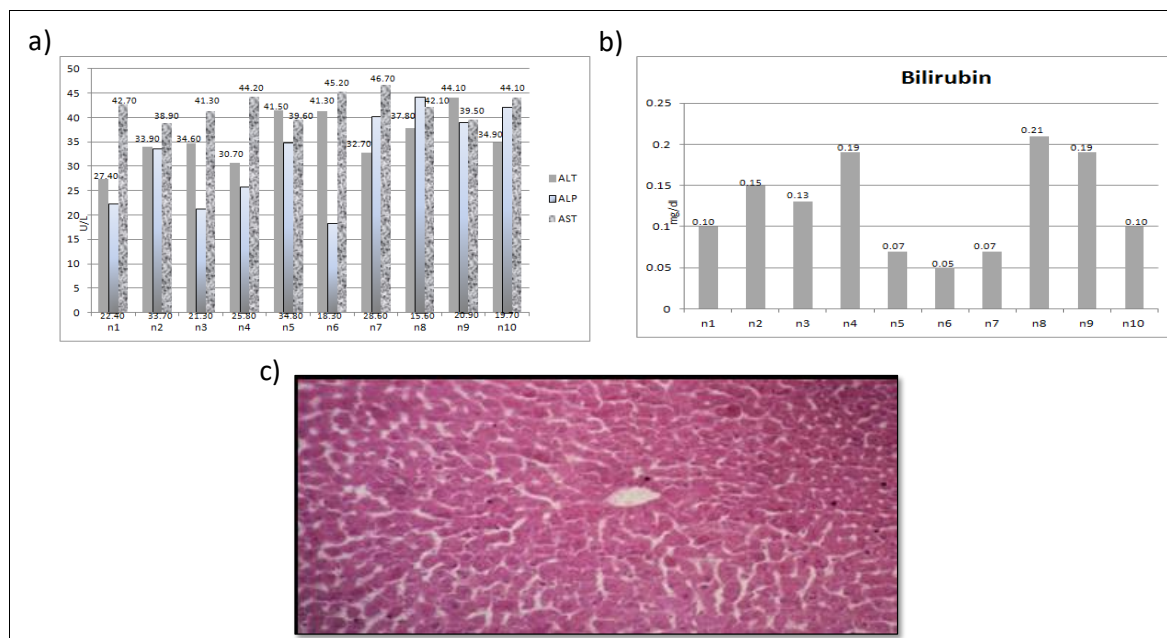


Figure 1. Biochemical and histological parameters of group 1 samples. a) Normal liver parameters with mean serum ALT level was 35.89 ± 5.24 U/L, ALP exhibited a mean value of 32.20 ± 9.51 U/L, AST a mean value of 42.43 ± 2.63 U/L, b) Normal serum bilirubin showing a mean value of 0.12 ± 0.05 mg/dl, c) The histology of the liver slice fixed in 5% formalin and stained with H & E showed normal hepatocytes.

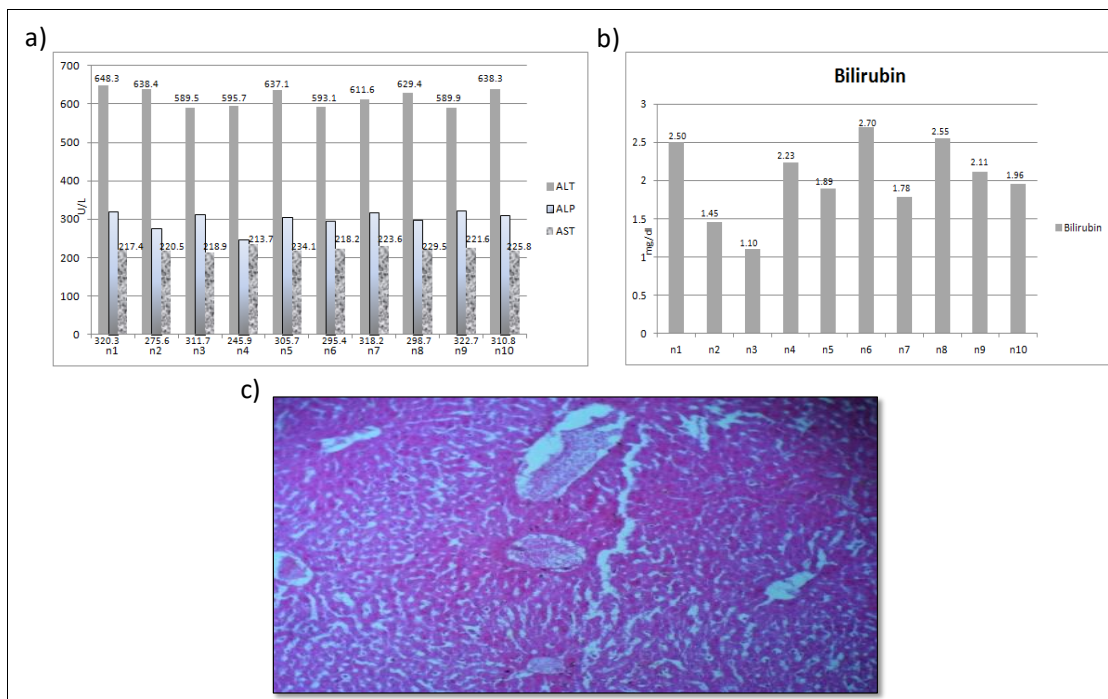


Figure 2. Biochemical and histological parameters of group 2 samples. a) Mean serum ALT levels significantly raised to a mean value of 647.13 ± 104.71 U/L. similar pattern was displayed by ALP levels with a mean value of 300.5 ± 23.77 U/L. The levels of AST showed a raised mean value of 222.3 ± 6.10 U/L, b) Rise in serum bilirubin was noted with a mean value of 2.02 ± 0.50 mg/dl, c) Histopathological section of the mice liver treated with INH for 14 days. The liver was fixed in 5% formalin and stained with H & E. classed slides as moderate damage. The total score was graded as 10 with moderate periportal necrosis in most areas (2), confluent necrosis in most areas (3), 5-10 foci of lytic necrosis per 10X (3) and moderate portal inflammation in some portal areas (2).

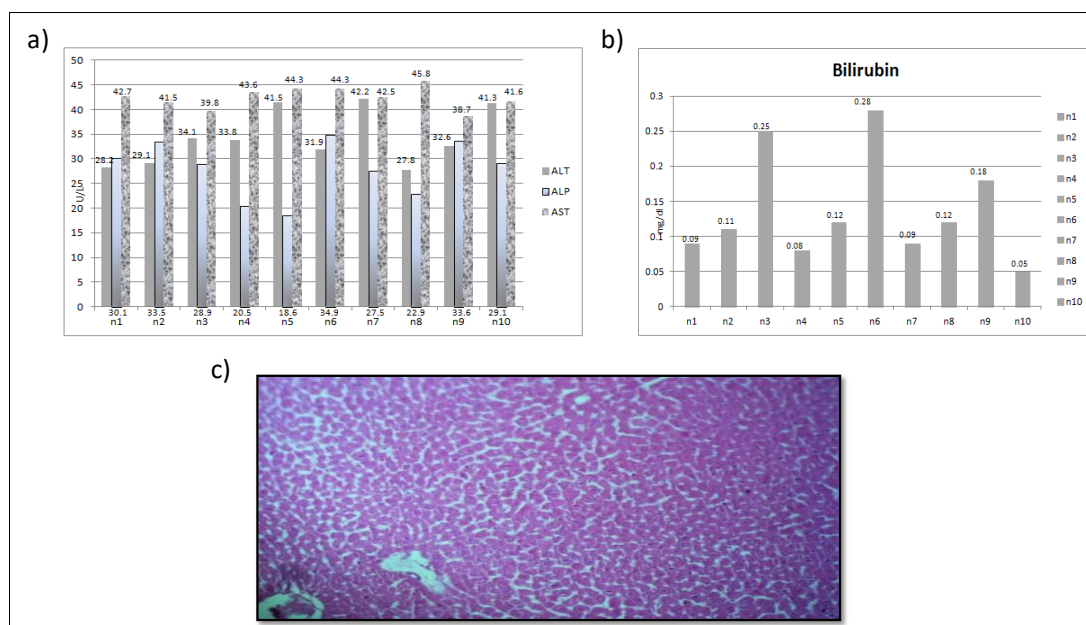


Figure 3. Biochemical and histological parameters of group 3 samples. a) Normal liver enzymes with mean serum ALT of 34.25 ± 5.56 U/L; ALP registered a mean value of 27.96 ± 5.64 U/L, AST of 42.48 ± 2.16 U/L, b) Normal serum bilirubin of 0.13 ± 0.07 mg/dl, c) light microscopy of H & E stained slides were classed to have minimal histopathological changes [Fig - 5.8]. The slides showed focal confluent necrosis with score of 1.

Group 4

In INH/NAC group the mice looked healthy and active.

The liver function tests demonstrated normal parameters. The light microscopy of H & E stained slides was classed to

have normal histological structure (Fig. 4).

Group 5

In Group 5 which received isoniazid 150mg/kg, Silymarin 50mg/kg and N-Acetylcysteine 300mg/kg daily intraperitoneally for 2 weeks, the liver function test parameters remained within normal limits. In this group, after light microscopy of H & E stained slides were classed to have normal histological structure (Fig. 5).

Comparison between Groups

Comparison of mean serum liver function parameters between all the groups showed a significant difference in ALT levels of Group 2 with p less than 0.05 in range (Table 3).

DISCUSSION

The issue of hepatic injury induced by drugs still remains an unresolved. Its impact on the healthcare system is even greater than the total number of cases that are reported every year. It was ranked at the top among the adverse effects pro-

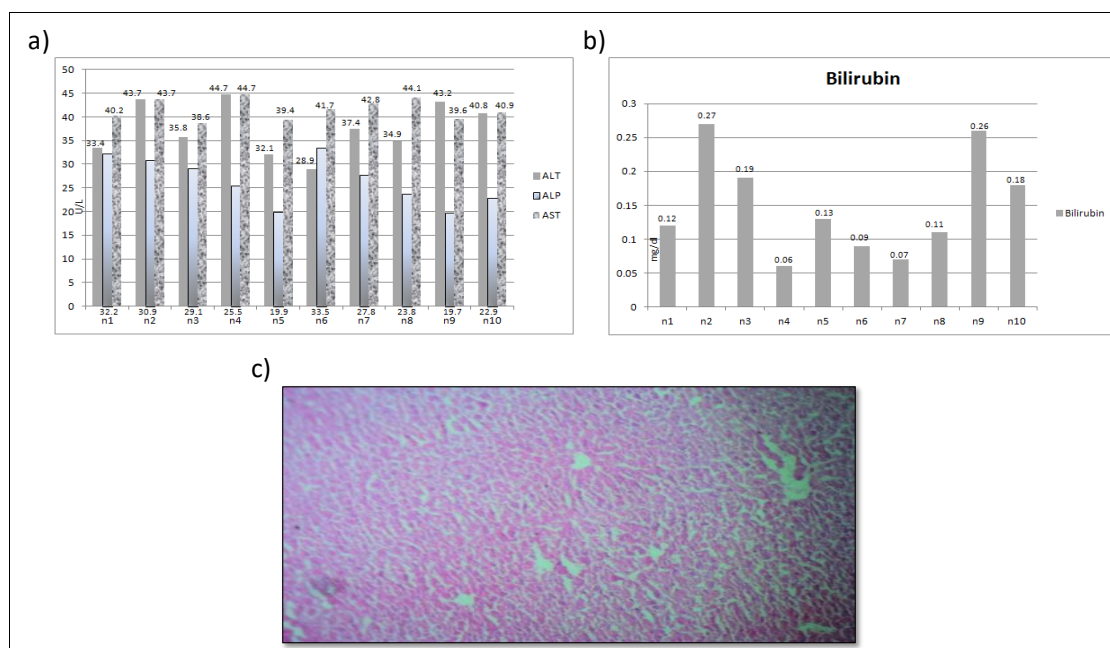


Figure 4. Biochemical and histological parameters of group 4 samples. a) Mean serum ALT of 37.4 ± 5.40 U/L; ALP registered a mean value of 26.53 ± 4.94 U/L, AST of 41.57 ± 2.16 U/L, b) Normal serum Bilirubin of 0.14 ± 0.07 mg/dl, c) Light microscopy of H & E stained slides was classed to have normal histological structure.

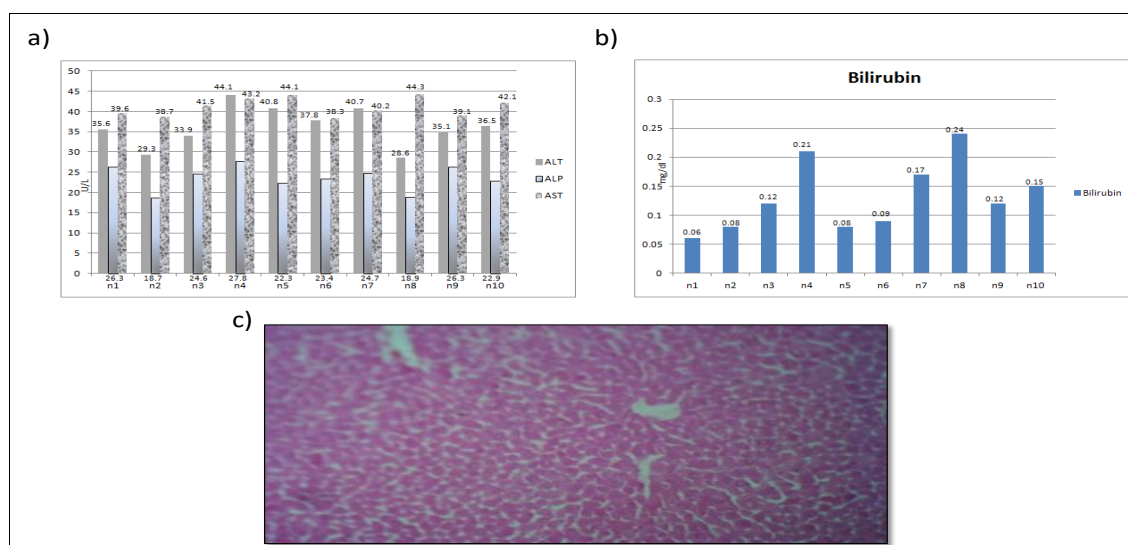


Figure 5. Biochemical and histological parameters of group 5 samples. a) Normal Lfts with mean serum ALT of 34.25 ± 5.56 U/L; ALP registered a mean value of 27.96 ± 5.64 U/L, AST of 42.48 ± 2.16 U/L, b) Normal Bilirubin of 0.13 ± 0.07 mg/dl, c) Light microscopy of H & E stained slides were classed to have normal histological structure.

Table 3. Comparison between Groups

Groups		ALT	ALP	AST	Bilirubin
Group 1	Group 2	0.000*	0.000*	0.000*	0.000*
	Group 3	1.000	0.932	1.000	1.000
	Group 4	1.000	0.828	0.980	1.000
	Group 5	1.000	0.503	0.909	1.000
	Group 1	0.000*	0.000*	0.000*	0.000*
Group 2	Group 3	0.000*	0.000*	0.000*	0.000*
	Group 4	0.000*	0.000*	0.000*	0.000*
	Group 5	0.000*	0.000*	0.000*	0.000*
	Group 1	1.000	0.932	1.000	1.000
Group 3	Group 2	0.000*	0.000*	0.000*	0.000*
	Group 4	1.000	0.999	0.975	1.000
	Group 5	1.000	0.925	0.897	1.000
	Group 1	1.000	0.828	1.000	1.000
Group 4	Group 2	0.000*	0.000*	0.000*	0.000*
	Group 3	1.000	0.999	0.975	1.000
	Group 5	1.000	0.982	0.998	1.000
	Group 1	1.000	0.503	0.909	1.000
Group 5	Group 2	0.000*	0.000*	0.000*	0.000*
	Group 3	1.000	0.925	0.897	1.000
	Group 4	1.000	0.982	0.998	1.000
	Group 1	1.000	0.982	0.998	1.000

*The mean difference is significant at the 0.05 level

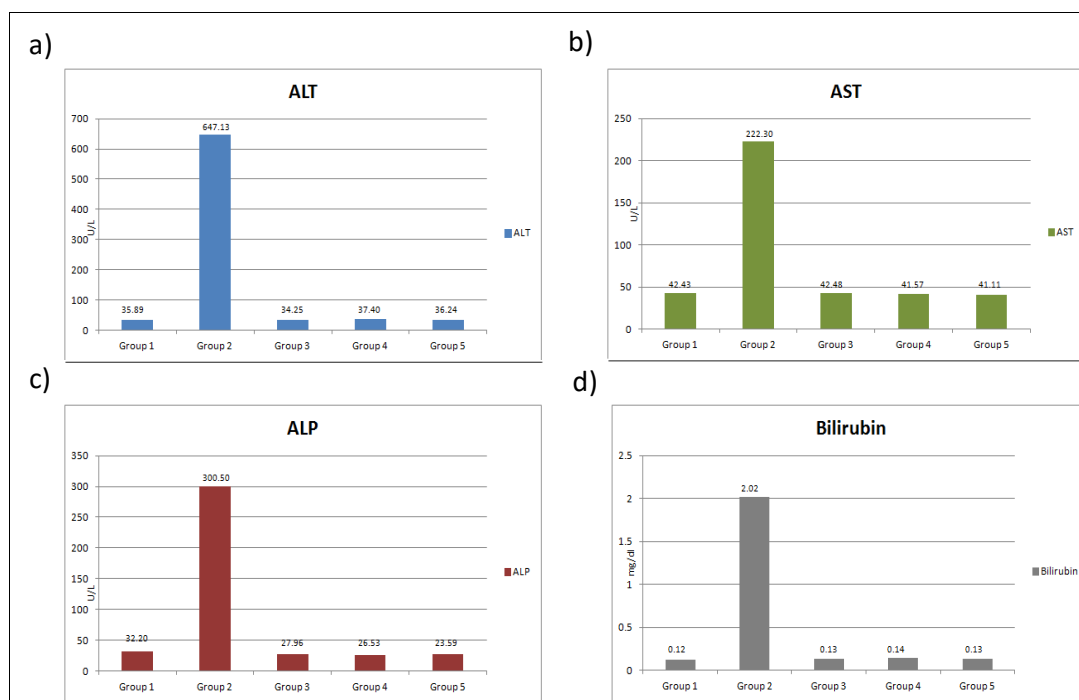


Figure 6. Comparison of Liver function Tests (LFTs) in different groups. Comparison between all the groups demonstrated a significant difference in ALT levels of Group 2 with p less than 0.05 in range. No statistical difference was found between group 3 and 4 although clinically NAC group showed better response

duced by drugs in 2006 [10], DILI has emerged as the most common reason for the termination of drug development programs and post-marketing drug regulatory decisions. Out of 1000 drugs known to cause hepatic damage, more than 50 approved ones have been withdrawn from markets worldwide owing to their hepatotoxic potential [11]. Serious DILI is induced by the anti tuberculosis drugs that are used in a very high number owing to the prevalence of tuberculosis

infection all over the world. Ever since 1993, TB has been labeled as a public health emergency by the WHO [12].

Tuberculosis is a curable disease with very efficacious drugs available for the treatment. Isoniazid is among the commonly used anti tuberculous drugs and is very efficacious in treating the infection. However, the hepatotoxicity induced by these drugs is fatal and a big limiting factor in the treatment continuation. The therapy has to be withdrawn,

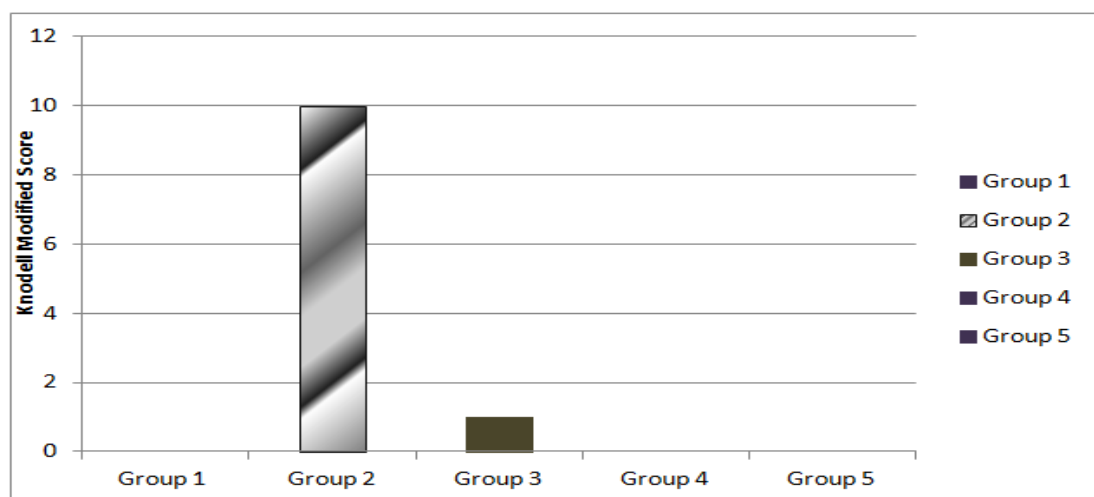


Figure 7. Comparison of Knodell Scoring. The group 2 score was showing moderate histopathological damage.

withheld until the LFTs are back to normal or switched and the second line agents are not only expensive but also more toxic [13]. Upon restarting the first line drug after the LFTs return to normal about 11-24 percent of the patients suffer from the drug induced hepatotoxicity again [14, 15]. Decision in these cases is very controversial and difficult as there is risk of toxicity but at the same time there is requirement of threatening the infection that can be life threatening, stopping the disease progress and transmission. So, the best option in this scenario is the development of methods to prevent and reduce the hepatotoxicity of the first line anti tuberculosis drugs. There is very less evidence available for the exact pathophysiological mechanism of these drugs that has the toxic potential and in addition it is hard to predict whether the toxicity is self limiting and reversible or it is going to cause cirrhosis and liver failure.

Isoniazid being very efficacious is used commonly in the treatment of the tuberculosis infection. INH, however has a very serious risk of producing toxicity in the liver [16]. Within the first 2 months of therapy, isoniazid-induced liver toxicity occur in about 50% of patients [17]. The DILI caused by INH is due to an idiosyncratic mechanism [18]. Although the main mechanism of hepatotoxicity of INH is still to be understood but according to animal models the hepatotoxicity by INH is due to the stress produced by toxic metabolites [19], peroxidation of the lipid membrane [20], depletion of glutathione in the cells [21] or activation of CYP2E1 [22] or a combination of either all or some of these mechanisms. INH is metabolized into products that act as reactive oxygen species and increase the oxidative stress. The oxidative stress ultimately leads to the disruption of the hepatocyte membranes and cell damage. Under the oxidative stress the liver produces glutathione that possesses antioxidant properties in its reduced form. However, INH is known to deplete the stores of glutathione hence leading to hepatocyte damage. If either the production of the oxidating radicals by INH is reduced or glutathione stores are replenished the liver

damage may be prevented.

The pattern in which hepatic enzymes are raised in case of INH use is mostly hepatocellular. Isoniazid induces the apoptosis of liver cells. The membrane of mitochondria is disrupted and there is breakage of the strands of DNA. The INH metabolites can bind to and produce destruction of the macromolecules of the hepatocytes [29]. Hepatocellular injury induced by INH show the pattern of hepatic necrosis. Zonal necrosis with coagulation is observed varying in intensity, either involving a fraction of a single acinar zone to extension of necrosis to the whole of acinus.

During the initial stages, the regions with necrosis contain the ghost cells of hepatocytes. When the injury progresses further there is migration of, neutrophils & macrophages to the zone of necrosis, starting from the edges. Eventually within 12 to 24 hours of the injury, the process of necrosis progresses and only pigmented macrophages are observed that have replaced the hepatocytes. The apoptosis of the hepatocytes is observed at the necrotic corners. Significant amount of inflammation, portal triditis, lymphocytic and neutrophil infiltration is present.

Realizing the increasing necessity of use of INH but high incidence of morbidity with the use of this drug, we decided to investigate the extent of INH induced liver injury and its prevention by the use of Silymarin and N-Acetylcysteine, both of which have the hepatoprotective potential and can help reduced the INH induced morbidity. For our research study we chose BALB/C mice because of the fact that the characteristics that these mice possess make them an ideal model for hepatotoxicity studies. This includes induction of injury to the liver in a big percentage of these animals, low cost of these mice as well as the ease of their management. According to *Muruganandan & Sinal* [23], in cases of toxicity including the metabolism by the cytochromal enzymes, mice can be used as an efficient model. Our choice of mice was also supported by *Metushi* [24], who showed that reactive metabolites bind more with mice and human hepatic

microsomes as compared to rats. Depending upon the pattern of hepatic damage produced by INH measurement of ALT, AST, ALP and Bilirubin was used for liver injury assessment. Histopathology was performed to look for the changes induced by INH and preventive effect of NAC and Silymarin.

Group 1 served as control group in our study which was given no drugs but normal food and water followed by sacrifice, 2 weeks later. Serum ALT and ALP remained within reference range as compared to the study of *Michael.A & Christine.H* [25]. The biochemical parameters were found within normal limits. Histopathological examination of H & E stained slides revealed normal cellular organization of mouse liver compared to a study conducted by *Janie L. Baratta, 2009* [26].

Hepatotoxicity was induced in mice of group 2 by daily intraperitoneal injection of INH 150 mg/kg. ALT and ALP had risen significantly after 2 weeks of administration which was also reflected by a change in the general activity and behavior of mice. The rise in ALT was more than that seen for ALP. These findings were backed by research of *Xi Chin & fellows* in 2011 [27]. Light microscopy revealed marked inflammation with moderate to severe changes. These hepatic structural distortion as a result of administration of INH were also observed by *Saima Rafiq, Adnan Jehangir & colleagues* of Islamic international medical college in 2015 [28].

Silymarin was chosen because of it possess an antioxidant property, and alters the membrane permeability thus preventing the entry of toxins into the hepatocytes. N-Acetylcysteine on the other hand, triggers the cellular protective mechanisms by replenishing glutathione in the cells.

Group 3 was given daily I/P dose of INH 150mg/kg followed by I/P Silymarin 50mg/kg. When samples were taken and analyzed 2 weeks later, 24 hours after the last dose, hepatic biomarkers remained normal and was in accordance with a study performed by *S Jahan, M Khan & colleagues* [30]. Histopathological examination also revealed marked improvement in all parameters of ISHAK'S grading.

Group 4 received I/P INH daily in a dose of 150mg/kg followed by I/P NAC 300mg/kg for a period of 2 weeks. The assessment of biochemical parameters and histo-pathology was performed 2 weeks later. NAC administration effectively diminished the elevation in ALT and ALP levels seen in group 2. A positive response was also observed during light microscopy with showing only mild changes. The remedial effect of NAC inspected in this group was in accordance with previous studies of *S Baniasadi, P Eftekhari & colleagues* [31].

Group 5 received daily I/P doses of INH 150mg/kg, Silymarin 50mg/kg and NAC 300mg/kg for a period of 2 weeks. Co-administration of Silymarin and NAC was protective against DILI in animals treated with hepatotoxic doses of INH. The results can be compared to a study performed by *M Singh, P Sasi & colleagues* [32]. As compared to Group 2 (INH Group) both ALT and ALP displayed statistically significant difference with $p < 0.01$. Lack of unremark-

able increase in liver enzymes was in harmony with histological scores of liver slides of both groups.

CONCLUSION & RECOMMENDATIONS

INH induced hepato-toxicity occurs through multiple mechanisms. Reduction in the oxidative stress either by antagonizing the reactive metabolites or replenishing antioxidant stores in the body can alter or even inhibit the extent of the hepatic damage caused by INH. Silymarin reduces the hepato-toxic potential of Isoniazid by either removing the toxic metabolites or reducing their entry into the hepatocytes. N-Acetylcysteine acting via replenishing the glutathione stores in the body possesses the hepatoprotective effect. There was no statistically significant difference in the groups treated with Silymarin and NAC, however, the Silymarin group mice were weak, less active and six out of the ten died with 5-8 days after the experiments while all the mice in the NAC group were not only healthy but also survived during the month of the follow-up.

Further research work should be carried out for the evaluation of the hepato-protective potential caused by NAC as compared to Silymarin in INH induced toxicity in order to strengthen the hypothesis that NAC has a greater hepatoprotective effect as compared to Silymarin in INH induced hepatotoxicity.

CONFLICTS OF INTEREST

The author(s) declare(s) that there is no conflict of interest regarding the publication of this article

REFERENCES

1. Sgro C, Clinard F, Ouazir K, Chanay H, Allard C, Guilleminet C, et al. Incidence of drug-induced hepatic injuries: A French population-based study. *Hepatology*. W.B. Saunders; 2002 Aug 1 ;36(2):451–5.
2. Ostapowicz G, Fontana RJ, Schiødt FV, Larson A, Davern TJ, Han SHB, et al. Results of a Prospective Study of Acute Liver Failure at 17 Tertiary Care Centers in the United States. *Ann Intern Med* [Internet]. American College of Physicians; 2002 Dec 17 [cited 2017 Dec 24];137(12):947. DOI: 10.7326/0003-4819-137-12-200212170-00007
3. WHO | Tuberculosis. WHO. World Health Organization; 2017. Website: <http://www.who.int/mediacentre/factsheets/fs104/en/>
4. Salpeter SR. Fatal isoniazid-induced hepatitis. Its risk during chemoprophylaxis. *West J Med*. BMJ Publishing Group 1993 Nov ;159(5):560–4. 5. Chowdhury A, Santra A, Bhattacharjee K, Ghatak S, Saha DR, Dhali GK. Mitochondrial oxidative stress and permeability transition in Isoniazid and Rifampicin induced liver injury in mice. *J Hepatol* 2006 Jul ;45(1):117–26.
6. Ben Mahmoud L, Ghazzi H, Kamoun A, Hakim A, Hachicha H, Hammami S, et al. Polymorphism of the N-acetyltransferase 2 gene as a susceptibility risk factor for antituberculosis drug-induced hepatotoxicity in Tunisian patients with tuberculosis. *Pathol Biol* 2012 Oct ;60(5):324–30.
7. Shaker E, Mahmoud H, Mnaa S. Silymarin, the antioxidant component and Silybum marianum extracts prevent liver damage. *Food Chem Toxicol* 2010 Mar ;48(3):803–6.
8. Hur GM, Ryu YS, Yun HY, Jeon BH, Kim YM, Seok JH, et al. Hepatic Ischemia/Reperfusion in Rats Induces iNOS Gene Transcription by Activation of NF- κ B. *Biochem Biophys Res Commun*. Academic Press; 1999 Aug 11 ;261(3):917–22.
9. Muruganandan S, Sinal C. Mice as Clinically Relevant Models for the Study of Cytochrome P450-dependent Metabolism. *Doi.org/10.1038/clpt.2008.50*

10. Lee KS, Oh SJ, Kim HM, Lee KH, Kim SK. Assessment of reactive metabolites in drug-induced liver injury. *Arch Pharm Res* 2011 Nov 3;34(11):1879–86.
11. Chen M, Bisgin H, Tong L, Hong H, Fang H, Borlak J, et al. Toward predictive models for drug-induced liver injury in humans: are we there yet? *Biomark Med. Future Medicine Ltd London, UK*; 2014 Feb 12;8(2):201–13.
12. Bouazzi O El, Hammi S, Bourkadi JE, Tebaa A, Tanani DS, Soulaymani-Bencheikh R, et al. First line anti-tuberculosis induced hepatotoxicity: incidence and risk factors. *Pan Afr Med J* 2016;25:167.
13. Ramachandran G, Swaminathan S. Safety and Tolerability Profile of Second-Line Anti-Tuberculosis Medications. *Drug Saf* 2015 Mar 13;38(3):253–69.
14. Hunt CM. Mitochondrial and immunoallergic injury increase risk of positive drug rechallenge after drug-induced liver injury: A systematic review. *Hepatology. Wiley Subscription Services, Inc., A Wiley Company*; 2010 Dec 1;52(6):2216–22.
15. Sharma SK, Singla R, Sarda P, Mohan A, Makharia G, Jayaswal A, et al. Safety of 3 Different Reintroduction Regimens of Antituberculosis Drugs after Development of Antituberculosis Treatment-Induced Hepatotoxicity. *Clin Infect Dis. Oxford University Press*; 2010 Mar 15;50(6):833–9.
16. Zimmerman HJ. Drug-induced liver disease. *Clin Liver Dis.* 2000 Feb;4(1):73–96, vi.
17. Kabbara WK, Sarkis AT, Saroufim PG. Acute and Fatal Isoniazid-Induced Hepatotoxicity: A Case Report and Review of the Literature. *Case Rep Infect Dis. Hindawi Limited*; 2016;2016:3617408.
18. Velayudham LS, Farrell GC. Drug-induced cholestasis. *Expert Opin Drug Saf* 2003 May ;2(3):287–304.
19. Attri S, Rana SV, Vaiphei K, Sodhi CP, Katyal R, Goel RC, et al. Isoniazid- and rifampicin-induced oxidative hepatic injury — protection by N-acetylcysteine. *Hum Exp Toxicol* 2000 Sep 1;19(9):517–22.
20. Richards VE, Chau B, White MR, McQueen CA. Hepatic Gene Expression and Lipid Homeostasis in C57Bl/6 Mice Exposed to Hydrazine or Acetylhydrazine. *Toxicol Sci* 2004 Jul 22 ;82(1):318–32.
21. Chowdhury A, Santra A, Bhattacharjee K, Ghatak S, Saha DR, Dhali GK. Mitochondrial oxidative stress and permeability transition in Isoniazid and Rifampicin induced liver injury in mice. *J Hepatol* 2006 Jul ;45(1):117–26.
22. Yue J, Peng R, Yang J, Kong R, Liu J. CYP2E1 mediated INH-induced hepatotoxicity in rats. *Acta Pharmacol Sin* 2004 May;25(5):699–704.
23. Muruganandan S, Sinal C. Mice as Clinically Relevant Models for the Study of Cytochrome P450-dependent Metabolism. [Doi.org/10.1038/clpt.2008.50](https://doi.org/10.1038/clpt.2008.50)
24. Metushi IG, Nakagawa T, Utrecht J. Direct oxidation and covalent binding of isoniazid to rodent liver and human hepatic microsomes: humans are more like mice than rats. *Chem Res Toxicol* 2012 Nov 19;25(11):2567–76.
25. Schnell MA, Hardy C, Hawley M, Probert KJ, Wilson JM. Effect of Blood Collection Technique in Mice on Clinical Pathology Parameters. *Hum Gene Ther* 2002 Jan 1;13(1):155–61.
26. Baratta JL, Ngo A, Lopez B, Kasabwalla N, Longmuir KJ, Robertson RT. Cellular organization of normal mouse liver: a histological, quantitative immunocytochemical, and fine structural analysis. *Histochem Cell Biol* 2009 Jun 3;131(6):713–26.
27. Chen X, Xu J, Zhang C, Yu T, Wang H, Zhao M, et al. The protective effects of ursodeoxycholic acid on isoniazid plus rifampicin induced liver injury in mice. *Eur J Pharmacol* 2011 May ;659(1):53–60.
28. Rafiq S, Jehangir A, Medical SI-J of II. Hepatoprotective Effect of Aqueous Extract of Stem Bark of Berberis Lycium Royale in Isoniazid Induced Hepatotoxicity in Mice. [jiimc.riphah.edu.pk. https://jiimc.riphah.edu.pk/wp-content/uploads/2014/08/JIIMC-December-2015-Final-new.pdf#page=22](https://jiimc.riphah.edu.pk/wp-content/uploads/2014/08/JIIMC-December-2015-Final-new.pdf#page=22)
29. Zazuli Z, Barliana MI, Mulyani UA, Perwitasari DA, Ng H, Abdulah R. Polymorphism of PXR gene associated with the increased risk of drug-induced liver injury in Indonesian pulmonary tuberculosis patients. *J Clin Pharm Ther* 2015 Dec 1;40(6):680–4.
30. Jahan S, Khan M, Imran S, Assoc MS-JPM, 2015 undefined. The hepatoprotective role of Silymarin in isoniazid induced liver damage of rabbits. [jpma.org.pk. https://www.jpma.org.pk/PdfDownload/7375.pdf](https://www.jpma.org.pk/PdfDownload/7375.pdf)
31. Baniyasi S, Eftekhari P. Protective effect of N-acetylcysteine on antituberculosis drug-induced hepatotoxicity. [journals.lww.com. Doi.org/10.1097/MEG.0b013e32833aa11b](https://doi.org/10.1097/MEG.0b013e32833aa11b)
32. Singh M, Sasi P, Gupta VH, Rai G, Amarapurkar DN, Wangikar PP. Protective effect of curcumin, silymarin and N -acetylcysteine on antitubercular drug-induced hepatotoxicity assessed in an in vitro model. *Hum Exp Toxicol. SAGE PublicationsSage UK: London, England*; 2012 Aug 8;31(8):788–97.
33. Klemens SP, DeStefano MS, Cynamon MH. Therapy of multidrug-resistant tuberculosis: lessons from studies with mice. *Antimicrob Agents Chemother* 1993 Nov 1;37(11):2344-7.
34. Lian Y, Zhao J, Xu P, Wang Y, Zhao J, Jia L, Fu Z, Jing L, Liu G, Peng S. Protective effects of metallothionein on isoniazid and rifampicin-induced hepatotoxicity in mice. *PloS One* 2013 Aug 13;8(8):e72058.
35. Upadhyay G, Kumar A, Singh MP. Effect of silymarin on pyrogallol- and rifampicin-induced hepatotoxicity in mouse. *Eur J Pharmacol* 2007 Jun 22;565(1-3):190-201.
36. Girish C, Koner BC, Jayanthi S, Ramachandra Rao K, Rajesh B, Pradhan SC. Hepatoprotective activity of picroliv, curcumin and ellagic acid compared to silymarin on paracetamol induced liver toxicity in mice. *Fund Clin Pharmacol* 2009 Dec;23(6):735-45.
37. Zwingmann C, Bilodeau M. Metabolic insights into the hepatoprotective role of N-acetylcysteine in mouse liver. *Hepatology* 2006 Mar;43(3):454-63.