

Comparative Study on Antihyperglycemic and Antihyperlipidemic Effects of Separate and Composite Extract of Seed of *Eugenia jambolana* and Root of *Musa paradisiaca* in Streptozotocin-Induced Diabetic Male Albino Rat

CHHANDA MALLICK, RAJKUMAR MAITI AND DEBIDAS GHOSH

For author affiliations, see end of text.

Received November 7, 2005; Revised March 15, 2006; Accepted March 16, 2006

This paper is available online at <http://ijpt.iuims.ac.ir>

ABSTRACT

Herbal medicine development against the non-communicable disease like diabetes is one of the thrust area of research in the field of global medicine. Here we have studied the separate and composite methanolic extract of seed of *Eugenia jambolana* and root of *Musa paradisiaca* for the management of streptozotocin-induced diabetes mellitus. We have measured the fasting blood glucose level and glycogen content in liver as well as in skeletal muscle. Hyperglycemia and hyperlipidemia are two important characters of diabetes mellitus. Hyperlipidemia developed in these experimental diabetic rats was assessed by quantification of total cholesterol (TC), high-density lipoprotein cholesterol (HDLc), low-density lipoprotein cholesterol (LDLc) and triglyceride (TG) in serum. We noted that after treatment of methanolic extract of above plant parts in separate as well as in composite manner in streptozotocin-induced diabetic rat resulted a significant remedial effect on blood glucose level as well as in the quantity of liver and skeletal muscle glycogen. Serum insulin level that was diminished in streptozotocin-induced diabetic state was recovered significantly after the co-administration of extract of above plant parts. Serum lipid profile was also corrected significantly in streptozotocin induced diabetic rats after the composite extract co-administration. The recovery in all the above-mentioned parameters was more effective when we use the composite extract in comparison to the separate extract of above plant parts. None of the extract has any metabolic toxicity induction in general. So the composite extracts of above plant parts have some remedial effects against streptozotocin-induced diabetic state.

Keywords: Herbal extract, Diabetes mellitus, Lipid profile, Insulin, Transaminases

Diabetes mellitus is a syndrome, associated with hyperglycemia [1, 2], hyperlipidemia, oxidative stress, polyurea, polyphagia, polydypsia, ketosis, nephropathy, neuropathy and cardiovascular disorders [3]. From literature review it has been noted that hyperlipidemia is associated with diabetes [4]. In modern medicine no satisfactory effective therapy is yet available to cure diabetes mellitus. Though insulin therapy is used for management of diabetes mellitus but there are several drawbacks like insulin resistance [5], anorexia nervosa, brain atrophy and fatty liver [6] along with requirement for refrigeration of the drug and skilled technician as well as of its high cost, which are not affordable in poor economic community. Chronic treatment with sulfony-

lureas and biguanides are also associated with side effects [7]. In India, use of herbal drugs based on Ayurveda is very commonly practiced from long ago and it is less expensive. The herbal drugs which we are considered frequently are of less toxicity with fewer side effects compared with synthetic drugs [8,9]. For such reasons, at present traditional and complementary medicine has seen an upsurge in its popularity for the treatment of different diseases. The National Centre for Complementary and Alternative Medicine which was established in 1998 by the United States Government. Here herbal medicine development is one of the important subjects of study [10, 11]. Though there are few reports on anti-diabetic activity of *Eugenia jambolana* (*E. jambolana*)

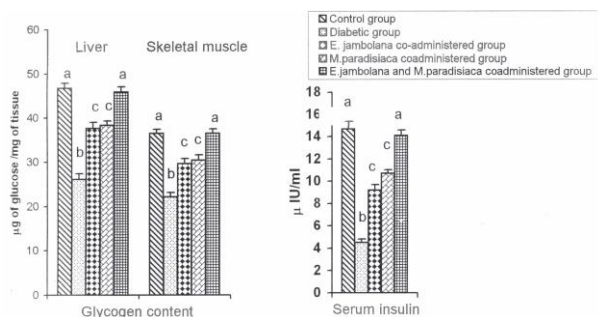


Fig 1. Resettlement of glycogen content in liver and skeletal muscles as well as serum insulin level to matched control group after co-administration of composite extract and significant recovery of these parameter after co-administration of individual extract of seed of *E. jambolana* and root of *M. paradisiaca* in streptozotocin induced diabetic male albino rat. Data are expressed as mean \pm SEM, n=8. ANOVA followed by multiple comparison two tail 't' test. Bar with different superscripts (a,b,c) differ from each other significantly ($p < 0.05$)

but till now no work has been performed to find out the hypoglycemic effect of *E. jambolana* and *Musa paradisiaca* (*M. paradisiaca*) in composite way. In Indian system of folk medicine, more than one plant in combined way are used for the correction of health disorders and this composite plant extract in the form of tonic or mixture exhibits a better results than single plant extract treatment [12,13]. Moreover hyperlipidemia is developed in diabetic state [14] and there is no report about hyperlipidemic potency of these plants in individual or in composite manner. On that background we used here the composite mixture of these two-plant materials for the management of diabetes mellitus.

E. jambolana is used as traditional medicine for the management of diabetes [15]. This plant is large evergreen tree up to 3.6 m girth and 30 m high. Bark is pale brown, slightly rough on old stems with shallow cracks. Fruits are variable in size, up to 2.5 cm long, ellipsoid or oblong structures. It is found all over India. It belongs to the myrtaceae family. Jambu bark cures hemorrhages, burning sensation, dysentery, diarrhea, diabetes, excessive thirst, dyspepsia, cough and asthma and is used in preparation of astringent decoction for gargles and washes [16]. Fruit is useful astringent in bilious diarrhea. Seeds are used for the treatment of diabetes [16].

M. Paradisiaca (Banana) is a tree like herb with thick stem composed of convolute leaf sheaths, Leaves are very large and oblong. It is distributed throughout India and Malaysia. And belong to the musaceae family. Roots of *M. paradisiaca* are antihelminthic [15]. Flowers are astringent [16]. Banana fruit is mild laxative. It aids in combating diarrhea and dysentery and promotes healing of intestinal lesions in ulcerative colitis [16]. It is useful in celiac disease, constipation and peptic ulcer. Banana powder is effective in treatment of celiac disease [16]. Unripe fruit and cooked flower are useful in diabetes [16].

The aim of this study was to find out the antihyperglycemic potencies of *E. jambolana* and *M. paradisiaca* in individual and in composite manner in diabetic state and to focus the scientific basis of this folk medicine.

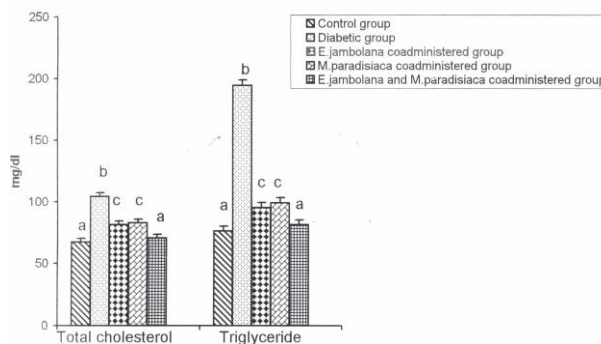


Fig 2. Better efficacy of composite methanolic extract in respect to individual extract of seed of *E. jambolana* and root of *M. paradisiaca* for resettlement of serum total cholesterol (TC) and serum triglyceride (TG) level towards the matched control in streptozotocin induced diabetic rat. Data are expressed as Mean \pm SEM, n=8. ANOVA followed by multiple comparison two tail 't' test. Bar with different superscripts (a,b,c) differ from each other significantly ($p < 0.05$)

MATERIALS AND METHODS

Selection of Animal and Animal Care

Forty matured Wistar strain male albino rats (Chakraborty Traders, Midnapore, India) of 3 month of age weighing about 150 ± 10 g were taken for this experiment. Animals were acclimatized for a period of 15 day to our laboratory conditions prior to the experiment. Rats were housed in colony cage (4 rats per cage) at an ambient temperature of $25 \pm 2^\circ\text{C}$ with 12 h light: 12 h dark cycle. Rats had free access to standard food and water. The principles of laboratory animal care (NIH 1985) were followed through out the duration of experiment and instruction given by our institutional ethical committee was followed regarding injection and other treatment of experiment. Normoglycemic animals were selected for this experiment having fasting blood glucose level of 70-80 mg/dL.

Chemicals

Streptozotocin was obtained from spectrochem Pvt. Ltd chemical company (India). Insulin enzyme linked immunosorbant assay (ELISA) kit purchased from Boehringer Mannheim Diagnostic, Mannheim (Germany).

Induction of Diabetes Mellitus

Rats were fasted for 24 h before the induction of diabetes by streptozotocin (STZ) injection. Single intramuscular injection of freshly prepared solution of STZ at the dose of 4.0 mg/0.1 mL of citrate buffer/100 g body weight/rat was performed. This single dose of STZ produce type I diabetes (having fasting blood sugar level more than 250 mg/dL) after 24 h of STZ injection and this diabetic state was maintained through out the experimental schedule.

Plant Material

The seeds of *E. jambolana* and root of *M. paradisiaca* were collected from Midnapore, district Paschim Midnapore, West Bengal in the month of June and the materials were identified by taxonomist of Botany De-

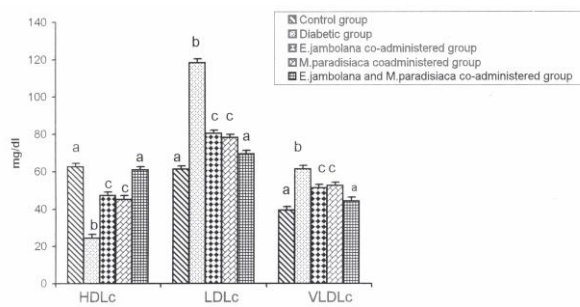


Fig 3. Resettlement of serum HDLc, LDLc and VLDL levels to the matched control after composite methanolic extract coadministration and significant recovery was noted after coadministration of separate extract of seed of *E.jambolana* and root of *M .paradisiaca* in streptozotocin induced diabetic male albino rat. Data are expressed as mean \pm SEM, n=8. ANOVA followed by multiple comparison two tail 't' test. Bar with different superscripts (a, b, c) differ from each other significantly ($p<0.05$)

partment, Vidyasagar University, Midnapore. A voucher specimen was deposited in the Department of Botany, Vidyasagar University, and the voucher specimen numbers are HPCCH No-6, 7. Please indicate which no belongs to which plant.

Preparation of Extract of *E. Jambolana*

Fresh seeds of *Eugenia jambolana* were collected from rural areas in the month of June. These are dried in an incubator for 2 days at 40 °C, crushed in an electric grinder and then powdered. Out of this powder, 50 g was suspended in 250 mL of methanol and incubated at 37 °C for 36 h. The slurry was stirred intermittently for 2 h and left overnight. The mixture was then filtered and filtrate was dried by low pressure and residue was collected. When required the residue was suspended in olive oil in a fixed dose and used for treatment.

Preparation of Extract of *M. Paradisiaca*

Roots of *M. paradisiaca* are cut into small pieces and dried in an incubator for 2-3 days at 40 °C, crushed in an electric grinder and then powdered. From this powder 50 g was suspended in 250 mL of methanol and incubated at 37 °C for 36 h. To prepare the extract the same procedure was followed as for the *E. jambolana*.

Experimental Procedure

Forty rats were divided into five groups as follows.

Group I: Control group. Rats of this group received single intramuscular injection of citrate buffer (0.1 mL/100 g body weight/rat).

Group II: Diabetic group. Diabetes was induced in rats of this group by single intramuscular injection of streptozotocin at the dose of (4 mg/0.1 mL citrate buffer/100 g body weight/rat).

Group III: *E. jambolana* co-administered group. The diabetic rats of this group were forcefully fed by gavage method with methanolic extract of seed of *E. jambolana* at the dose of 80 mg/0.5 mL olive oil/100 g body weight/rat/day after 24 h of STZ injection for 14 days at fasting state.

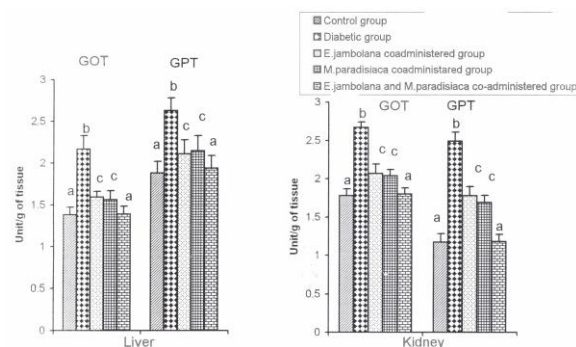


Fig 4. Better protection of hepatic and renal GOT and GPT activity after composite extract coadministration in respect to individual extract co-administration of seed of *E. jambolana* and root of *M. paradisiaca* in streptozotocin induced diabetic male albino rat. Data are expressed as mean \pm SEM, n=8. ANOVA followed by multiple comparison two tail 't' test. Bar with different superscripts (a, b, c) differ from each other significantly ($p<0.05$)

Group IV: *M. paradisiaca* co-administered group. Streptozotocin induced diabetic rats were forcefully fed by gavage with methanolic extract of root of *M. paradisiaca* at the dose of 80 mg/0.5 mL olive oil/100 g body weight/rat/day for 14 days.

Group V: *E. jambolana* and *M. paradisiaca* co-administered group. The diabetic rats of this group were forcefully fed by gavage with methanolic extract of seeds of *E. jambolana* and *M. paradisiaca* in composite manner at the dose of 80 mg (1:1)/ 0.5 mL olive oil/100 g body weight / rat for 14 days.

Co-administration of above plant extract in-group III, IV and V was performed at early morning and at fasting state.

Animals of control (group I) and diabetic groups (group II) were subjected to forceful feeding of 0.5 mL of olive oil/100 g body weight /day for 14 day at the time of extract supplementation to the animals of group III, IV and V to keep all the animal in same experimental condition.

From the starting day of extract supplementation to diabetic rats, fasting blood sugar level of rats in all groups was measured by single touch glucometer at the interval of two days.

On 16th day of experiment, all the animals were sacrificed by decapitation after recording the final body weight. Blood was collected from dorsal aorta and serum was separated by centrifugation at 3000 g for 5 min for the assay of insulin followed by ELISA technique and for the measurement of serum lipid profile. Liver, skeletal muscle (gastrocnemius) were dissected out and stored at -20°C for biochemical analysis of glycogen content in liver and skeletal muscle.

Testing of Fasting Blood Glucose Level

At the time of grouping of the animals, fasting blood glucose (FBG) level was measured. At the interval of two days, FBG was further recorded from all the animals of all groups throughout the experimental duration. Blood was collected from the tip of tail vein and FBG level was measured by single touch glucometer.

Biochemical Assay of Glycogen Content in Liver and Muscle

Glycogen levels in liver and skeletal muscle were measured according to the standard protocol [17]. Hepatic and skeletal muscular tissues were homogenized separately in hot 80% ethanol at the tissue concentration of 100 mg/mL and then centrifuged at $8000 \times g$ for 20 min. The residue was collected and allowed to dry over a water bath. To the residue, 5ml of distilled water and 6ml of 52% perchloric acid were added. The extraction was done at 0°C for 20 min. The collected material was centrifuge at $8000 \times g$ for 15 min and supernatant was collected. From the collected supernatant, 0.2 mL was transfer in graduated test tube and volume was made up to 1 mL by the addition of distilled water. Graded standards were prepared by using 0.1, 0.2, 0.4, 0.6, 0.8 and 1.0 mL of working standard solution and volume of all these standards were made upto 1ml by addition of distilled water. In all the test tubes 4 mL of anthrone reagent was added. The test tubes were heated in boiling water bath for 8 minutes. Then these were allowed to cool at room temperature and the intensity of green to dark green color of the solution was recorded at 630 nm. The amount of glycogen content was measured from standard curve prepared with standard glucose solution. The amount of glycogen in tissue sample was expressed in μg of glucose per mg of tissue.

Serum Total Cholesterol

Serum total cholesterol was quantified by spectrophotometric method [18] by the addition of enzyme present in reagent kit. The absorbance of red quinoneimine complex was determined at 505 nm. The value of TC present in serum was expressed in mg/dL.

Serum Lipoprotein Cholesterol

Serum LDLc and VLDLc were measured according to protocol of Friendswald et al [19]. Other lipoprotein like HDLc was measured by the method of Waenic et al [20].

Serum Triglyceride

Serum triglyceride was measured by using kit. The absorbance was noted at 520 nm. The value was expressed in the unit of mg/dL [21].

Serum Insulin Level

Serum insulin was measured by enzyme linked immunosorbant assay (ELISA) using the kit [22] (Boehringer Mannheim Diagnostic, Mannheim, Germany). The intra assay variation was 4.9%. As the samples was run at a time, so there is no inter assay variation. The insulin level in serum was expressed in $\mu\text{IU/mL}$.

Biochemical Assay of Glutamate Oxalate Transaminase (GOT) and Glutamate Pyruvate Transaminase (GPT) in Liver and Kidney

Liver and kidney tissues were homogenized separately in ice cold of 0.1M-phosphate buffer (pH=7.4) at the tissue concentration of 50 mg/mL. For the mea-

surement of liver and kidney GOT and GPT, kits were used supplied by Crest Biosystems, Gitanjali, Dr. Antonio Do Rego Bagh, Alto Santacruz, Bambolim Complex (Goa, India). The activities of these enzymes were expressed as unit per gram of tissue [23].

Statistical Analysis

Analysis of variance (ANOVA) followed by multiple two-tail 't' test was used for statistical analysis of collected data [24]. Differences were considered significantly at $p < 0.05$.

RESULTS

Body Weight

Body weight was decreased significantly in streptozotocin-induced diabetic rats with respect to control. After the supplementation of methanolic extract of seed of *E. jambolana* and root of *M. paradisiaca* in separate manner, this parameter recovered significantly towards the control level. Body weight of the animal of composite extract treated group was not significantly different from the control (Table 1).

Fasting Blood Glucose Level

There was a significant elevation in fasting blood glucose level after a single dose of streptozotocin compared to control. This parameter came towards the control level gradually after supplementation of methanolic extract of seed of *E. jambolana* as well as root of *M. paradisiaca* in separate way but more significant recovery in duration dependent fashion was noted after supplementation of composite extract (Table 2).

Glycogen Content

Significant diminution was noted in the level of glycogen in liver and skeletal muscle in diabetic group with respect to control. After supplementation of above mentioned plant extracts in separate manner to the diabetic animal, there was a significant recovery in this parameter when compare to the diabetic group. Glycogen levels in above-mentioned tissues were restored to the control level after supplementation of composite extract of above plants (Fig 1).

Serum Insulin Level

Serum insulin level decreased significantly in di-

Table 1. Effect of separate and composite methanolic extract of seed of *E. jambolana* and root of *M. paradisiaca* on body growth in streptozotocin-induced diabetic rats. Data are expressed as Mean \pm SEM, n=8. ANOVA followed by multiple comparison two tail 't' test. Values with different superscript (a,b,c) in each vertical column differ from each other significantly ($p < 0.05$).

	Body Weight (g)	
	Initial	Final
Control group	150.11 \pm 5.1 ^a	170.67 \pm 4.2 ^a
Diabetic group	152.07 \pm 5.2 ^a	122.33 \pm 5.2 ^b
<i>E. jambolana</i> co-administered group	151.67 \pm 5.8 ^a	148.16 \pm 4.1 ^c
<i>M. paradisiaca</i> co-administered group	153.33 \pm 5.3 ^a	151.12 \pm 4.1 ^c
<i>E. jambolana</i> and <i>M. paradisiaca</i> co-administered group	151.21 \pm 5.2 ^a	169.23 \pm 3.8 ^a

Table 2. Better remedial effect composite methanolic extract of seed of *E. jambolana* and root of *M. paradisiaca* in respect to individual extract of these plant parts on fasting blood glucose level after 24 hrs of streptozotocin injection followed by assessment of parameter at the interval of 2 days throughout the experimental schedule in diabetic rats. Data are expressed as Mean \pm SEM, n=8. ANOVA followed by multiple comparison two-tail 't' test. Values with different superscript (a,b,c,d) in each vertical column differ from each other significantly ($p < 0.05$).

	Fasting blood glucose level (mg/dL)						
	0 day	1 st day	4 th day	7 th day	10 th day	13 th day	16 th day
Control group	76.21 \pm 4.8 ^a	76.51 \pm 4.2 ^a	76.42 \pm 4.6 ^a	75.51 \pm 4.2 ^a	78.21 \pm 5.1 ^a	78.14 \pm 4.6 ^a	77.27 \pm 4.3 ^a
Diabetic group	78.32 \pm 5.2 ^a	294.31 \pm 5.3 ^b	347.41 \pm 4.2 ^b	319.42 \pm 5.2 ^b	357.00 \pm 5.0 ^b	380.17 \pm 4.2 ^b	421.21 \pm 4.0 ^b
<i>E. jambolana</i> coadministered group	76.54 \pm 4.3 ^a	296.26 \pm 6.2 ^b	271.31 \pm 4.1 ^c	253.41 \pm 4.4 ^c	185.32 \pm 4.1 ^c	173.18 \pm 3.8 ^c	125.32 \pm 3.0 ^c
<i>M. paradisiaca</i> coadministered group	79.11 \pm 4.1 ^a	298.21 \pm 5.9 ^b	273.41 \pm 4.2 ^c	251.45 \pm 4.3 ^c	176.24 \pm 4.8 ^c	165.34 \pm 4.0 ^c	132.41 \pm 3.1 ^c
<i>E. jambolana</i> and <i>M. paradisiaca</i> coadministered group	77.64 \pm 4.2 ^a	296.25 \pm 3.9 ^b	250.32 \pm 5.1 ^d	162.21 \pm 4.1 ^d	110.54 \pm 3.9 ^d	94.34 \pm 3.5 ^d	80.12 \pm 4.9 ^a

abetic group compared to control. After 14 days treatment with these two-plant extract in separate way there was a significant elevation in serum insulin level towards control. This parameter resettled to the control level after supplementation of composite extract (Fig 1).

Serum Lipid Profile

Serum total cholesterol (TC) and triglyceride (TG) levels were significantly elevated in diabetic group in comparison to control (Fig 2). After treatment with these plants extract in separate way, serum TC and TG levels significantly recovered towards the control. After supplementation of composite extract to the diabetic animal, the above parameters were not significantly different from control (Fig 2).

Other hyperlipidemic parameters like serum LDLc and VLDLc, were elevated in diabetic group with respect to control (Fig 3). The levels of above mentioned parameters recovered significantly when compare to diabetic group after supplementation of individual extract. There was no significant difference when the above parameters in above-mentioned tissues were compared between control and composite extract supplemented groups (Fig 3).

In diabetic group HDLc, the Friendly lipoprotein was decreased in serum with respect to control (Fig 3). There was a significant recovery in above parameter after supplementation of individual extract of above plants to the diabetic animals in comparison to STZ induced diabetic group. After supplementation of composite extract to the diabetic animal, the level of this parameter was not significantly different from control (Fig 3).

Glutamate Oxaloacetate Transaminase (GOT) and Glutamate Pyruvate Transaminase (GPT) Level in Liver and Kidney

Hepatic and renal GOT and GPT levels were increased significantly in diabetic group with respect to control group. These two parameters in both liver and kidney were restored towards the control level after the supplementation of methanolic extract of seeds of *E. jambolana* and root of *M. paradisiaca* in separate manner and more significant result was noted in case of composite extract treatment (Fig 4).

DISCUSSION

The present study deals with two dimensions for antidiabetogenic effects of the plant extract of *E. jambolana* and *M. paradisiaca* in separate and in composite way. In one dimension, the fasting blood glucose level and glycogen content in liver and skeletal muscle were measured. In other dimension antihyperlipidemic potency of these plant extracts were studied as there is a close correlation between hyperglycemia and hyperlipidemia [25].

Here we selected the STZ induced hyperglycemia as an experimental model because it is one of the best models to study the effect of the antidiabetogenic agent [26].

Table 2. Better remedial effect composite methanolic extract of seed of *E. jambolana* and root of *M. paradisiaca* in respect to individual extract of these plant parts on fasting blood glucose level after 24 hrs of streptozotocin injection followed by assessment

The specific dose of the extract used and duration of the treatment adopted here were selected by trial and error where good promising results were noted without any metabolic toxicity induction.

Supplementation of the composite and separate extract of these plants parts resulted a significant correction of fasting blood glucose (FBG) level with respect to STZ induced diabetic group and this recovery was more effective when treatment of composite extract was used which primarily focuses on the antidiabetic activity of these plant products. The actual mechanism of such antidiabetogenic activity is not clear from this study but, following possible dimensions may be enlightened.

In STZ induced diabetes, glycogen level in liver and skeletal muscle were diminished which is consistent to other reports [27] and may be due to low level of insulin [28]. After the extract supplementation in diabetic rat, there was a significant recovery in hepatic and skeletal muscle glycogen level towards the control level where the degree of recovery was more significant after composite extract administration. These findings suggest that one of the possible mechanisms of antidiabetogenic action of these extracts is modulating glycogen metabolism.

The above parameters, which were recovered, showed a more potent correction after composite extract

treatment and this was equal to control, which may be due to the insulinotropic effect of this extract. Moreover the effects of these plant on the management of diabetes is also consistent to some previous worker who used the above plants separately [28-30].

Diabetes is also associated with hyperlipidemia [14]. Serum TC and TG have been decreased significantly in diabetic rats after extract supplementation. These effects may be due to low activity of cholesterol biosynthesis enzymes and or low level of lipolysis that are under the control of insulin [31]. This extract supplementation also resulted in significant attenuation in the level of LDLc and HDLc in serum towards the control level, which again strengthen the hypolipidemic effect of this extract.

In order to determine if the plant extracts used here, had any toxicity in general, we measured hepatic and renal GOT and GPT activities which are important indicators of general toxicity [32]. There was significant diminution in these parameters after separate and composite extract treatment in respect to diabetic group, which suggest that these plant extracts did not cause any toxicity induction and recovered the general toxicity that is noted in diabetic state.

Thus our study showed that administration of composite extract of *E. jambolana* and *M. paradisiaca* was more effective than individual extract to manage diabetes mellitus. The active ingredient(s) present here may recover the disorders in carbohydrate metabolism noted in diabetic state by stimulating existing β cell or by increasing the rate of β cell regeneration or by modulating intracellular glucose utilization. The actual mechanism is not clear and further biochemical and pharmacological investigations are needed to isolate and identify the active ingredient(s) in the composite extract.

REFERENCES

- Georg P, Ludvik B. Lipids and Diabetes. *J Clin Basic Cardiol*. 2000;3:159-62.
- Nyholm B, Porsen N, Juhl CB, Gravholt CH, Butler PC, Weeke J, Veldhuis JD, Pincus S, Schmitz O. Assessment of insulin secretion in relatives of patients with type 2 (non- insulin dependent) diabetes mellitus: Evidence of early β cell dysfunction. *Metabolism*. 2000;49:896-905.
- Gandjbakhch I, Leprince P, D'Alessandro C, Ouattara A, Bonnet N, Varvous S, Pavie A. Coronary artery bypass graft surgery in patients with diabetes. *Bull Acad Natl Med*. 2005;189:257-66.
- Pushparaj P, Tan CH, Tan BKH. Effect of Averrhoa bilimbi leaf extract on blood glucose and lipids in streptozotocin-diabetic rats. *J Ethnopharmacol*. 2000;72:69-76.
- Piedrola G, Novo E, Escobar F, Garcia-Robles R. White blood cell count and insulin resistance in patients with coronary artery disease. *Ann Endocrinol*. 2001;62:7-10.
- Yaryura-Tobias JA, Pinto A, Neziroglu F. Anorexia nervosa, diabetes mellitus, brain atrophy, and fatty liver. *Int J Etiol Disorders* 2001;30:350-3.
- Rang HP, Dale MM, Ritter JM. The endocrine system pharmacology. In: Pharmacology. LongmanGroup Ltd, UK, 1991; p. 504-8.
- Geetha BS, Biju CM, Augusti KT. Hypoglycemic effects of leucodelphinidin derivative isolated from *Ficus bengalensis* (Linn.). *Ind J Pharmacol*. 1994;38:220-2.
- Rao BK, Sudarshan PR, Rajsekher MD, Nagaraju N, Rao CA. Antidiabetic activity of Terminalia pallida fruit in alloxan induced diabetic rats. *J Ethnopharmacol*. 2003;85:169-72.
- Yoon SL, Horne CH, Adams C. Herbal product use by African American older women. *Clin Nurs Res*. 2004;13:271-88.
- Edwards OT, Colquist S, Maradiegue A. What's cooking with garlic: Is this complementary and alternative medicine for hypertension. *J Am Acad Nurse Pract*. 2005;17:381-5.
- Wu Y, Ahang Y, Wu JA, Lowell T, Gu M, Yuan CS. Effects of Erkang, a modified formulation of Chinese folk medicine Shi-Quan-Da-Tang, on mice. *J Ethnopharmacol*. 1998;61:153-9.
- Borchers AT, Stern JS, Hackman RM, Keen CL, Gershwin ME. Mushrooms tumors and immunity. *Proc Soc Exp Biol Med*. 1999;221:281-93.
- Maiti R, Das UK, Ghosh D. Attenuation of hyperglycemia and hyperlipidemia in streptozotocin induced diabetic rats by aqueous extract of seed of Tamarindus indica. *Biol Pharm. Bull* 2005;28:1172-6.
- Kirtikar KR, Basu BD. Eugenia Jambolana L, Musa paradisiaca L. Kirtikar KR, Basu BD. (eds), In: Indian Medicinal Plant. Volume IV. Periodical Experts Book Agency, Delhi, 1991; p.1048-55, 2452-6.
- Joshi S, Eugenia Jambolana L, Musa paradisiaca L. Joshi S. (eds), In: Medicinal Plants., Oxford & IBH Publishing Co. Pvt. Ltd, New Delhi, 2000; p. 286, 294.
- Sadasivam S, Manickam A. Carbohydrates. Sadasivam S, Manickam A. (eds), In: Methods in Biochemistry. New Age International Pvt. Ltd, New Delhi, 1996; p.11-2.
- Allain CC, Poon LS, Chan CSG. Enzymatic determination of total serum cholesterol. *Clin Chem*. 1974;20:470-5.
- Friendwald WT, Levy KJ, Frederickson DS. Estimation of concentration of LDL in plasma without of preparative ultracentrifuge. *Clin Chem*. 1972;18:499-502.
- Waenic RG, Albers JJ. A comprehensive evaluation of the heparin manganese precipitation procedure for estimating high density lipoprotein cholesterol. *J Lipid Res*. 1978;19:65-76.
- McGowan MW, Aritiss ZE, Strandbergh DR, Zak B. A peroxidase-coupled method for the colorimetric determination serum triglycerides. *Clin Chem*. 1983;29:538-42.
- Brugi W, Briner M, Fraken N, Kessler ACH. One step sandwich enzyme immuno assay for insulin using monoclonal antibodies. *Clin Biochem*. 1988;21:311-4.
- Henry RJ, Chiamori M, Golub OJ, Berkman S. Revised spectrophotometric methods for the determination of glutamate oxaloacetic transaminase, glutamic pyruvate transaminase and lactic acid dehydrogenase. *Am J Clin Pathol*. 1960;34:381-98.
- Sokal RR, Rohle FJ. Introduction to Analysis of Variance. Sokal RR, Rohle FJ. (eds), In: Biometry, WH Freeman and Company, New York, 1997; p.179-206.
- Cho SY, Park JY, Park EM, Choi MS, Lee MK, Jeon SM, Jang MK, Kim MJ, Park YB. Alteration of hepatic antioxidant enzyme activities and lipid profile in streptozotocin induces diabetic rats by supplementation of dandelion water extract. *Clin Chim Acta*. 2002;317:109-17.
- Carter SK, Broder L, Friedman M. Streptozotocin and metastatic insulinoma. *Ann Intern Med*. 1971;74:445-6.
- Grover JK, Vats V, Yadav S. Effect of feeding aqueous extract of *Petrocarpus marsupium* on glycogen content of tissues and the key enzymes of carbohydrate metabolism. *Mol Cell Biochem*. 2002;241:53-9.
- Lintus C, Cappelloni M, Adorisio S, Clementi A, Del Toma E. Effect of ripening on resistant starch and total sugar in *Musa paradisiaca sapientum*: glycaemic and insulinaemic responses in normal subjects and NIDDM patients. *Eur J Clin Nutr*. 1995;49:S303-6.
- Ojewole JA, Adewumi CO. Hypoglycemia effect of methanolic extract of *Musa paradisiaca* (Musaceae) green fruits in normal

and diabetic mice. *Methods Find Exp Clin Pharmacol.* 2003;25(6):453-6.

30. Khan B, Arayne MS, Naz S, Mukhtar N. Hypoglycemic activity of aqueous extract of some indigenous plants. *Pak J Pharm Sci.* 2005;18:62-4.
31. Sharma SB, Nasir A, Prabhu KM, Murthy PS, Dev G. Hypoglycemic and hypolipidemic effect of ethanolic extract of seed of *Eugenia jambolana* in alloxan induced diabetic rabbits. *J Ethnopharmacol.* 2003;85:201-6.
32. Ghosh S, Suryawanshi SA. Effect of *Vinca rosea* extracts in treatment of alloxan diabetes in male albino rats. *Ind J Exp Biol.* 2001;39:748-59.

CURRENT AUTHOR ADDRESSES

Chhanda Mallick, Reproductive Endocrinology and Family Welfare Research Unit, Department of Human Physiology with Community Health.

Rajkumar Maiti, Reproductive Endocrinology and Family Welfare Research Unit, Department of Human Physiology with Community Health.

Debidas Ghosh, Dr. Debidas Ghosh Reader & Head Bio-Medical Laboratory Science and Management Vidyasagar University, Midnapore-721 102. West Bengal, India. E-mail address: debidas_ghosh@yahoo.co.in (Corresponding Author).