

Protective Effect of *Falcaria vulgaris* Extract on Ethanol Induced Gastric Ulcer in Rat

MOZAFAR KHAZAEI, HOSSEIN SALEHI

For author affiliations, see end of text.

Received January 28, 2005; Revised April 2, 2006; Accepted April 30, 2006

This paper is available online at <http://ijpt.iums.ac.ir>

ABSTRACT

Falcaria vulgaris is a member of *Umbelliferae* family and is used for treatment of stomach disorders in the folk medicines of the west of Iran. This study was designed to evaluate the gastroprotective effect of *F. vulgaris* extract on ethanol (50%) induced gastric ulcers in rat. Thirty five young white male rats were divided to five groups (7 rats/ group). Three case groups received plant extract (50, 100, 150 mg/kg) and control negative and positive groups received distilled water and ranitidine respectively. Animals were killed and their stomachs were removed and macroscopic and microscopic ulcer index were determined. Data were subjected to one way ANOVA followed by Dennett's t-test. The results indicated that hydro alcoholic extract of *F. vulgaris* (50,100,150 mg/kg) significantly decreased the ulcer index ($p<0.05$) and these doses of extract exerted macroscopic curative ratios of 66.9%, 76.9% and 80.25% respectively. *F. vulgaris* extract has gastroprotective effect on ethanol-induced ulcer in rat.

Keywords: *Falcaria vulgaris*. Gastric ulcer, Protective effect, Ethanol

Falcaria vulgaris (Locally named Ghazzyaghi / Poghazeh) is a member of *Umbelliferae* family which grows near farmlands and is consumed as a vegetable in some regions of Iran. In the folk medicines of west of the country this herb is used for healing of skin ulcer, stomach disorders including peptic ulcer, liver diseases and stones of kidney and bladder [1, 2]. Phytochemical studies showed the presence of tannin and saponin and no flavonoids or terpenoid [3]. It also contains essence, vitamin C, phytoestrol, protein and starch [1, 2].

Ulcerative lesions of gastrointestinal tract are one of the major side effects associated with alcohol consumption [4]. Gastric ulcer is a benign lesion occurring at a site where the mucosal epithelium is exposed to acid, alcohol and pepsin. There are many products used for the treatment of gastric ulcers, including H₂-blockers, M₁-blockers, proton pump inhibitors which decrease secretion of acid, and sucralfate and carbenoxolone which provide mucosal defense. Although these drugs have brought about remarkable changes in ulcer therapy, their efficacy is still debatable. Report on clinical evaluation of these drugs show that there are incidences of adverse effects and drug interactions during ulcer therapy [5]. Thus, there is a need for more effective and less toxic antiulcer agents. Plant extracts are some of the most attractive sources of new drugs and have been

shown to produce promising results for the treatment of gastric ulcer [6].

To our knowledge, there were no scientific reports available in literature in support of the traditional claims of *F. vulgaris*. The present study is therefore an attempt to assess the efficacy of this indigenous herb for its gastroprotective effect in rats.

MATERIAL AND METHODS

Plant Material

F. vulgaris was identified and authenticated by a botanist (Mr. Caverizadeh, Biology Department, Razi University, Kermanshah, Iran). A voucher specimen has been kept for future reference. The clean leaves and stems were shade dried for 5 days and pulverized into powder [7].

Preparation of Extract

About 100 g of powder was extracted with 70% ethanol (Merck) by percolation. The ethanolic extract was completely dried under vacuum and then weighed and the residue was used in testing (a yield of 37%). The dried extract was dissolved in distilled water before gavage.

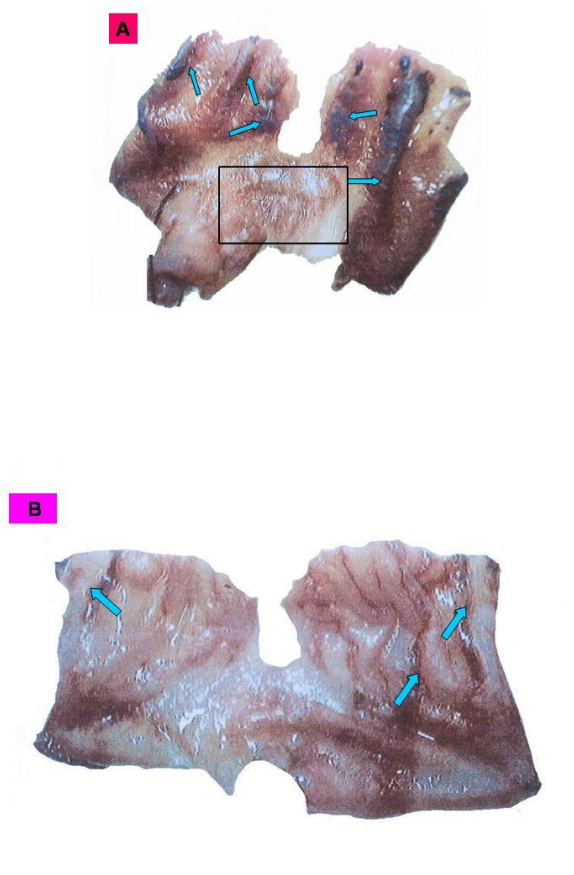


Fig 1. Macroscopic view of ethanol-induced longitudinal hemorrhagic bands (arrow) in glandular part of rat stomach (A); and ethanol effect on pretreated animal with extract (150 mg/kg) (B), nonglandular part of stomach is shown in square.

Animals

Male albino rats [Razi Institute of Iran] (200-250 g) were used; animals were maintained in cages with raised floors of wide wire mesh to prevent coprophagy and were housed in an ambient temperature of $22 \pm 1^\circ\text{C}$ in a 12 h light–dark cycle. They were fed a balanced diet and given free access to water. All animals were fasted for 48h before use to ensure an empty stomach [8]. During the fasting period rats received a nutritive solution of 8% sucrose in 0.2% NaCl to avoid excessive dehydration [96, 9]. This study was approved by the ethics committee for animal studies of medical faculty, Kermanshah University of Medical Sciences.

Acute Toxicity Test

The intraperitoneal acute toxicity (LD_{50}) of the extract was evaluated in Swiss albino mice as described by Miller and Tainted [10]. In brief, the method involved the administration of 5 different doses of the extract to 5 group of mice (6 mice/group). The mortality in each group was recorded within 24h. LD_{50} was estimated from the graph of percentage (%) mortality (converted to probit) against log-dose of the extract – probit 5 being 50%.

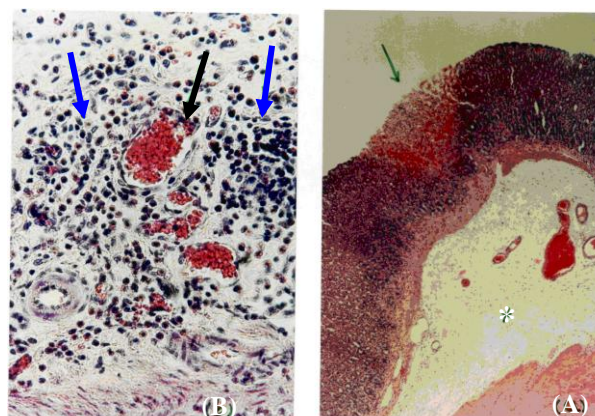


Fig 2. Microscopic view of ethanol-induced mucosal lesion (limited area) and submucosal edema*, $\times 40$ (A). Leukocyte infiltration (blue arrows) and venule expansion in lamina propria (black arrow), $\times 400$ (B).

Experiment Design

Three treatment groups received 50, 100, 150 mg/kg plants extract orally via a stainless steel intubation needle. Two doses were given at 08:00 and 16:00 and a third dose was given on the second day 1.5 h before induction of gastric ulceration [6]. As the same time as case groups: a negative control group was given distilled water (10 mL/kg) and a positive control group was given Ranitidine at 50 mg/kg [11]. All animals were given ethanol (Merck) 50 % (v/v) (in distilled water) at 10 mL/kg orally to induce gastric ulceration [6].

One hour after ethanol administration, all rats were killed by an overdose of chloroform and the stomachs were rapidly removed, opened along their greater curvature and gently rinsed under running tap water and spread on a paraffin plate. Lesions in the glandular part of the stomach were measured with a graticules (Heerbrugg Switzerland wild) under a stereomicroscope (Leica zoom 2000).

Long lesions were counted and measured along their greater length. Petechial lesions were counted. Each five petechial lesions were taken as 1mm of ulcer [6]. The sum of the total length long ulcers and petechial lesions in each group of rats was divided by its number to calculate the ulcer index (mm). The macroscopic curative ratio was determined by the formula:

$$\text{Curative ratio} = \frac{(\text{control ulcer index}) - (\text{test ulcer index})}{(\text{control ulcer index})} \times 100$$

Immediately after macroscopic evaluation the stomachs were fixed in neutral buffered formalin (10%) then glandular parts were divided to four segments and routine histologic processing was carried out. 5-6 μm sections were stained by H&E method and were evaluated microscopically (Olympus CH30). Microscopic ulcer index was obtained using published methods [12] by two pathologists, separately and a mean index was calculated.

Normal tissue = 0

Local damage to gastric pits cells = 1

Local damage to gastric glands = 2

Deep damage to gastric glands = 3

Table 1. Effect of the extracts on ethanol- induced gastric ulcer.

Groups	Ulcer index \pm SEM (Macroscopically)	Ulcer index \pm SEM (Microscopically)	Macroscopic Curative ratio (%)
Distilled water (10 mL/kg)	12.51 \pm 2.14	13.6 \pm 1.22	
Ranitidine (50 mg/kg)	5.19 \pm 1.02	7.72 \pm 0.87	58.51
Fv (50 mg/kg)	4.14 \pm 0.62*	6.32 \pm 0.75*	66.9
Fv (100 mg/kg)	2.99 \pm 0.46*	4.15 \pm 0.78*	76.09
Fv (150 mg/kg)	2.47 \pm 0.42*	2.15 \pm 0.42*	80.25

* $p < 0.01$; n/group=7Fv: *Falcaria vulgaris*

Microscopic ulcer index = (number of lesion 1) + (number of lesion 2) \times 2 + (number of lesion 3) \times 3

Statistical Analysis

The data were expressed as mean \pm SEM and tested for significance by one way ANOVA and Dunnett t-test and results were regarded as significant when $p < 0.05$.

RESULTS

Ethanol (50%) induced gastric damage showed marked gross mucosal lesion, including long hemorrhage bands and petechial lesion. On gross examination these hemorrhagic bands were characterized by different sizes along the longitudinal axis of the glandular part of stomach (Fig 1A). Animals pretreated with *F. vulgaris* showed very mild lesions with interstitial hemorrhage and sometimes no lesion at all (Fig 1B).

Doses of *F. vulgaris* significantly increased macroscopic curative ratio compared with control groups (Table 1). Morphometric evaluation was also carried out to evaluate the extent of ulcer. The ulcer index was significantly reduced in animals pretreated with *F. vulgaris* compared to distilled water and ranitidine treated rats (Table 1). On microscopic examination, ethanol treated rats showed mucosal hemorrhage (Fig 2A), segmental mucosal necrosis of gastric epithelium, edema and ample infiltration of leukocytes in submucosa (Fig 2B). Only patchy mucosal epithelial loss was seen in pretreated rats.

DISCUSSION

The finding of present study demonstrated that hydroalcoholic extract of *F. vulgaris* significantly protected against mucosal damage induced by ethanol (50%) and curative ratios of plant extracts 50, 100 and 150 mg/kg were 66.9, 76.09 and 80.25 respectively. It is remarkable that these doses produced a greater protection than ranitidine (50 mg/kg) against the ethanol. Narcotizing agents such as ethanol, when given intragastrically to rats produce severe gastric hemorrhagic erosions. Ethanol induced both long ulcers and petechial lesions within a short time, which makes this technique suitable for screening experiments for investigation of antiulcer drugs. The genesis of ethanol-induced gastric lesion is of multifactorial origin with the decrease in gastric mucus amount [0] also it is associated with significant production of free radicals leading to increased lipid peroxidation which in turn causes damage to cell and cell membranes [13].

In an attempt to correlate the effects of the extract observed in this study with chemical compound present in *F. vulgaris*, we carried out a literature review and found that tannins have gastroprotective and antiulcer effects. Alkofahi (1999) showed that all of the effective plant extracts contained tannins and/or flavonoids [9]. Ramirez (2003) showed that tannins extracted from *S. cumini* have significant gastroprotective property [14]. Although, the exact nature of phytoconstituents present in this plant is not clear, it is a rich source of tannins and ascorbic acid [1, 3]. Gastroprotective effect of its extract could be due partly to the presence of tannins and their vasoconstrictive and gastroprotective effects and antioxidant property excreted by vitamin C which can reduce free radical effects by scavenging them. Further experiments are required to isolate the active principals and to elucidate the exact mechanism of antiulcerogenic activity of *F. vulgaris*.

In conclusion, to our knowledge, this study provides for the first time evidence that showed gastroprotective effect of *F. vulgaris* against ethanol-induced ulcers which correlated with the folk medicinal use of this herb in the west of Iran.

ACKNOWLEDGEMENTS

The authors would like to thank Dr Rostam Ghorbani (histologist), Dr Babak Izadi (pathologist) Dr Gholamreza Bahrami (pharmacologist), Dr Mansour Rezaei (statistician) and Dr Parviz Sayadi for their useful help in this work.

REFERENCES

- Azhdari, E. Treatment of diseases by traditional method. Yas publishers, mash had 4th, 1380; 226-9. (In Persian)
- Mir-Haidar H. Plant knowledge and using plants to prevent and treatment disease. 1st Ed, 2001; 67-8. (In Persian)
- Fazly Bazaz BS, Harrirzadeh G, Imani SA, Rashed MH. Survey of Iranian plants for Alkaloid, Flavonoids, Saponin and Tannins (Khorasan province), *Int J Pharmacol.* 1993;35(1):17-30.
- Mizui T, Sato H, Hirose F, Doteuchi M. Effect of antiperoxidative drugs on gastric damage induced by ethanol in rat. *Life Sci.* 1987;41:755-63.
- Goel RK, Sairam K. Anti-ulcer drugs from indigenous sources with emphasis on *Musa sapientum*, *Tamrabhasma*, *Asparagus racemosus* and *Zingiber officinale*. *Indian J Pharmacol.* 2002;34:100-10.
- Alkofahi A, Atta AH. Pharmacological screening of anti-ulcerogenic effects of some Jordanian medicinal plants in rats. *J Ethnopharmacol.* 1999;67:341-5.
- Anupam B, Malay C. Protective effects of *Mikania cordata* root extracts against physical and chemical factors-induced gastric

- erosions in experimental animals. *Planta Medica*. 1994;60:110-3.
8. Garg GP, Nigam SK, Ogle CW. The gastric antiulcer effects of leaves of the neem tree. *Planta Medica*. 1993;59:215-7.
 9. Glavin GB, Mikhail AA. Stress and ulcer etiology in the rat. *Physiol Behav* 1976;16:135-9.
 10. Miller LC, Tainter ML. Estimation of ED₅₀ and its error by means of log probit graph. *Exp Biol Med*. 1944;57:261-4.
 11. Alvares A, Pomar F, Sevilla MA, Montero MJ. Gastric antisecretory and antiulcer activities of an ethanolic extract of *Bidens pilosa* L. var. *radiata* Schult. *J Ethnopharmacol*. 1999;67:333-40.
 12. Pandit S, Sur TK, Jana U, Bhattacharyya D, Debnath PK. Antiulcer effect of Shankha bhasma in rats: a preliminary study. *Indian J Pharmacol*. 2000;32:378-80.
- Al-Harbi MM, Qureshi S, Raza M, Ahmad MM, Afzal M, Shah AH. Gastric antiulcer and cytoprotective effect of *Commiphora Molmol* in rat. *J Ethnopharmacol*. 1997;55(2):141-50.
13. Reshma, S, Vijay Kumar K, Naidu MUR, Ratnagar KS. Effects of *Gingko biloba* extract on ethanol-induced gastric mucosal lesions in rats. *Indian J Pharmacol*. 2000;32:313-7.
 14. Ramirez RO, Rao JR. The gastro protective effect of tannin extract from Duhat (*Syzygium cumini* skeels) bark on HCl / ethanol induced gastric mucosal injury in rat. *Clin Hemorheol Microcirc* 2003;79(3-4):253-61.

CURRENT AUTHOR ADDRESSES

Mozafar Khazaei, Reproduction Research Center, Kermanshah University of Medical Sciences, Kermanshah, Iran (Zip Code: 67146-64685), Tel: +98 (831) 4274619-21, Fax: +98 (831) 4276477, e-mail: mkhazaei1345@yahoo.com (Corresponding Author).

Hossein Salehi, Department of Anatomy, Medical Faculty, Arak University of Medical Sciences, Arak, Iran, e-mail: psalehi2002@yahoo.com.