

# Ocular Toxicity Caused by Euphorbia Sap: A Case Report

ISAAC KARIMI, JAVAD YOUSEFI and ALI GHASHGHAI

For author affiliations, see end of text.

Received May 6, 2009; Revised May 29, 2009; Accepted June 5, 2009

This paper is available online at <http://ijpt.iums.ac.ir>

## ABSTRACT

This is the first clinical case report of patient with ocular inflammation caused by plant sap from *Euphorbia* species in Iran. We examined a patient with history of recent ocular exposure to the sap of *Euphorbia* species. Initial symptoms were generally burning or stinging pain, blurred vision, ocular itching, agitation, and lacrimation. All symptoms were stable during course of disease except lacrimation that not continued following first day of exposure. Clinical findings confirmed mild keratoconjunctivitis. All signs and symptoms had resolved by 8 days. The patient was treated with antibiotic drop (chloramphenicol). Cycloplegic drop, steroid injection and potato poultice were also used. In conclusion, people who work with *Euphorbia* plant species must wear goggle and glove. Clinicians managing ocular problems caused by *Euphorbia* should be aware of sight-threatening infection. Our suggestion for managing of *Euphorbia* sap keratoconjunctivitis is applying freeze potato poultice as supportive therapy.

**Keywords:** *Euphorbia*, Keratoconjunctivitis, Potato poultice, Iran

*Euphorbia* is a genus of plants belonging to the family Euphorbiaceae. This diverse genus has worldwide distribution. The plants are annual or perennial herbs, woody shrubs or tree with a caustic, poisonous milky sap. Herbaceous species of this plant are known in Iranian and Arabic traditional folk medicines with different names, depending on its various toxic or beneficial effects, such as fiery flower, emetic pill, pill of maleks and snake milk. Wild herbaceous species of this plant are known as weed plants for wheat and bran plantations while others that grown on the deserts are good resources for nomadic apiculture systems especially in the central Iran. Honeybees attracted to this plant because of its latex. The main phytochemical substances in the latex of *Euphorbia* are of di- or tri-terpen esters (e.g., resiniferatoxin), 1-inositol, pyrrogalic and catechuic tannins and the alkaloid xanthorammine. Gupta and Gargi [1] found taxerol, friedelin, sitosterol, myricyl alcohol, ellergic acid and hentriacontane in extracts of the stem whilst Blanc *et al.* [2] reported ellagic, gallic, chlorogenic and caffeic acids, kaempferol, quercitol, quercitrin (as a genin of a heteroside), and a number of amino acids. Falodun *et al.* [3] also have reported saponins, alkaloids, tannins, flavonoids and terpenes in the ethanolic and aqueous extracts of leaves and flowers of *E. heterophylla* L.

The latex (milky sap) of spurge acts as a deterrent for herbivores as well as a wound healer. The terpen ester composition determines how caustic and irritating to the skin it is. In contact with mucous membranes (eyes, nose, mouth), the latex can produce extremely painful inflammation. In experiments with animals, it was found that the terpen ester resiniferatoxin had an irritating effect much stronger than capsaicin, the "hot" substance found in chillies [4]. Adedapo *et al.* [5] has shown that *E. hirta* contains substances that have potential deleterious effects on serum biochemistry of rats; therefore caution should be exercised in the use of *E. hirta* as medicinal plant. It also means that the presence of this plant in the pasture could serve as a source of toxicosis to grazing animals. AL-Sultan and Yehia [6] have reported acute toxicity of *E. heliscopia* in various organs of rats.

Beside these hazardous effects, *Euphorbia* plant has many therapeutic effects including of hepatoprotective and antioxidant activity [7], anti-inflammatory and purgative. It is also useful in rheumatism, dropsy, gout, neuropathy, deafness and cough [8]. The plant is also widely used in Africa against diarrhea and dysentery, especially amoebic dysentery. In Nigeria, extracts or exudates of *E. hirta* are used as ear drops and in the treatment of boils, sore and promoting wound healing [9]. The plant has a diuretic and purgative action and is



Fig 1. *Euphorbia* leaves

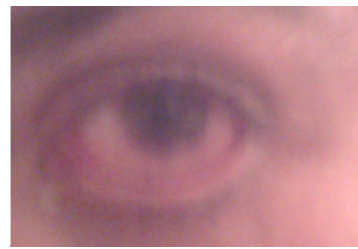


Fig 2. Mild keratoconjunctivitis 5 hours after exposure to *Euphorbia* sap

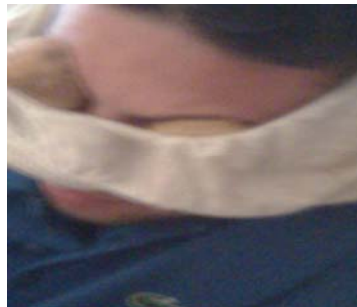

Fig 3. Eye covering with halves of potato

also known to have a remedy for inflammation of the respiratory tract in asthma as it has a special reputation for causing bronchial relaxation [10]. The plant shows antibiotic activity as well [11]. The alcoholic extract of the whole plant had an anti-cancer action against Friend leukaemia virus in mice [12]. It further showed hypoglycaemia action in albino rats and an antiprotozoal effect [13]. The plant has also been shown to have anthelmintic activity [5, 11, 14]. The use of latex on warts, whitlows and the like is worldwide [15]. Recently antibacterial and anti-inflammatory activities of *E. heterophylla* and *E. hirta* were reported [16-19]. The website: <http://www.euphorbia-international.org/> of International Euphorbia Society covers much more information about the *Euphorbiae*.

We present here a case of ocular toxicity caused by *Euphorbia* that grown as weeds in wheat plantation in Urmia, Western Azerbaijan, Iran (Fig 1). He had decided to evaluate antibacterial effects of several extracts of collected saps for his B.Sc. project. He felt a stinging sensation as sap hit his eyes. He did not irrigate the eyes until 2 hours later, by which time he was suffering increasing pain. The eyes were immediately washed with clean water many times. The patient was so agitated and his main complaint was burning ocular pain.

#### REPORT OF CASE

A 24-year-old man was collecting the sap of herbaceous variety of plant *Euphorbia* in urban area of Urmia, Western Azerbaijan, Iran (Fig 1). He had decided to evaluate antibacterial effects of several extracts of collected saps for his B.Sc. project. He felt a stinging sensation as sap hit his eyes. He did not irrigate the eyes until 2 hours later, by which time he was suffering increasing pain. The eyes were immediately washed with clean water many times. The patient was so agitated and his main complaint was burning ocular pain.

He was assessed by a general physician later the same midnight. The eyes were still painful and there were marked lacrimation and conjunctival hyperemia. The patient was treated with acute dexamethazone injection, topical 2% homatropine drop and chloramphenicol eye drop 4 times daily but the outcome was scarce. The next two days, the eyes were more painful and a thick mucopurulent layer covered the eyes. The patient complained of blurred vision and asked his family to check his eyes for sands as he was severely photophobic (Fig 2). He was referred to an ophthalmologist. The eyes were still painful but there was no lacrimation. There was no edema of the corneal stroma. The anterior chamber was quiet, and intraocular pressure was normal. His problem was diagnosed as keratoconjunctivitis by the ophthalmologist. He was still treated with chloramphenicol drop 4 times daily but the patient didn't show any sign of improvement. Finally according to the old medical folklore quote that stated: "the potato poultice is the best remedy for the burning wound and burning pain", he applied freeze halves of potato on his eyes (Fig 3). It was like pouring water on the fire. All symptoms had resolved by 8 days after supportive therapies.

#### CONCLUSION AND COMMENT

*Euphorbia* keratopathy was reported by several case reports and clinical case series previously all around the world [20-22], but this work is the first report of inadvertently keratoconjunctivitis following unarmed contact with the sap of *Euphorbia* species that grown in Iran. The usual therapy consists of rinsing, antibiotics, steroids and mydriatics when the anterior chamber is inflamed. It may also be necessary to protect the

damaged eye from light, because photo-allergic reactions are possible. Although *Euphorbia* keratopathy seems to be self-limiting when managed supportively, it is important to remember that blindness can occur, particularly in neglected cases [22]. Management is aimed at minimizing inflammation until the disease naturally subsides. Pharmacologic therapy is the mainstay of treatment. Environmental strategies of therapy include: avoidance of allergens and triggering factors, cold compresses and moving to a cooler climate. The striking feature of this study is supportive therapy with potato. Potato is an astringent and will help to reduce the inflammation.

## REFERENCES

- Gupta DR, Gargi SK. A chemical examination of *Euphorbia hirta* L. *Bull Chem Soc Jap* 1966; 39:2532-4.
- Blanc P, Bertrand P, de Saqui Sanner G, Ane M. Identification par chromatographie et etude spectral de quelque acides phenols, acides ellagique, gallique, chologenique, cafeique dans une Euphorbiaceae exotique; *Euphorbia hirta*, L. *Annales des Pharmacie francaises* 1972;30:720-1.
- Falodun A, Okunrobo LO, Uzoamaka N. Phytochemical screening and anti-inflammatory evaluation of methanolic and aqueous extracts of *Euphorbia heterophylla* Linn (*Euphorbiaceae*). *African J Biotech* 2006; 5:529-31.
- Eldershaw TP, Colquhoun EQ, Bennett KL, Dora KA, Clark MG. Resiniferatoxin and piperine: capsaicin-like stimulators of oxygen uptake in the perfused rat hindlimb. *Life Sci* 1994; 55:389-97.
- Adedapo AA, Abatan MO, Idowu SO, Olorunsogo OO. Effects of chromatographic fractions of *Euphorbia hirta* on the rat serum biochemistry. *African J Biomed Res* 2005; 8:185-9.
- AL-Sultan SI, Yehia AH. Acute Toxicity of *Euphorbia helioscopia* in Rats. *Pakis J Nutri* 2006; 5:135-40.
- Jyothi TM, Prabhu K, Jayachandran E1, Lakshminarasu S, Ramachandra Setty S. Hepatoprotective and antioxidant activity of *Euphorbia antiquorum*. *Phcog Mag* 2008; 4:127-33.
- Kirtikar KR, Basu BD. Indian medicinal plants, vol 3. M/s Bishen singh Mahendrapal singh, Dehardun; 1975. p. 2204-16.
- Igoli JO, Ogaji TA, Tor-Anyiin Igoli NP. Traditional medicine practice amongst the Igede people of Nigeria. *Part II. African J Traditional Compl Alt Med* 2005; 2:134-52.
- Johnson PB, Abduraham EM, Tiam EA, Abduaguye I, Hussaini IN. *E. hirta* extracts increase urine output and electrolytes in rats. *J Ethnopharmacol* 1999; 65:63-9.
- Sofowora A. Medicinal Plants and Traditional Medicine in Africa. Nigeria: Spectrums Books Limited, Ibadan; 1993. p. 4-10.
- Burkill HM. The useful plants of West Tropical Africa. London: Royal Botanical Gardens; 1985. p. 370-378.
- Dhar ML, Dhar MM, Dhawan BN, Mehrotara BN, Ray C. Screening Indian plants for biological activity. *Part I Indian J Exptal Biol* 1968; 6:232-47.
- Ayensu ES. Medicinal Plants in West Africa. Algonac, Michigan, USA: Reference Publication Inc; 1979. p. 4-7.
- Hartwell JL. Plants used against cancer; a survey. *Lloydia* 1969; 32:153-205.
- Ogueke CC, Ogbulie JN, Okoli IC, Anyanwu BN. Activities and toxicological potentials of crude ethanolic extracts of *Euphorbia hirta* antibacterial activities and toxicological potentials of crude ethanolic extracts of *Euphorbia hirta*. *J Amer Sci* 2007; 3:11-6.
- Falodun A, Agbakwuru EOP, Ukoh GC. Antibacterial Activity of *Euphorbia heterophylla* Linn (Family *Euphorbiaceae*). *Pak J Sci Res* 2003; 46:471-2.
- Falodun A, Okunrobo LO, Uzoamaka N. Phytochemical screening and anti-inflammatory evaluation of methanolic and aqueous extracts of *Euphorbia heterophylla* Linn (*Euphorbiaceae*). *African J Biotech* 2006; 5:529-31.
- Ogbulie JN, Ogueke CC, Okoli IC, Anyanwu BN. Antibacterial activities and toxicological potentials of crude ethanolic extracts of *Euphorbia hirta*. *African J Biotech* 2007; 6:1544-8.
- Antcliff RJ, Hodgkins PR, Bowman R, Keast-Butler J. *Euphorbia lathyris* latex keratoconjunctivitis. *Eye* 1994; 8:696-8.
- Eke T. Acute kerato-uveitis associated with topical self-administration of the sap of the Petty Spurge (*Euphorbia peplus*). *Ophthalmologie* 1993;90:58-61
- Eke T, Al-Husainy S, Raynor MK. The Spectrum of Ocular Inflammation Caused by *Euphorbia* Plant Sap. *Arch Ophthalmol* 2000; 118:13-16.

## CURRENT AUTHOR ADDRESSES

Isaac Karimi, Department of Physiology and Pharmacology, College of Veterinary Medicine, Razi University, Kermanshah, Iran. E-mail: isaac\_karimi2000@yahoo.com (Corresponding author)

Javad Yousefi, Hamadan University of Medical Sciences, Hamadan, Iran.

Ali Ghashghai, Department of Clinical Sciences, College of Veterinary Medicine, Razi University, Kermanshah, Iran.